

# Aromatherapy in the Treatment of Idiopathic Intraoral Ulcer

<sup>ID</sup> Zeliha GÜNEY<sup>a,b</sup>, <sup>ID</sup> Canan ÖNDER<sup>b</sup>, <sup>ID</sup> Tuba ÇALIK DURMAZ<sup>c</sup>

<sup>a</sup>Ankara Medipol University Faculty of Dentistry, Department of Periodontology, Ankara, Türkiye

<sup>b</sup>Ankara University Faculty of Dentistry, Department of Periodontology, Ankara, Türkiye

<sup>c</sup>Private Pharmacist, Ankara, Türkiye

This study was presented as a poster at the 24<sup>th</sup> Congress of the Balkan Stomatological Society, May 9, 2019, Tirana, Albania

**ABSTRACT** Idiopathic intraoral ulcers are recurrent painful oral sores with an unknown cause but are related to infections, hypersensitivity, genetics, and immune responses in the mouth. In July 2018, a 17-year-old female kidney transplant patient applied to our clinic with a complaint of non-healing mouth wounds. After an excisional biopsy, it was diagnosed with a non-specific ulcer. Subsequently, a mouthwash containing hyaluronic acid was prescribed. However, despite regular follow-ups, no clinical improvement was observed in the patient's condition, and the patient was referred to an aromatherapy specialist pharmacist. A specialist pharmacist prepared 1% Myrrh (*Commiphora molmol*) oil to be applied to ulcers by diluting with 0.9% NaCl. Remarkable improvement was observed within two days. Combining conventional therapies with aromatherapy can lead to successful results for specific diseases not responding to current treatments.

**Keywords:** Intraoral ulcers; *Commiphora molmol*; aromatherapy

Idiopathic intraoral ulcers (IIU) are a common condition of the oral cavity characterized by recurrent, painful ulcers. They are shallow and confined erythematous ulcers with a gray base. IIU often manifests as a single lesion on the buccal or labial mucosa, gingiva, or tongue. Severe discomfort is common, and the patient's chewing ability may be affected at the location of the lesion. Immunocompromised individuals frequently have more noticeable symptoms, such as extensive involvement and significant discomfort, which might interfere with eating.<sup>1</sup> Although several variables contribute to the development of IIU, including dietary, traumatic, microbiological, psychological, genetic, and allergy factors, no definitive cause has been found.<sup>2</sup>

Epithelial damage usually begins in the stratum basale and progresses through the superficial layers,

finally resulting in ulceration and surface exudate. Extravasated erythrocytes, subepithelial extravascular neutrophils, and numerous macrophages with phagolysosomes around the ulcer margin, as well as non-specific attachment of stratum spinosum cells to immunoglobulins and complements, may be caused by vascular leakage and passive diffusion of serum proteins. These observations imply that immune complex vasculitis could be involved in developing IIU.<sup>3</sup> Previous research also supports the idea that this inflammatory condition stems from an abnormal immune response to the oral mucosa. Tissue-specific autoimmunity is considered one of the primary mechanisms of IIU development, emphasizing cytokine release due to T-helper 1 lymphocyte activation.<sup>4</sup> Additionally, there is evidence indicating the involvement of polymorphonuclear leukocytes (PMNL) in the pathogenesis of IIU.<sup>5</sup>

#### TO CITE THIS ARTICLE:

Güney Z, Önder C, Çalık Durmaz T. Aromatherapy in the treatment of idiopathic intraoral ulcer. Türkiye Klinikleri J Case Rep. 2024;32(3):87-90.

#### Correspondence: Canan ÖNDER

Ankara University Faculty of Dentistry, Department of Periodontology, Ankara, Türkiye

E-mail: gulec\_canan@yahoo.com

Peer review under responsibility of Türkiye Klinikleri Journal of Case Reports.

Received: 18 Dec 2023

Accepted: 26 Mar 2024

Available online: 28 Mar 2024

2147-9291 / Copyright © 2024 by Türkiye Klinikleri. This is an open access article under the CC BY-NC-ND license (<http://creativecommons.org/licenses/by-nc-nd/4.0/>).



Within complementary and alternative medicine, the utilization of plants for medicinal purposes is gaining popularity. Myrrh, an herb frequently incorporated into home-prepared traditional remedies in Saudi Arabia, holds significance.<sup>6</sup> It is derived from the oleo-gum resin of two trees, namely *Commiphora molmol* and *Balsamodendron myrrh*, both of which are shrub-like trees found in Arabia and Africa.

Many researchers have examined myrrh's possible benefits and effects in treating ulcers, Schistosoma, catarrh, furunculosis, diabetes, and skin wounds.<sup>7,8</sup> It has been observed that *C. molmol* has a practical antimicrobial effect by stimulating the production of leukocytes thanks to its antimicrobial components.<sup>8</sup> Myrrh is antimicrobial and antifungal and is known to have local antiseptic, immunomodulatory, circulatory stimulating, anti-inflammatory, antiseptic, deodorizing, and vasoconstrictor properties, and it even exhibits anti-tumor properties.<sup>7</sup>

## CASE REPORT

A female patient who underwent kidney transplantation in January 2018 with the diagnosis of membranoproliferative glomerulonephritis applied to Ankara University Faculty of Dentistry in July 2018 with the complaint of a non-healing wound in her mouth. She was using cyclosporine to prevent organ rejection, which has a profound inhibitory effect on the function of granulocytes and monocytes, playing an important role in the host's defense against infection.<sup>9</sup> In clinical examination, pale, diffuse, and painful ulcerated lesions were observed on the lip mucosa, vermillion line, and gingival margin (Figure 1). After conducting a culture using swab samples taken from the patient, no microbial growth was detected except for standard flora elements. In addition to the oral hygiene procedures, the patient was prescribed a mouthwash containing chlorhexidine. During this period, nutrition was adversely affected due to oral discomfort and pain, and weight loss was observed. As a result of the complete blood counts of the patient in this period, a decrease was observed in the neutrophil, monocytes, and lymphocyte values (Figure 2).

The histopathological examination of the biopsy sample obtained from the relevant region diagnosed

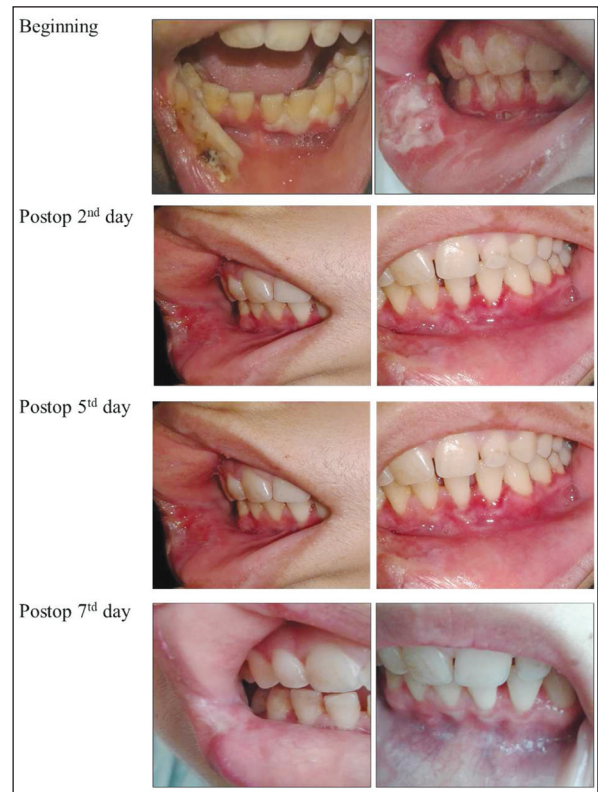

FIGURE 1: Intraoral view of lesions over time.

a non-specific ulcer. After the biopsy, we recommended mouthwash containing hyaluronic acid to the patient, but after one week, no improvement was achieved. We consulted the patient with a specialist pharmacist working on aromatherapy.

A solution was prepared by diluting 1% Myrrh oil with 0.9% NaCl to be applied to ulcers twice a day, considering the patient's necrosis and oral hygiene, and a dramatic improvement was achieved in the following two days; all lesions healed within a week.

Written informed consent was obtained from the patient before the study.

## DISCUSSION

PMNL, lymphocytes, and macrophages are the first line of defense of the tissue. Specific inflammatory mediators can potentially prepare these protective cells, enhancing their ability to adhere, phagocytose, and degranulate. However, if these cells are inappropriately or excessively activated, they could damage inflammatory tissue.<sup>10</sup> It is crucial to regulate the ac-

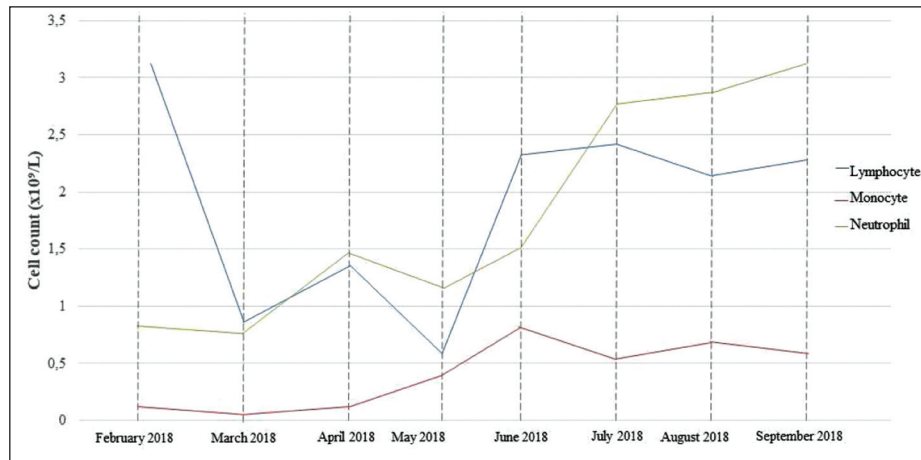


FIGURE 2: Change in blood lymphocytes, monocytes, and neutrophil counts over time.

tivation status of these protective cells to maintain a balance between defense mechanisms and preventing harm. Recurrent episodes of oral aphthae, fever, malaise, and skin infections characterize a decreased blood neutrophil count. In our patient, the decrease in neutrophil, lymphocyte, and monocyte counts during the development of the lesions may be the underlying cause. Although there is no clear information about the etiology of the lesions, long-term broad-spectrum antimicrobial mouthwashes may have caused the deterioration of the balance of the normal oral flora and malnutrition that developed with the decline of nutrition, which may further aggravate the case.

In comparison to natural healing methods, pharmacotherapeutic agents pose the risk of being toxic, ineffective, contraindicated, or causing severe side effects. Hence, there has been a growing inclination towards the use of natural remedies. The literature reports a diverse array of traditional alternative medicines, many of which are employed for managing chronic conditions like cancer, diabetes mellitus, and chronic renal pathologies.<sup>11</sup> Notably, 51% of healthcare professionals, including physicians and nurses, acknowledge using herbal medication.<sup>12</sup> Furthermore, herbs are commonly used in conjunction with conventional medications. While there has been substantial research emphasizing the potential positive impacts of myrrh, there is a lack of thorough investigation into its potential negative effects and toxicity within dental contexts.<sup>6</sup> Previous studies have recog-

nized myrrh for its antiseptic, anti-inflammatory, and properties that stimulate circulatory and immune systems.<sup>13</sup> Moreover, it has shown the capability to boost plasma cell production and promote angiogenesis and tissue remodeling within a week following an injury.<sup>14</sup> Given its healing properties, myrrh holds promise as a potential aid in promoting wound healing and repair. The positive effect of myrrh on our patient's lesions may be related to its positive impact on the production and regulation of immune cells. Our patient, who uses immunosuppressants due to kidney transplantation, becomes prone to opportunistic infections. Therefore, broad-spectrum antimicrobial agents were initially sought. However, observing standard oral flora elements in the swab samples and the absence of opportunistic microorganisms support the findings that these lesions are related to wound healing and immune response rather than microbial stimuli. Therefore, it is unsurprising that the lesions regressed dramatically with myrrh, which has an immunomodulatory effect.

Successful results can be achieved using conventional treatment with aromatherapy support for diseases that the current treatment methods cannot threaten. The global use of herbs for medicinal reasons has seen a significant surge. It is crucial to conduct further research to gain a thorough understanding of the various properties of these herbs, encompassing optimal dosage, forms, and potential negative effects and toxicity. It's essential to take into account multiple fac-

tors, such as the type, size, and location of the wound, vascular supply, presence of infection, and other conditions that may complicate the healing process.

### Source of Finance

During this study, no financial or spiritual support was received neither from any pharmaceutical company that has a direct connection with the research subject, nor from a company that provides or produces medical instruments and materials which may negatively affect the evaluation process of this study.

### Conflict of Interest

No conflicts of interest between the authors and / or family members of the scientific and medical committee members or mem-

bers of the potential conflicts of interest, counseling, expertise, working conditions, share holding and similar situations in any firm.

### Authorship Contributions

**Idea/Concept:** Zeliha Güney, Canan Önder; **Tuba Çalık Durmaz;**  
**Design:** Zeliha Güney, Canan Önder; **Tuba Çalık Durmaz;** **Control/Supervision:** Zeliha Güney, Canan Önder; **Data Collection and/or Processing:** Zeliha Güney, Canan Önder; **Analysis and/or Interpretation:** Zeliha Güney, Canan Önder; **Tuba Çalık Durmaz;**  
**Literature Review:** Zeliha Güney, Canan Önder; **Tuba Çalık Durmaz;** **Writing the Article:** Zeliha Güney, Canan Önder; **Tuba Çalık Durmaz;** **Critical Review:** Canan Önder; **Materials:** Zeliha Güney.

## REFERENCES

1. Akintoye SO, Greenberg MS. Recurrent aphthous stomatitis. Dent Clin North Am. 2014;58(2):281-97. [Crossref] [PubMed] [PMC]
2. Porter SR, Scully C, Pedersen A. Recurrent aphthous stomatitis. Crit Rev Oral Biol Med. 1998;9(3):306-21. [Crossref] [PubMed]
3. Jurge S, Kuffer R, Scully C, Porter SR. Mucosal disease series. Number VI. Recurrent aphthous stomatitis. Oral Dis. 2006;12(1):1-21. [Crossref] [PubMed]
4. Buño IJ, Huff JC, Weston WL, Cook DT, Brice SL. Elevated levels of interferon gamma, tumor necrosis factor alpha, interleukins 2, 4, and 5, but not interleukin 10, are present in recurrent aphthous stomatitis. Arch Dermatol. 1998;134(7):827-31. [Crossref] [PubMed]
5. Sistiğ S, Cekic-Arambasin A, Rabatic S, Vucicevic-Boras V, Kleinheinz J, Piffko J. Natural immunity in recurrent aphthous ulceration. J Oral Pathol Med. 2001;30(5):275-80. [Crossref] [PubMed]
6. Bakhotmah BA, Alzahrani HA. Self-reported use of complementary and alternative medicine (CAM) products in topical treatment of diabetic foot disorders by diabetic patients in Jeddah, Western Saudi Arabia. BMC Res Notes. 2010;3:254. [Crossref] [PubMed] [PMC]
7. Kimura I, Yoshikawa M, Kobayashi S, Sugihara Y, Suzuki M, Oominami H, et al. New triterpenes, myrrhanol A and myrrhanone A, from guggul-gum resins, and their potent anti-inflammatory effect on adjuvant-induced air-pouch granuloma of mice. Bioorg Med Chem Lett. 2001;11(8):985-9. [Crossref] [PubMed]
8. Shonouda ML, Farrag RM, Salama OM. Efficacy of the botanical extract (myrrh), chemical insecticides and their combinations on the cotton leaf-worm, *Spodoptera littoralis* boisd (Lepidoptera : Noctuidae). J Environ Sci Health B. 2000;35(3):347-56. [Crossref] [PubMed]
9. Kharazmi A, Svenson M, Nielsen H, Birgens HS. Effect of cyclosporin A on human neutrophil and monocyte function. Scand J Immunol. 1985;21(6):585-91. [Crossref] [PubMed]
10. Condliffe AM, Kitchen E, Chilvers ER. Neutrophil priming: pathophysiological consequences and underlying mechanisms. Clin Sci (Lond). 1998;94(5):461-71. [Crossref] [PubMed]
11. Gardiner P, Legedza A, Woods C, Phillips RS, Kemper KJ. Herb use among health care professionals enrolled in an online curriculum on herbs and dietary supplements. J Herb Pharmacother. 2006;6(2):51-64. [Crossref] [PubMed]
12. Saw JT, Bahari MB, Ang HH, Lim YH. Herbal use amongst multiethnic medical patients in Penang Hospital: pattern and perceptions. Med J Malaysia. 2006;61(4):422-32. [PubMed]
13. Russo A, Russo G, Peticca M, Pietropaolo C, Di Rosa M, Iuvone T. Inhibition of granuloma-associated angiogenesis by controlling mast cell mediator release: role of mast cell protease-5. Br J Pharmacol. 2005;145(1):24-33. [Crossref] [PubMed] [PMC]
14. Young JD, Liu CC, Butler G, Cohn ZA, Galli SJ. Identification, purification, and characterization of a mast cell-associated cytolytic factor related to tumor necrosis factor. Proc Natl Acad Sci U S A. 1987;84(24):9175-9. [Crossref] [PubMed] [PMC]