

CASE REPORT

DOI: 10.5336/caserep.2024-104461

Challenges in Diagnosis and Treatment: A Case Presentation of Kleptomania

¹Aslı Enzel KOÇ^a, ²Ezgi SELÇUK ÖZMEN^a, ³Çiçek HOCAOĞLU^b

^aTrabzon Fatih State Hospital, Clinic of Psychiatry, Trabzon, Türkiye

^bRecep Tayyip Erdoğan University Faculty of Medicine, Department of Psychiatry, Rize, Türkiye

ABSTRACT Kleptomania is characterized by recurrent stealing, more commonly observed in women. In kleptomania, the act of stealing is egodystonic and causes stress to the individual. Its etiology has been approached through various psychodynamic and neurobiological perspectives. Although it is classified as an impulse control disorder, it is emphasized that it is associated with mood disorders. Stealing behavior can serve as a representation of reclaiming the losses experienced throughout childhood. This article seeks to enrich the literature by discussing a female patient with a history of multiple losses who presented with depression at a psychiatric clinic and demonstrated kleptomaniac tendencies during the interviews. This case report emphasizes the multidimensional nature of kleptomania, as well as the difficulties in its differential diagnosis and treatment.

Keywords: Kleptomania; stress; bipolar disorder; diagnosis; borderline personality disorder

Kleptomania (KM), characterized by the urge to steal items without personal value, has a prevalence of 0.6% and is categorized as a disruptive, impulse-control, and conduct disorder.^{1,2} KM, more common in women, is influenced by guilt and shame shaped by societal norms, though cultural differences remain unclear. Emotions like guilt and shame, influenced by societal norms, may affect kleptomania and vary by culture.³

Studies highlight its close link to mood disorders, with many patients reporting worsened symptoms during depression.^{4,5} KM may also indicate subclinical mania or hypomania, given its frequent co-occurrence with bipolar disorder.⁶

Psychoanalytic literature suggests that kleptomania stems from a child's emotional neglect, with stealing acting as a way to reclaim lost pleasure and

take revenge. It's seen as a defense mechanism, where the stolen object holds symbolic meaning.⁵

This case report discusses a patient with kleptomania, personal losses, bipolar spectrum disorder, and borderline traits. Furthermore, the identification of arachnoid cysts during neurological evaluations adds additional complexity, emphasizing the multifaceted nature of her condition and the need for careful considerations in her ongoing treatment.

CASE REPORT

Ms. E, a 27-year-old married woman, visited our clinic with concerns of immorality and worthlessness. Over the past three months, she had stolen pasta and butter from her sister-in-law's home, feeling remorse and discarding the items. This led to family conflicts when she was caught. Ms. E attributed her actions to

Correspondence: Aslı Enzel KOÇ

Trabzon Fatih State Hospital, Clinic of Psychiatry, Trabzon, Türkiye

E-mail: sovera972@yahoo.com



Peer review under responsibility of Türkiye Klinikleri Journal of Case Reports.

Received: 17 Jun 2024

Accepted: 18 Sep 2024

Available online: 30 Sep 2024

2147-9291 / Copyright © 2024 by Türkiye Klinikleri. This is an open access article under the CC BY-NC-ND license (<http://creativecommons.org/licenses/by-nc-nd/4.0/>).

the traumatic loss of her father at age 15 due to an aortic aneurysm, which left her emotionally unsupported. She said, “Maybe I’m making up for what was missing,” and noted no kleptomaniac behaviors during that time.

Her kleptomania began six years ago after her marriage, when she started stealing food from her sister-in-law’s kitchen. She felt guilty and donated money to charity. Over the last three months, this behavior became more frequent. Married for six years without children, she had experienced multiple miscarriages and expressed emptiness, saying, “I couldn’t keep my babies in my belly. They slipped away from me.” Recently diagnosed with antiphospholipid antibody syndrome, she was advised to start anticoagulant therapy to prevent miscarriages. This stress coincided with increased kleptomania, leading to her being caught.

The patient exhibited depressive and irritable moods and was diagnosed with impulse control disorder and depression. She was started on fluoxetine, gradually increased to 60 mg/day. She reported improvement but avoided her sister-in-law’s house due to shame. She also feared menstrual delays, worrying about another miscarriage from thrombosis. By the 6th-month follow-up, she felt relieved and was accepted back into her sister-in-law’s home.

In the 7th month of follow-up, the patient presented with agitation and suicidal ideation. She had

taken 200 liras from a friend’s house, which was caught on camera, leading to accusations of theft and her husband seeking a divorce. The patient had been caring for her friend’s baby daily and recalled seeing money in a pocket but couldn’t remember the events afterward. She expressed deep regret, gave her friend two gold bracelets. She admitted she didn’t need the money, anticipated getting caught, and thought, “I felt lacking; let others feel lacking too.”

The patient showed intense, impulsive reactions, heightened sensitivity, emotional dysregulation, and self-harm in response to rejection, indicating borderline personality traits. In interviews with her and her family, periods of increased energy and irritability, suggesting hypomanic episodes, were also noted, raising suspicions of bipolar spectrum disorder. Fluoxetine was discontinued due to a suspected mixed phase, and lithium therapy (600 mg/day) was initiated. The Multiphasic Personality Inventory suggested manic disorder tendencies, while the Barratt Impulsiveness Scale (BIS) scored 52. Electroencephalography showed sharp wave activity, and cranial magnetic resonance imaging (MRI) revealed a 2.7x2 cm arachnoid cyst on the right and a 2x1.5 cm cyst on the left in the right and left middle cranial fossae. She was referred to Neurosurgery, and follow-up was advised. Due to lithium intolerance, lamotrigine (50 mg/day) was initiated.

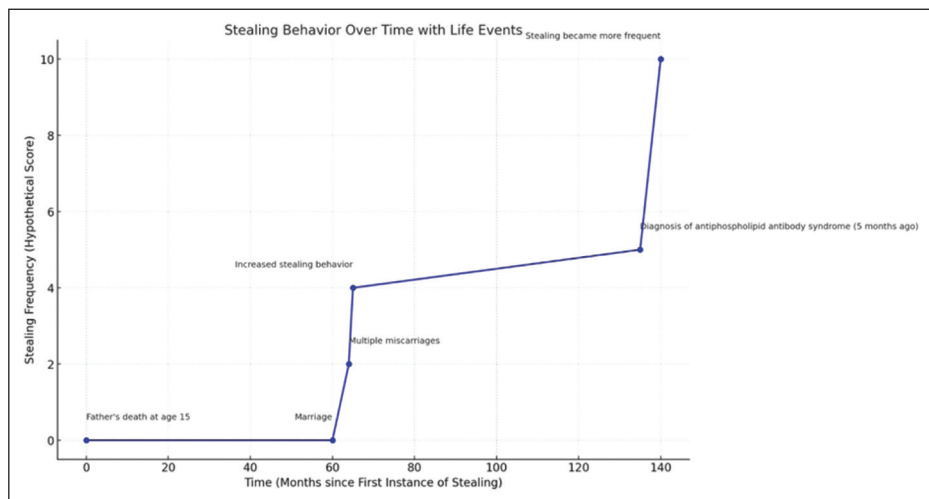


FIGURE 1: ????

In the 9th month of follow-up, the case expressed feeling better, stating that the stealing behavior never occurred. She scored 34 points on the BIS. Follow-ups of the case are ongoing. Written informed consent was obtained from the patient for publication of this case report.

Figure 1 illustrates the progression of the patient's stealing behavior over time, highlighting key life events that may have influenced the frequency and intensity of these behaviors.

DISCUSSION

KM is often seen as a forensic issue due to legal concerns.⁷ Though kleptomaniacs rarely seek help, women are more likely to do so, as in our case.⁸ Our case's stolen items are worthless, but discarding them after theft and feeling regret are kleptomania symptoms. The case did not describe an elevated strong sensation before theft or a sense of relief afterward. She describes an amnesic period which is inconsistent with kleptomania. The act of theft in kleptomania is unplanned, and the risk of getting caught is not a deterrent for individuals.⁷

The DSM-5 defines kleptomania as stealing without rage, revenge, delusions, or conduct disorder.⁹ Despite some antisocial traits, the patient is seen as responsible, altruistic, and remorseful, with no conduct disorder before age 15. The key to treating kleptomania is identifying its underlying function. As kleptomaniac behavior may serve as a defense mechanism, a psychodynamic approach to understanding her motivations may be more effective. Although uncommon in kleptomania, our patient's dissociative symptoms may be mistaken for dissociative disorders. However, research shows these symptoms are more common in kleptomaniacs than in healthy controls and are linked to impulsivity.¹⁰ The case's amnesic periods, limited to thefts and followed by guilt, align more closely with kleptomania.

Our interviews revealed transient periods of well-being and persistent interpersonal issues, many of which were driven by kleptomania. The kleptomaniac behaviors typically occurred during stressful periods, such as after miscarriages or when pregnancy was expected. Bipolar disorder, borderline per-

sonality disorder (BPD), and kleptomania were considered in the diagnosis. BPD was suggested by emotional instability, impulsivity, suicidal threats, and dissociation. Hypomanic episodes pointed towards bipolar disorder. The overlap between bipolar spectrum disorders and BPD, including affective instability, impulsivity, recurrent suicidal behavior, and interpersonal instability, can complicate differentiation.¹¹

KM often responds well to selective serotonin reuptake inhibitors (SSRI) at maximum doses. Paradoxically, SSRIs have also been reported to trigger kleptomania in some cases. Additionally, dopamine agonists used in Parkinson's disease can lead to kleptomania. SSRIs may regulate kleptomania by affecting the dopaminergic system rather than serotonin.¹² In this case, kleptomania was present before treatment, and fluoxetine was discontinued due to suspected mixed episodes. This underscores the need for careful monitoring of kleptomania patients with trauma histories, especially when using high-dose SSRIs.

Neurobiological studies have shown that kleptomaniacs exhibit reduced white matter integrity in the ventral-medial frontal brain compared to controls.¹³ The patient's electroencephalogram showed sharp wave activity in the posterior hemispheres, and the MRI showed arachnoid cysts. Arachnoid cysts have been linked to associated with various psychiatric disorders. In some cases, brain imaging in patients with impulse control disorders has suggested a neurological basis for their symptoms.^{14,15}

In conclusion, the limited epidemiological data on kleptomania highlights the need for more case reports. Our case emphasizes the complex nature of kleptomania and its connection to bipolar and BPD.

Source of Finance

During this study, no financial or spiritual support was received neither from any pharmaceutical company that has a direct connection with the research subject, nor from a company that provides or produces medical instruments and materials which may negatively affect the evaluation process of this study.

Conflict of Interest

No conflicts of interest between the authors and / or family members of the scientific and medical committee members or mem-

bers of the potential conflicts of interest, counseling, expertise, working conditions, share holding and similar situations in any firm.

Authorship Contributions

Idea/Concept: Aslı Enzel Koç, Ezgi Selçuk Özmen, Çiçek Hocaoğlu; **Design:** Aslı Enzel Koç, Ezgi Selçuk Özmen, Çiçek Hocaoğlu; **Control/Supervision:** Çiçek Hocaoğlu; **Data Collec-**

tion and/or Processing: Aslı Enzel Koç, Ezgi Selçuk Özmen; **Analysis and/or Interpretation:** Aslı Enzel Koç, Ezgi Selçuk Özmen, Çiçek Hocaoğlu; **Literature Review:** Aslı Enzel Koç, Ezgi Selçuk Özmen; **Writing the Article:** Aslı Enzel Koç, Ezgi Selçuk Özmen, Çiçek Hocaoğlu; **Critical Review:** Aslı Enzel Koç, Ezgi Selçuk Özmen, Çiçek Hocaoğlu; **References and Fundings:** Aslı Enzel Koç, Ezgi Selçuk Özmen, Çiçek Hocaoğlu; **Materials:** Aslı Enzel Koç, Ezgi Selçuk Özmen, Çiçek Hocaoğlu.

REFERENCES

1. Talih FR. Kleptomania and potential exacerbating factors: a review and case report. *Innov Clin Neurosci*. 2011;8(10):35-9. PMID: 22132369; PMCID: PMC3225132.
2. Baylé FJ, Caci H, Millet B, Richa S, Olié JP. Psychopathology and comorbidity of psychiatric disorders in patients with kleptomania. *Am J Psychiatry*. 2003;160(8):1509-13. PMID: 12900315.
3. Tangney JP, Stuewig J, Mashek DJ. Moral emotions and moral behavior. *Annu Rev Psychol*. 2007;58:345-72. PMID: 16953797; PMCID: PMC3083636.
4. Grant JE. Understanding and treating kleptomania: new models and new treatments. *Isr J Psychiatry Relat Sci*. 2006;43(2):81-7. PMID: 16910369.
5. Goldman MJ. Kleptomania: making sense of the nonsensical. *Am J Psychiatry*. 1991;148(8):986-96. PMID: 1853988.
6. McElroy SL, Pope HG Jr, Hudson JI, Keck PE Jr, White KL. Kleptomania: a report of 20 cases. *Am J Psychiatry*. 1991;148(5):652-7. PMID: 2018170.
7. Blum AW, Odlaug BL, Redden SA, Grant JE. Stealing behavior and impulsivity in individuals with kleptomania who have been arrested for shoplifting. *Compr Psychiatry*. 2018;80:186-91. PMID: 29127886.
8. Tamam L, Özpoyraz N, Ünal M. Kleptomani: bir gözden geçirme [Kleptomania: a review]. *Türk Psikiyatri Dergisi*. 1997;8(1):36-44. https://www.researchgate.net/profile/Lut_Tamam/publication/274834945_Kleptomani_Bir_gozden_gecirme_Kleptomania_A_Review/links/552aabf40cf2e089a3a9ff8b/Kleptomani-Bir-gozden-gecirme-Kleptomania-A-Review.pdf
9. American Psychiatric Association. *Diagnostic and Statistical Manual of Mental Disorders*. 5th ed. Washington, DC: Author; 2013.
10. Grant JE. Dissociative symptoms in kleptomania. *Psychol Rep*. 2004;94(1):77-82. PMID: 15077751.
11. Zimmerman M, Morgan TA. The relationship between borderline personality disorder and bipolar disorder. *Dialogues Clin Neurosci*. 2013;15(2):155-69. PMID: 24174890; PMCID: PMC3811087.
12. Mangot AG. Neurobiology of Kleptomania: an overview. *Sri Lanka Journal of Psychiatry*. 2014;5(2):2-4. <https://doi.org/10.4038/sljpsyc.v5i2.7305>
13. Mendez MF. Pathological stealing in dementia. *J Am Geriatr Soc*. 1988;36(9):825-6. PMID: 3411067.
14. Geniş B, Coşar B. A case of arachnoid cyst presenting with cognitive impairment and hypomania symptoms. *Türk Psikiyatri Dergisi* 2020;31(2):131-6. https://www.turkpsikiyatri.com/PDF/C31S2/en/tpd_c31-2_131-136_ing.pdf
15. Gössling HW, Rosin J. Kleptomanie vor und nach einer spontanen Subarachnoidalblutung—Ein neuropsychodynamischer Fallbericht [Kleptomania before and after spontaneous subarachnoid hemorrhage—a neuropsychodynamic case report]. *Fortschr Neurol Psychiatr*. 1994;62(5):164-8. German. PMID: 8050771.