

Two Cases of Nonspecific Interstitial Pneumonia

İki Olgu Nedeniyle Nonspesifik İnterstisyel Pnömoni

Sibel Alpar, Ömür Aydın, Funda Demirağ*, Nazire Uçar, Bahar Kurt

Atatürk Chest Disease and Chest Surgery, Training and Research Hospital, Chest Disease Clinic and *Pathology Department, Ankara, Turkey

Summary

Nonspecific interstitial pneumonia (NSIP) was first described in the classification of idiopathic interstitial pneumonia (IIP) by Katzenstein and Fiorelli in 1994. This term is also described in IIP consensus report of ATS and ERS in 2001. In this case report we presented 2 cases with NSIP and aimed to discuss the physiopathology, diagnosis and treatment strategies. Two female patients, 23 and 29 years old, both had respiratory signs and symptoms. X-ray of the chest showed diffuse reticular and ground glass opacifications in both patients. Diffusion capacity of CO was declined and restrictive pattern was observed in respiratory function tests. Both patients were diagnosed NSIP by open lung biopsy and steroid therapy was began. Diagnosis, treatment and aspects of NSIP as a new subgroup of IIP were examined with literature. (*Archives of Lung: 2006; 7: 110-3*)

Key Words: Nonspecific interstitial pneumonia

Özet

Nonspesifik interstisyel pnömoni (NSİP) ilk defa Katzenstein ve Fiorelli tarafından 1994'te idiyopatik interstisyel pnömoni (İİP) sınıflamasında tanımlanmıştır. Bu terim ayrıca ERS ve ATS'nin İİP konsensus raporunda da tanımlanmıştır. Burada fizyopatoloji, tanı ve tedavi stratejilerini tartışmak amacıyla iki NSİP'li olgu sunuldu. Biri 23, diğeri 29 yaşında iki kadın olgumuzun her ikisinde de respiratuvar bulgu ve belirtiler mevcuttu. Her iki olgunun akciğer grafilerinde de yaygın retiküler ve buzlu cam infiltrasyonları izleniyordu. Karbonmonoksit difüzyon kapasitesi azalmıştı ve solunum fonksiyon testlerinde restriktif patern mevcuttu. Olgulara açık akciğer biyopsisi ile NSİP tanısı konularak steroid tedavisi başlandı. İİP'nin yeni bir alt grubu olan NSİP'in tanı, tedavi ve prognozu literatür eşliğinde incelendi. (*Akciğer Arşivi: 2006; 7: 110-3*)

Anahtar Kelimeler: Nonspesifik interstisyel pnömoni

Introduction

Nonspecific interstitial pneumonia (NSIP) has been defined by Katzenstein and Fiorelli as an idiopathic interstitial pneumonia with a pathologic pattern distinct from usual (UIP), desquamative (DIP), and acute interstitial pneumonia (AIP) (1,2). NSIP is characterised by the presence of varying degrees of inflammation and fibrosis within alveolar walls. The

pathologic features of most examples contain either inflammation with minimal fibrosis or a mixture of inflammation and fibrosis (3).

NSIP occurs mainly in middle-aged adults. There is a slight female predominance. Dyspnea and cough are the most common complaints. The prognosis in NSIP is generally good (1-4). Our aim was to describe the clinical, radiologic, and pathologic profiles of NSIP in two patients.

Case 1

A 23-years-old mental retarded woman presented to our clinic with the symptoms of cough, dyspnea, weight loss and fatigue. The patient was diagnosed as pneumonia and antibiotherapy was given previously. She had never smoked. In auscultation, there were basilar end-inspiratory crackles on the left hemithorax. Routine laboratory tests were normal except a sedimentation rate of 38 mm/h. Acid resistant bacilli (ARB) in sputum and bronchial lavage fluid were negative. Angiotensin converting enzyme was normal. Collagen tissue markers were negative.

In pulmonary function tests; FVC: 2.37L(66%), FEV₁: 2.08L(64%), FEV₁/FVC: (87%). The patient was not compliant with the tests for lung volumes and carbonmonoxide diffusion capacity. In arterial blood gases; pH: 7.44, PaO₂: 60 mmHg, PaCO₂: 32 mmHg and O₂ saturation was 89%.

PA chest roentgenogram of the case revealed interstitial infiltrations at the lower zones of both lungs (Figure 1). On thorax CT bilateral ground-glass opacities, irregular alveolar consolidation, linear non septal opacities and bronchial dilatation were seen (Figure 2).

There were no pathologic findings in fiberoptic bronchoscopy. Trans bronchial biopsy was taken from the lingular segment. Histologic examination of the biopsy specimen was non-diagnostic. Bronchoalveolar lavage (BAL) was not taken because the patient was not compliant. Diagnostic wedge resection was performed by thoracic surgery.

In histopathological examination, temporally uniform and dense mononuclear cell infiltration and loose fibrosis were observed. Lymphoid aggregates were conspicuous. Dense interstitial fibrosis, organising pneumonia and granulomas were absent (Figure 3). The diagnosis was NSIP. Prednisolon (1 mg/kg/gün) therapy was given to the patient. The patient was not compliant with the therapy, therefore steroid therapy was stopped. No follow up study could be made.

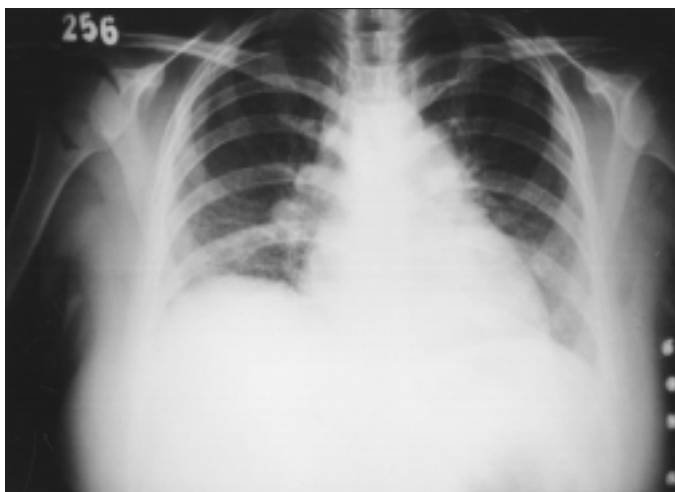

Figure 1. PA chest radiogram of the case 1

Case 2

A 29-years-old woman was admitted with cough, dyspnea, and cyanosis since 6 months. The patient was diagnosed as having bronchiolitis and antibiotherapy was given previously. She was non-smoker. On physical examination cyanosis was seen and the end inspiratory fine crackles were the only respiratory system finding. Her chest roentgenogram revealed bilateral interstitial linear or reticular opacities (Figure 4). On thorax CT, bilateral and symmetrical reticular opacities were seen (Figure 5). Results of routine laboratory tests were normal except a high sedimentation rate (50 mm/h). Acid resistant bacilli was

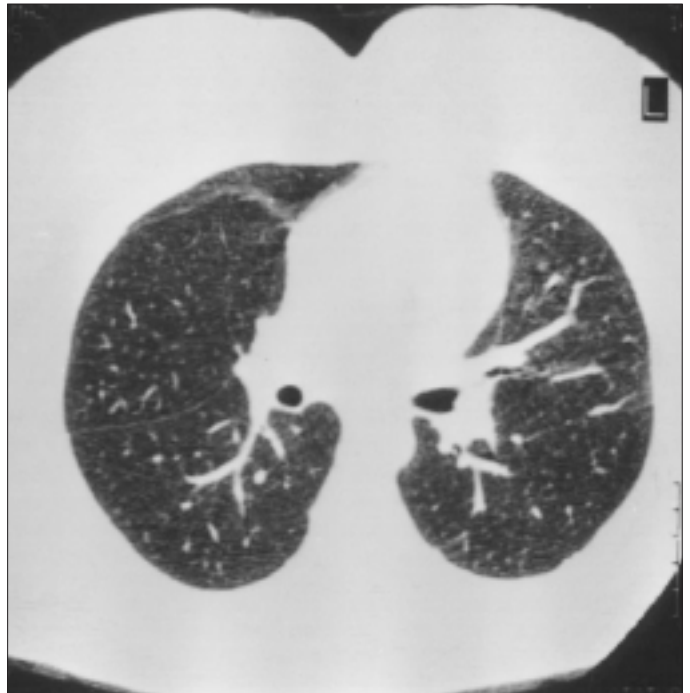


Figure 2. Thorax CT of the case 1

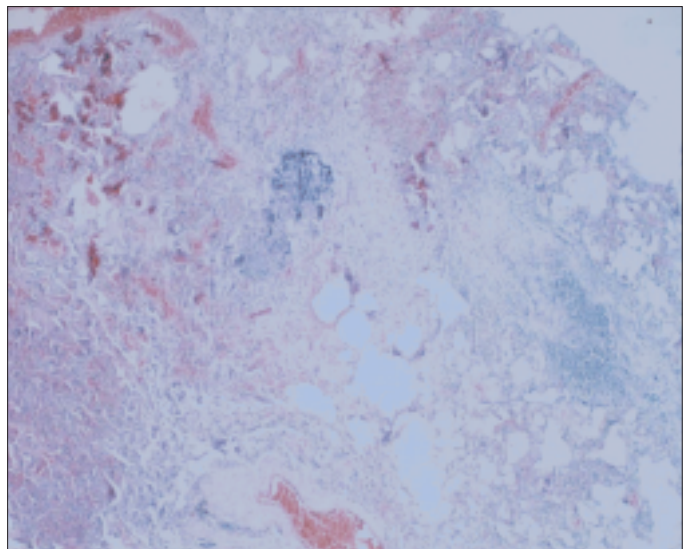


Figure 3. Histopathologic aspect of the wedge resection material of the case 1

negative in sputum. Collagen tissue markers were negative. Restrictive pattern was seen in spirometry: FVC: 2.09L(56%), FEV₁: 1.77L(55%), FEV₁/FVC: 85%, DLCO: 41%, DLCO/VA:70. In arterial blood gases; pH: 7.47, PaO₂: 40 mmHg, PaCO₂: 26 mmHg and O₂ saturation was %79.5. There were no endobronchial lesions in fiberoptic bronchoscopy. BAL and transbronchial biopsy were taken. The BAL fluid cell count yielded 20% macrophages, 15% polymorphonuclear leucocytes and 65% lymphocytes. CD4 lymphocytes were 21.26% and CD8 lymphocytes were 10.95% of all lymphocytes. CD4/CD8 ratio was 1.94. Cytologic examination of transbronchial biopsy showed that there was chronic bronchiolitis in bronchial mucosa. Open lung biopsy was done for diagnosis. In histological examination, temporally uniform interstitial inflammatory infiltration in thickened alveolar septa was seen in lung parenchyma. Interstitial cell infiltrates were consisted mainly in lymphocytes and plasma cells. (Figure 6).The diagnosis was NSIP.

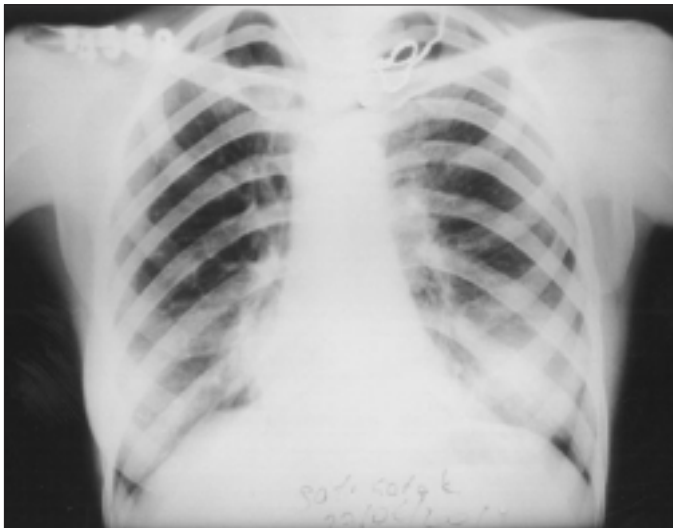

Figure 4. PA chest radiogram of the case 2

Treatment with 60 mg (1 mg/kg) prednisolon was given to the patient. Prednisolon was decreased to 30 mg after 3 months. Steroid treatment was continued for 12 months and the patient has no complaint. Radiologic findings regressed (Figure 7).

Discussion

Although first described by Katzenstein and Fiorelli in 1994, NSIP is not a new pulmonary disease. It has previously received other terms as nonclassifiable interstitial pneumonia. NSIP is characterized by a temporally uniform chronic inflammatory-cell infiltrate containing a mixture of lymphocytes and plasma cells within alveolar septa (1,4).

In our patients, pathologic lesions were temporally uniform and there were no honeycomb areas.

NSIP is usually seen in elderly patients but may occur in children, unlike IPF. There is no correlation with smoking.

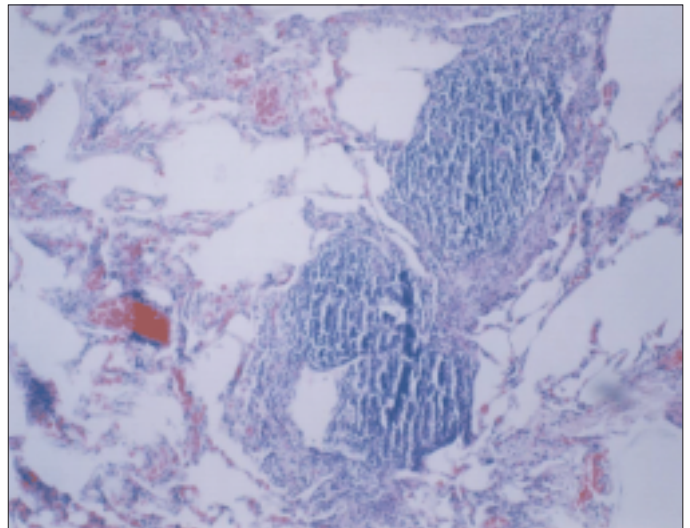


Figure 6. Histopathologic aspect of the open lung biopsy material of the case 2

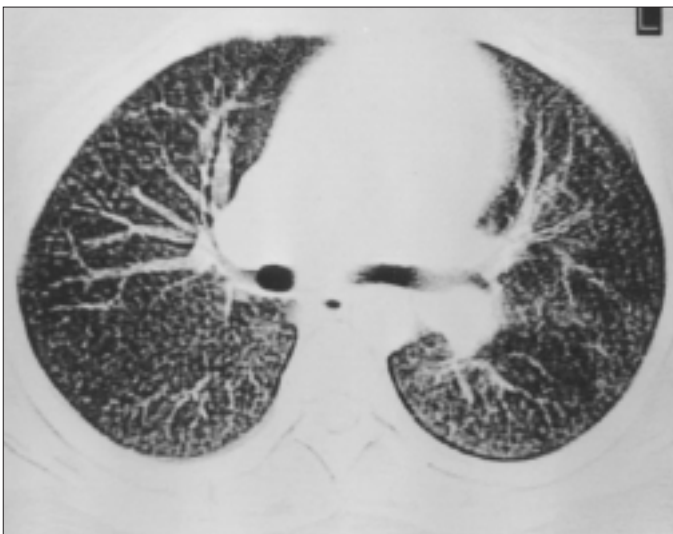

Figure 5. Thorax CT of the case 2 before therapy

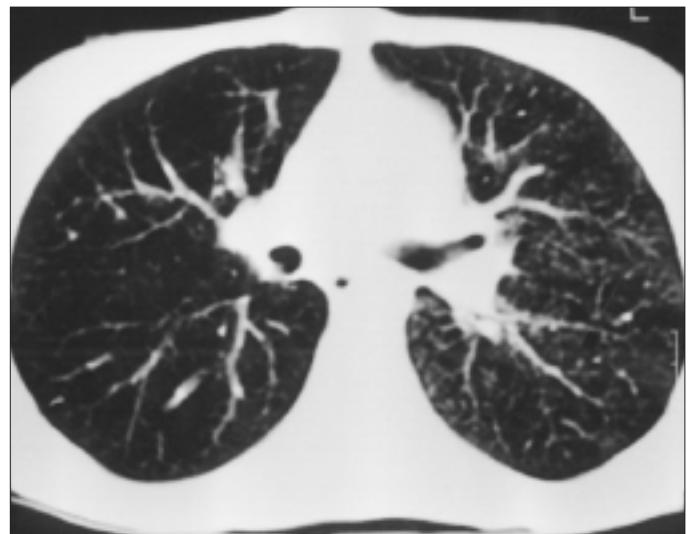


Figure 7. Thorax CT of the case 2 after therapy

Our cases were in 2 nd decade and were not smokers. Dyspnea, cough and fatigue are usual symptoms, and almost half present with a history of weight loss (1). Fever and finger clubbing are present in a minority of cases. Our cases had dyspnea, cough, fatigue and weight loss. On physical examination of NSIP, crackles are initially predominantly basal but may be widespread. Other clinical features are similar to those found in IPF. End-inspiratory rales which we obtained in both cases (I and II) are the most frequent auscultation finding.

Routine laboratory examination is non-specific. Restrictive type ventilation defect is frequent in respiratory function tests. Obstructive type defect is seen only in 10 % of the patients. We found restrictive type defect in both cases (5).

Chest radiographic features of NSIP typically shows bilateral pulmonary infiltrates on lower zones, although there is no large detailed analysis of the radiographic appearance of patients with NSIP. The HRCT features are heterogeneous, including ground-glass opacities, patchy alveolar opacities, linear nonseptal opacities, and thickening of the septal and pleural lines (1,5). Both cases showed ground-glass opacities and patchy alveolar opacities.

BAL plays an important role both in the diagnosis and the differential diagnosis. Unlike IPF, percentage of lymphocytes increases in about 50% of cases. The presence of BAL lymphocytosis strengthens the suspicion of NSIP in conjunction with other findings as HRCT and pulmonary function test results (1, 3, 5).

Only case 2 was performed BAL and lymphocyte predominance was seen in BAL fluid examination.

Transbronchial biopsy showed that there was chronic bronchiolitis in bronchi mucosa. In both cases fiber optic bronchoscopy did not provide any evidence for the diagnosis.

Usually transbronchial biopsy can not provide sufficient samples for diagnosis of NSIP. Surgical lung biopsy is recommended in most patients, especially those with suspected IPF who have clinical, physiological, or radiological features that are not typical for IPF and without contraindications to surgery. Open lung biopsy is very important in gaining sufficient lung tissue and having a definite pathological result. The main histologic feature of NSIP is the homogenous appearance of either inflammation or fibrosis as opposite to the heterogeneity seen in the other interstitial pneumonias. Fibrosis is usually located in the subpleural space (2,3). Histological examination showed temporally uniform interstitial infiltration by lymphocytes, plasma cells and a few eosinophils.

The histologic differential diagnosis for cases of NSIP includes

hypersensitivity pneumonitis, organising pneumonia, lymphoid interstitial pneumonia (LIP) and usual interstitial pneumonia (UIP). Hypersensitivity pneumonitis shows a pattern consisting of bronchiolocentric cellular interstitial pneumonia, scattered poorly formed granulomas. Masson body is not a prominent features in NSIP. NSIP pattern is less severe than the extensive diffuse alveolar septal infiltration observed in LIP. UIP pattern consists of architectural destruction, fibrosis often with honeycombing, scattered fibroblastic foci and patchy distribution (6).

Unlike patients with UIP, majority of patients with NSIP have a good prognosis. Most patients respond to treatment, but the response is not as dramatic as it is in bronchiolitis obliterans-organizing pneumonia. Steroid treatment is started usually at 1mg/kg (1, 5, 7). By the follow up response to therapy, treatment is completed to 12 months by decreasing the dose. Relapses occur while decreasing the steroid dose, especially in patients with idiopathic NSIP (1,5). In our first case, corticosteroid therapy wasn't given because of mental retardation. Our second case was given 1mg/ kg oral prednisolon therapy. At the third month of treatment, dyspnea symptom of the patient was decreased, DLCO and O₂ saturation of the blood were increased and radiologic findings regressed.

We conclude that the diagnosis of NSIP is very important for its response to steroid therapy. NSIP deserves to be individualized as an original clinicopathologic entity and should be distinguished from usual interstitial pneumonia, especially because of a better prognosis.

References

1. Cottin V, Donsbeck A, Revel D and et al. Nonspecific interstitial pneumonia. *Am J Respir Crit Care Med* 1998; 158: 1286-93.
2. Michaelson EJ, Aguayo SM, Roman J. Idiopathic pulmonary fibrosis. *Chest* 2000; 118: 788- 794.
3. American Thoracic Society, European Respiratory Society. Idiopathic pulmonary fibrosis: Diagnosis and treatment. *Am J Respir Crit Care Med* 2000; 161: 646- 64.
4. Katzenstein AL, Myers JL. Idiopathic pulmonary fibrosis. *Am J Respir Crit Care Med* 1998; 157: 1301- 1315.
5. American Thoracic Society/ European Respiratory Society International Multidisciplinary Consensus Classification of the Idiopathic Interstitial Pneumonias. *Am J Respir Crit Care Med* 2002; 165:227- 304.
6. Demirağ F. Patolojik paternler. In: Erdoğan Y, Samurkaşoğlu B (Eds). *İnterstisyel Akciğer Hastalıkları*, Ankara, Güneş Kitabevi; 2002:21-38.
7. Castobel U, King TE. International consensus statement on idiopathic pulmonary fibrosis. *Eur Respir J* 2001;17:163- 7.