

Tattoo Sarcoidosis on the Arm Associated with Systemic Involvement: Case Report

Kolda Sistemik Tutulumla Birliktelik Gösteren Bir Dövme Sarkoidozu

Nezih KARACA,MD,^a
 Banu ERTEKİN,MD,^a
 Bengü GERÇEKER TÜRK,MD,^a
 Gülşen KANDİLOĞLU,MD,^b
 Tuğrul DERELİ,MD^a

Departments of
^aDermatology,
^bPathology,
 Ege University Faculty of Medicine,
 İzmir

Geliş Tarihi/Received: 15.10.2009
 Kabul Tarihi/Accepted: 23.02.2010

Yazışma Adresi/Correspondence:
 Nezih KARACA, MD
 Ege University Faculty of Medicine,
 Department of Dermatology, İzmir,
 TÜRKİYE/TURKEY
 drmezihkaraca@gmail.com

ABSTRACT A 32 year-old male was admitted with papular lesions over his tattoo. After histopathologic examination of the lesion and biochemical and radiologic examinations, "tattoo sarcoidosis with pulmonary involvement" was diagnosed. Skin involvement of sarcoidosis is rare but it is known that first lesion can develop on old scar. Sarcoidosis on tattoos is a rare form of scar sarcoidosis in which tattoos become infiltrated with non-caseating epithelioid cell granulomas. The occurrence of tattoo sarcoidosis may be as an isolated local reaction or may accompany systemic involvement. Herein, we report a case of tattoo sarcoidosis on the arm associated with systemic involvement.

Key Words: Sarcoidosis; tattooing

ÖZET 32 yaşında erkek olgu dövmesi üzerinde gelişen papüler lezyonları nedeniyle başvurdu. Lezyonun histopatolojik değerlendirilmesi, biyokimyasal ve radyolojik incelemelerden sonra, akciğer tutulumu ile birlikte dövme sarkoidozu teşhisi konuldu. Sarkoidozun deri tutulumu nadirdir, ancak başlangıç lezyonunun operasyon izleri gibi eski skarlar üzerinde gelişebildiği bilinmektedir. Dövmeler üzerindeki sarkoidoz, dövmelerin non-kazeifiye epitelyal hücre granülomları ile infiltrat olduğu skar sarkoidozunun nadir bir formudur. Dövme sarkoidozunun gelişimi izole bir lokal reaksiyon şeklinde olabilir ya da sistemik tutulumla eşlik edebilir. Burada, sistemik tutulumla birlikte görülen kolda dövme sarkoidozu olgusu bildirilmektedir.

Anahtar Kelimeler: Sarkoidoz; dövme

Türkiye Klinikleri J Dermatol 2010;20(2):88-90

Tattooing may result in granulomatous complications such as sarcoidal granulomas, foreign body granuloma and allergic granulomatous reactions.^{1,2} Sarcoidal granuloma may be an isolated local reaction or sometimes may accompany systemic involvement. Tattoo-associated sarcoidal granuloma in a patient with systemic sarcoidosis was first described by Lubeck and Epstein.³ Afterwards, this unusual association has been reported in a limited number of cases, even as the first manifestation of the systemic disease.⁴⁻²² Herein, a further case of systemic sarcoidosis diagnosed with the development of granulomatous papules on a tattoo is described.

CASE REPORT

A 32 year-old male was admitted with papular lesions over his 6 year-old tattoo for the last 6 months. The patient also complained of an effort dysp-

nea. On dermatologic examination, there were firm, 2-3 mm in diameter erythematous papules on the blue pigmented area of the tattoo on the right scapula (Figure 1). He had no other lesions on the body. The histopathology revealed non-caseating, naked epithelioid cell granulomas with asteroid bodies in the absence of acid-fast bacilli. (Figure 2a, b, c). The sedimentation rate (30 mm/h) and serum angiotensin converting enzyme (ACE) levels were elevated (106 IU; normal range: 8.3-21.4 IU). Other parameters of blood count and biochemistry, urinalysis Mantoux test, sputum for acid fast bacilli, mycologic and mycobacteriologic cultures of tissue were negative or normal. Ophthalmologic examination revealed no ocular involvement. X-ray radiography and computed tomography of the chest showed hilar lymphadenopathy and reticulonodular infiltration in the upper zones of the lung. Diagnosis of "tattoo sarcoidosis with pulmonary involvement" was thus confirmed. Upon recommendations of chest disease hydroxychloroquine (200 mg/day) orally together with topical clobetasol propionate (0.05%) were initiated and resolution of papular lesions and dyspnea within 6 weeks were observed.

DISCUSSION

Scar sarcoidosis is an uncommon form of cutaneous sarcoidosis arising on old scars. Rarely, the lesion may be the unique sign of an underlying systemic disease. It may develop on the particular areas exposed to trauma such as surgery, venipuncture, vaccination or inoculation, purified protein derivative of tuberculin skin test, Kveim test as well as tattoos.¹ Previous incursions of these scars by a foreign matter, such as talc or ash at the time of trauma has been blamed in the pathogenesis of scar sarcoidosis.^{1,2}

The association between tattoos and sarcoidosis is not so clear and it raises some questions need to be answered: whether the systemic sarcoidosis manifests itself at first on the scar area⁶ or dyes of tattoo serves as a trigger for development of the sarcoidosis. In some cases, dyes of tattoo seem to play a role in the etiology. Tattoo-induced systemic sarcoid reaction has been demonstrated by showing

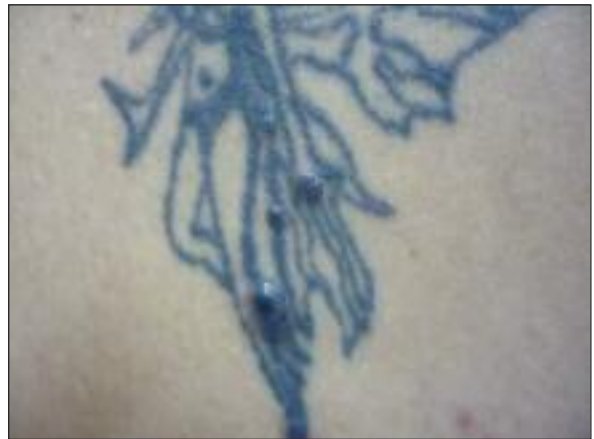

FIGURE 1: Nodules on the tattoo.

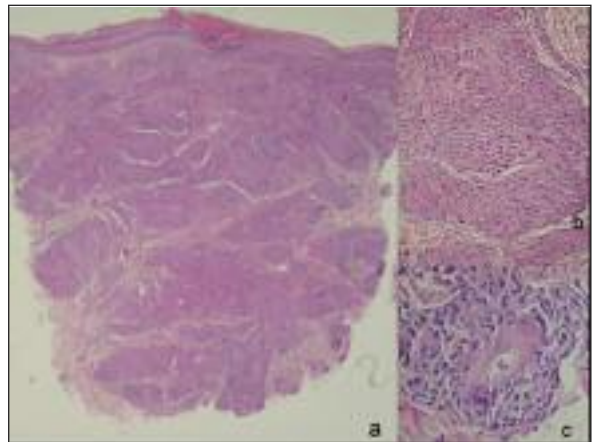


FIGURE 2: (a) Non-caseating granulomas that penetrate the whole dermis (H&E, 2x), (b) high number of granulomas in the dermis (H&E, 10x), (c) asteroid body seen in giant cells (H&E, 40x).

pigment granules in lymph nodes and the lung tissue, similar to those in the tattoos.⁶ On the other hand, tattoo changes as the first sign of systemic sarcoidosis in patients receiving interferon alpha-suggest tattooed area as a presentation side (a scar area), rather than being an etiologic factor.^{7,8} Thus, sarcoidosis resolves after discontinuation of interferon therapy, despite the presence of the tattoo. Development of sarcoid granuloma on the tattoos in patients with a known previous systemic sarcoidosis again supports the affinity of sarcoidosis to scar areas.⁹⁻¹⁰

The review of literature via "Pubmed" from 1952 to December 2008 revealed limited number

of cases (approximately 26 cases) of tattoo sarcoidosis in association with systemic involvement. Of them, the first group includes the patients with the tattoo sarcoidosis as the first manifestation of systemic sarcoidosis. And the second group includes the patients with a known previous systemic sarcoidosis in whom the cutaneous involvement manifest itself at first on the tattooed area.³⁻²² The present case falls into the first group, since he is diagnosed as systemic sarcoidosis by the typical manifestation of scar sarcoidosis on a tattoo without demonstration of pigment granules in the histopathology. The reported cases present extracutaneous findings such as hilar adenopathy, pulmonary sarcoidosis, arthritis, uveitis and iritis.³⁻²² Our patient presented hilar adenopathy, pulmonary sarcoidosis together with tattoo sarcoidosis. The latent period, between the application of tattoo and development of cutaneo-

us or systemic sarcoidosis, ranges between 1 to 45 years.³⁻²² The latent period of our patient was 6 years. In the literature, a few cases of tattoo sarcoidosis have been found to be associated with interferon alpha administration.^{7,8} However, our patient had no history of drug intake prior to the development of sarcoidosis. Different tattoo colors including red, black, yellow, blue and green may be involved on the tattoo area.³⁻²² In our case, blue color was involved.

In conclusion, sarcoidosis developing on tattoo is a rare occasion. Sarcoidosis should always be kept in mind as a differential diagnosis for granulomatous lesions that develop in areas of skin which have been exposed to exogenous substances, such as tattoo. Subsequent investigation in these cases may reveal a systemic sarcoidosis.

REFERENCES

- Kazandjieva J, Tsankov N. Tattoos: dermatological complications. *Clin Dermatol* 2007; 25(4):375-82.
- Erdi H, Taşpınar A, Gürgev E, Arit F. [Sarcoidosis (four cases of sarcoidosis with various clinical manifestations)]. *Turkiye Klinikleri J Dermatol* 1994;4(2):114-9.
- Lubeck G, Epstein E. Complications of tattooing. *Calif Med* 1952;76(2):83-5.
- Antonovich DD, Callen JP. Development of sarcoidosis in cosmetic tattoos. *Arch Dermatol* 2005;141(7):869-72.
- Landers MC, Skokan M, Law S, Storrs FJ. Cutaneous and pulmonary sarcoidosis in association with tattoos. *Cutis* 2005;75(1):44-8.
- Hanada K, Chiyoya S, Katabira Y. Systemic sarcoid reaction in tattoo. *Clin Exp Dermatol* 1985;10(5): 479-84.
- Werchniak AE, Cheng SX, Dharand AD, Klaus SN. Sarcoidosis presenting as tattoo changes in a patient undergoing treatment with interferon- α and ribavirin. *Clin Exp Dermatol* 2004;29(5):547-8.
- Nawras A, Alsolaiman MM, Mehboob S, Bartholomew C, Maliakkal B. Systemic sarcoidosis presenting as a granulomatous tattoo reaction secondary to interferonalpha treatment for chronic hepatitis C and review of the literature. *Dig Dis Sci* 2002;47(7):1627-31.
- Ali SM, Gilliam AC, Brodell RT. Sarcoidosis appearing in a tattoo. *J Cutan Med Surg* 2008;12(1):43-8.
- Blobstein SH, Weiss HD, Myskowski PL. Sarcoid granulomas in tattoos. *Cutis* 1985; 36(5):423-4.
- Perera GK, Calonje E. Systemic sarcoidosis presenting in a tattooed man undergoing treatment for hepatitis C. *Clin Exp Dermatol* 2006;31(3):387-9.
- Yesudian PD, Azurdia RM. Scar sarcoidosis following tattooing of the lips treated with mepacrine. *Clin Exp Dermatol* 2004;29(5): 552-4.
- Weidman A, Andrade R, Franks A. Sarcoidosis report of a case of sarcoid lesions in a tattoo and subsequent discovery of pulmonary sarcoidosis. *Arch Dermatol* 1966;94(3): 320-5.
- Rorsman H, Brehmer-Andersson E, Dahlquist I, Ehinger B, Jacobsson S, Linell F, et al. Tattoo granuloma and uveitis. *Lancet* 1969;2 (7610):27-8.
- Dickinson JA. Sarcoid reactions in tattoos. *Arch Dermatol* 1969;100(3):315-9.
- Farzan S. Sarcoid reaction in tattoos. *N Y State J Med* 1977;77(9):1477-9.
- Colp CR, Goldfarb R, Ongseng F. Value of gallium imaging in the evaluation of tattoo granulomas due to sarcoidosis. *Chest* 1991;100(6):1737-8.
- Iveson JM, Cotterill JA, Wright V. Sarcoidosis presenting with multiple tattoo granulomata. *Postgrad Med J* 1975;51(599):670-2.
- Sowden JM, Cartwright PH, Smith AG, Hiley C, Slater DN. Sarcoidosis presenting with a granulomatous reaction confined to red tattoo. *Clin Exp Dermatol* 1992;17(6):446-8.
- Collins P, Evans AT, Gray W, Levison DA. Pulmonary sarcoidosis presenting as a granulomatous tattoo reaction. *Br J Dermatol* 1994;130(5):658-62.
- Jones MS, Maloney ME, Helm KF. Systemic sarcoidosis presenting in the black dye of a tattoo. *Cutis* 1997;59(3):113-5.
- Ghorpade A. Inoculation sarcoid granulomas on blue-black tattoos in seven ladies. *J Eur Acad Dermatol Venereol* 2006;20(3): 349-50.