

An Unusual Presentation of Hydatid Cyst Mimicking Eosinophilic Granulomatosis Polyangiitis in a Child

Bir Çocukta Eozinofilik Granülomatoz Polianjiti Taklit Eden Nadir Bir Kist Hidatik Olgusu

^{1b} Nuran BELDER^a, ^{1b} Nihal KARAÇAYIR^a, ^{1b} Tuğba ŞİŞMANLAR EYÜBOĞLU^b, ^{1b} Merve YAZOL^c,
^{1b} Akif KAVGACI^d, ^{1b} Nursel KARA ULU^e, ^{1b} Batuhan KÜÇÜKALİ^a, ^{1b} Aylar POYRAZ^f,
^{1b} Ayşe Tana ASLAN^b, ^{1b} Gonca ERBAŞ^c, ^{1b} Semiha TOKGÖZ^d, ^{1b} Zühre KAYA^g,
^{1b} Deniz GEZGİN YILDIRIM^a, ^{1b} Sevcan BAKKALOĞLU^a

^aGazi University Faculty of Medicine, Division of Pediatric Rheumatology, Ankara, Türkiye

^bGazi University Faculty of Medicine, Division of Pediatric Pulmonology, Ankara, Türkiye

^cGazi University Faculty of Medicine, Department of Radiology, Ankara, Türkiye

^dGazi University Faculty of Medicine, Division of Pediatric Cardiology, Ankara, Türkiye

^eGazi University Faculty of Medicine, Division of Pediatric Infectious Disease, Ankara, Türkiye

^fGazi University Faculty of Medicine, Department of Pathology, Ankara, Türkiye

^gGazi University Faculty of Medicine, Division of Pediatric Hematology, Ankara, Türkiye

ABSTRACT Infectious disorders, cancer, and anti-neutrophil cytoplasm antibody-associated vasculitides are just a few of the clinical situations that can cause pulmonary nodular or cavitary lesions with cardiac thrombosis. In this case, we wanted to show how a hydatid cyst could resemble eosinophilic granulomatosis polyangiitis. A 15-year-old female patient was admitted to the hospital with a chronic cough and fatigue that had persisted for 1.5 years. Pulmonary nodules, cavitary lesions, and arterial thrombosis were found on thorax imaging, and cardiac thrombi were found on echocardiography, whereas acute phase reactants and eosinophil levels were elevated, and microscopic hematuria in urine test. These radiological and laboratory findings initially suggested eosinophilic granulomatosis with polyangiitis. A lung biopsy revealed no findings in favor of vasculitis, instead the hydatid cyst cuticle was seen. Hydatid cysts should be kept in mind in nodular/cavitary and thrombotic pulmonary involvement, and cardiac thrombus resembling vasculitis.

Keywords: Eosinophilic granulomatosis with polyangiitis; hydatid cyst; pulmonary nodules; thrombus; vasculitis

ÖZET Enfeksiyöz hastalıklar, kanser ve anti-nötrofil sitoplazmik antikor (ANCA) ilişkili vaskülitler, pulmoner nodüller veya kaviter lezyonlara ve kardiyak tromboza neden olabilen klinik durumlardan sadece birkaçıdır. Bu vakada, bir kist hidatik olgusunun eozinofilik granülomatoz polianjite (EGPA) nasıl benzeyebileceğini göstermek istedik. 15 yaşında bir kız hasta, 1,5 yıldır devam eden kronik öksürük ve yorgunluk şikayetleriyle hastaneye başvurdu. Toraks görüntülemesinde pulmoner nodüller, kaviter lezyonlar ve arteriyel tromboz saptandı; eko-kardiyografide ise kardiyak trombüsler bulundu. Akut faz reaktanları ve eozinofil düzeyleri yüksekti, idrar testinde mikroskopik hematüri mevcuttu. Bu radyolojik ve laboratuvar bulguları başlangıçta eozinofilik granülomatoz polianjiti düşündürdü. Ancak, akciğer biyopsisinde vaskülit lehine bir bulguya rastlanmadı; bunun yerine kist hidatik kutikülü görüldü. Vaskülit benzeri nodüller/kaviter ve trombotik pulmoner tutulum ile kardiyak trombüs durumlarında kist hidatik olasılığı akılda tutulmalıdır.

Anahtar Kelimeler: Eozinofilik granülomatoz polianjit; kist hidatik; pulmoner nodül; trombüs; vaskülit

TO CITE THIS ARTICLE:

Belder N, Karacı N, Şişmanlar Eyüboğlu T, Yazol M, Kavgacı A, Kara Ulu N, et al. An unusual presentation of hydatid cyst mimicking eosinophilic granulomatosis polyangiitis in a child. *Turkiye Klinikleri J Pediatr.* 2024;33(3):130-4.

Correspondence: Nuran BELDER

Gazi University Faculty of Medicine, Division of Pediatric Rheumatology, Ankara, Türkiye

E-mail: nuranbelder@gazi.edu.tr

Peer review under responsibility of Türkiye Klinikleri Journal of Pediatrics.

Received: 24 Apr 2024

Received in revised form: 25 Oct 2024

Accepted: 18 Nov 2024

Available online: 20 Dec 2024

2146-8990 / Copyright © 2024 by Türkiye Klinikleri. This is an open access article under the CC BY-NC-ND license (<http://creativecommons.org/licenses/by-nc-nd/4.0/>).



Pulmonary nodular or cavitary lesions along with arterial thrombi may be encountered in a multitude of disorders, such as infectious diseases (fungi, tuberculosis, etc.), malignancies, and vasculitides.¹ Anti-neutrophil cytoplasm antibody (ANCA)-associated vasculitides (AAV) involving small and medium-sized vessels. Eosinophilic granulomatosis with polyangiitis (EGPA) is a rare form of AAV, characterized by asthma, necrotizing vasculitis, eosinophilic inflammation, and extravascular granulomas in the lungs, heart, upper airways, or skin.² Herein, we report a patient who presented with chronic cough, multiple pulmonary nodules, pulmonary vascular thrombosis, cardiac thrombus, eosinophilia, and elevated acute phase reactants that initially mimicked EGPA but were ultimately diagnosed as cyst hydatid.

CASE REPORT

A 15-year-old female patient was referred to our pediatric rheumatology clinic with complaints of chronic cough and fatigue for a duration of 1.5 years and the detection of pulmonary nodules and intraarterial thrombosis on thorax computed tomography (CT), exhibiting resemblances to vasculitis. In her medical history, she had begun inhaler therapy nine months prior due to suspected asthma, yielding only partial success. Notably, there was no history of fever, skin rash, recurrent oral aphthae, genital ulcers, uveitis, arthralgia, and/or arthritis. In her family history, there was neither parental consanguinity nor rheumatologic disease. No pathological findings were observed during the physical examination. In laboratory work-up, acute-phase reactants were elevated [erythrocyte sedimentation rate 72 mm/h, C-reactive protein 82.7 mg/L (normal range; 0-5)]. The white blood cell count was 10,500/ μ L (59% neutrophils, 26% lymphocytes, 7.8% monocytes, and 7.2% eosinophils). Hemoglobin was 11.3 g/dL, platelet count was 325,000/ μ L. Biochemical tests yielded normal results, as did coagulation tests, except for the presence of two heterozygous mutations in the MTHFR (C677T and A1298C) gene. Homocysteine levels in the blood were 9 μ mol/L (normal range: 6-15). Urinalysis revealed microscopic hema-

turia of unexplained etiology. Serum immunoglobulin (Ig) G, IgA, and IgM levels were within normal limits; IgE levels were elevated (2,809 kUA/L). For screening vasculitis and autoimmune diseases via complement levels and antinuclear antibodies (ANA), ANA profile, ANCAs, and anti-phospholipid antibodies yielded negative results. The angiotensin-1-converting enzyme level was normal. The human leukocyte antigen B51 and pathergy tests were resulted negative for Behçet's disease. The ophthalmological examination revealed no pathological findings. The chest X-ray showed multiple nodules. Subsequent thorax CT and angiography revealed bilateral multiple pulmonary nodules, thrombus formations, and enlargement in the segmental branches of the pulmonary arteries located in the lungs (Figure 1a). The imaging findings were not suggestive of malignancy. The patient was consulted with the pediatric infectious diseases and pulmonology departments to determine the etiology of the cavitating nodular lesion in the lung parenchyma and other infiltration areas compatible with a ground-glass appearance on the thorax CT (Figure 1b). Severe acute respiratory syndrome coronavirus 2 polymerase chain reaction, tuberculosis acid-resistant bacilli direct microscopic examination, quantiferon, and galactomannan tests, returned negative results. There was no growth in any culture. For the differential diagnosis of the pulmonary nodule, no infectious agents (viral, bacterial, mycobacterial, fungal) were identified. Abdominal ultrasonography (USG), abdominal, bilateral extremities arterial Doppler USG examinations yielded normal findings. Echocardiography revealed a hyper-echogenic mass image compatible with a 1.8 to 1.5 cm-sized thrombus attached to the septal leaflet of the tricuspid valve in the right atrium (Figure 1c). Cardiac magnetic resonance imaging (MRI) confirmed the presence of the thrombus (Figure 1d). Low-molecular-weight heparin was started. The presence of chronic cough, microscopic haematuria, and eosinophilia prompted us to think about EGPA and related thrombus formation as possible diagnosis. Therefore, a lung biopsy was performed to elucidate the underlying etiology or to rule out vasculitis. Within the pathology specimen, the cuticle of the hydatid cyst was identified

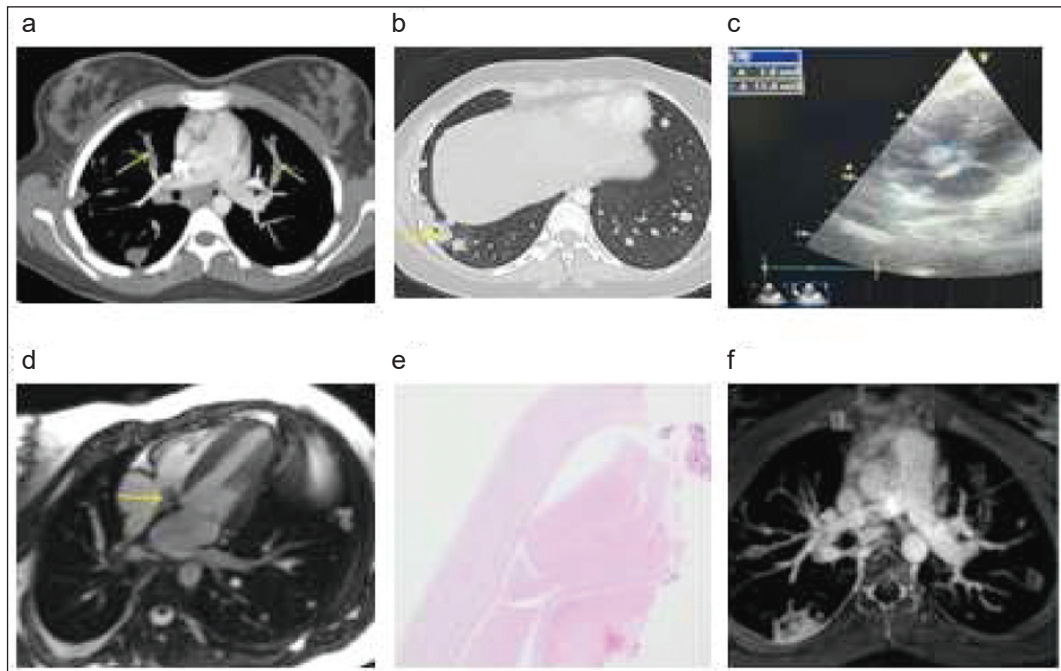


FIGURE 1: a) Pulmoner arter thrombus in thorax CT image; b) Cavitating pulmonary nodule in the lower lobe of the right lung in the thorax CT image; c) A thrombus in right atrium in the echocardiography; d) The cardiac thrombus in cardiac MRI; e) Pathology image compatible with the cyst hydatid cuticle; f) Intraarterial appearance in thoracic MRI angiography.

CT: Computed tomography; MRI: Magnetic resonance imaging.

(Figure 1e). Subsequently, a serum *Echinococcus granulosus* hemagglutination test returned a positive result at a titer of 1/1,280 and confirming the diagnosis of a hydatid cyst. The patient's thoracic MRI angiography imaging revealed nodules with cavitations in both lung parenchyma, as well as an intraarterial cyst with localized expansion and concomitant thrombus formation in the pulmonary artery branches (Figure 1f). As a result, anti-parasitic treatment was initiated. Informed consent was obtained from the patient that their information would be shared.

DISCUSSION

The clinical and laboratory findings of our patient initially indicated EGPA. However, following a comprehensive diagnostic work-up, the diagnosis of a hydatid cyst was confirmed by laboratory and pathologic studies. We want to emphasize the importance of differential diagnosis in children presenting with a

common pulmonary phenotype, such as intravascular thrombosis.

Hydatid cyst is a parasitic infection caused by *E. granulosus*. The liver and lungs are particularly affected areas, but it may also manifest in the brain, spleen, kidneys, pancreas, retroperitoneum, mediastinum, gall bladder, uterus, seminal vesicle, and spinal cord.³ While liver involvement is common in adults, the lungs are more frequently involved in children.⁴ Imaging is crucial for the diagnosis of hydatid cyst. However, the thoracic CT scan of our patient did not reveal the typical 'onion peel' and 'water-lily' signs associated with hydatid cysts.⁵ While pulmonary hydatid cyst in pediatric cases typically presents as a unilateral and solitary lesion, our patient had multiple lesions in both lungs. The presence of these findings with cardiac and intra-arterial thrombus also necessitated further detailed investigation. The presence of eosinophilia, although not as high as 10%, elevated acute phase reactants, microscopic hematuria, cardiac thrombosis, pulmonary

nodules with a history of suspected asthma collectively pointed towards a diagnosis of EGPA in our patient. Cardiovascular involvement in EGPA is common among ANCA-negative patients. Patients with EGPA may also present with myocarditis, heart failure, pericarditis, arrhythmia, coronary arteritis, valvulopathy, and intracardiac thrombosis.⁶ Our patient had a cardiac thrombus with a negative ANCA. On the other hand, the prevalence of cardiac involvement in cyst hydatid ranges between 0.2 and 2%. Echinococcus invasion of the myocardium via the coronary arterial circulation is the putative mechanism. As in our patient, the cyst hydatid may form a solid mass in the right atrium.⁷ There are also adult patients with cyst formation in the heart and thrombus formation in the remaining cyst cavity after rupture of the cyst into the circulation.⁸ Echinococcus infections of the liver may cause nonthrombotic pulmonary emboli due to the rupture of hydatid cysts and the circulation of daughter vesicles from the liver to the pulmonary arteries.⁹ It may also cause Budd-Chiari syndrome because of the occlusion of the venous system by the cystic lesions of the parasite.¹⁰ The thrombus may progress towards the right heart, resulting in thrombotic pulmonary embolism.¹¹ Although our patient's primary cystic lesions were not initially visible in the pulmonary arteries and right atrium, the presence of cardiac and pulmonary artery thrombi was thought to be due to a nidus formed by the parasite's daughter's vesicles. Inflammation and endothelial damage occurring in and around the nidus lead to thrombus development. Thrombus formation with the appearance of intraarterial cysts was detected on thoracic MRI angiography. Albendazole is the most commonly used antiparasitic agent for the treatment of *E. granulosus*. Mebendazole could also be used, albeit with less effectiveness.¹² Surgical resection and percutaneous aspiration of the cyst are also among

the treatment options. The choice of treatment modality is based on the size, type, and location of the cysts and associated complications.¹³

In conclusion, rheumatologic and infectious diseases may present with similar clinical findings. Therefore, in cases of nodular or cavitary pulmonary involvement and cardiopulmonary system thrombosis resembling vasculitis, hydatid cysts should be kept in mind, particularly in regions where the disease is endemic. Hence, maintaining a heightened level of clinical suspicion is crucial for accurate differential diagnoses.

Acknowledgment

The authors are grateful to the patient and his family.

Source of Finance

During this study, no financial or spiritual support was received neither from any pharmaceutical company that has a direct connection with the research subject, nor from a company that provides or produces medical instruments and materials which may negatively affect the evaluation process of this study.

Conflict of Interest

No conflicts of interest between the authors and / or family members of the scientific and medical committee members or members of the potential conflicts of interest, counseling, expertise, working conditions, share holding and similar situations in any firm.

Authorship Contributions

Idea/Concept: Deniz Gezgin Yıldırım; **Design:** Nihal Karaçayır; **Control/Supervision:** Sevcin Bakkaloğlu; **Data Collection and/or Processing:** Nuran Belder; **Analysis and/or Interpretation:** Batuhan Küçükali, Akif Kavgacı; **Literature Review:** Merve Yazol; **Writing the Article:** Nuran Belder; **Critical Review:** Ayşe Tana Aslan, Tuğba Şişmanlar Eyüboğlu, Zühre Kaya; **References and Findings:** Gonca Erbaş, Nursel Kara Ulu; **Materials:** Aylar Poyraz, Semiha Tokgöz.

REFERENCES

1. Parkar AP, Kandiah P. Differential diagnosis of cavitory lung lesions. *J Belg Soc Radiol.* 2016;100(1):100. [[Crossref](#)] [[PubMed](#)] [[PMC](#)]
2. David AC, Kimberly AM. Antineutrophil cytoplasmic antibody associated vasculitis. In: Petty RE, Laxer R, Lindsley C, Wedderburn L, Mellins ED, Fuhlbrigge RC, eds. *Textbook of Pediatric Rheumatology.* 8th ed. Elsevier Health Sciences; 2021.
3. Mushtaque M, Mir MF, Malik AA, Arif SH, Khanday SA, Dar RA. Atypical localizations of hydatid disease: experience from a single institute. *Niger J Surg.* 2012;18(1):2-7. [[Crossref](#)] [[PubMed](#)] [[PMC](#)]
4. Kanat F, Turk E, Aribas OK. Comparison of pulmonary hydatid cysts in children and adults. *ANZ J Surg.* 2004;74(10):885-9. [[Crossref](#)] [[PubMed](#)]
5. Sodhi KS, Bhatia A, Samujh R, Mathew JL, Lee EY. Prospective comparison of MRI and contrast-enhanced MDCT for evaluation of pediatric pulmonary hydatid disease: added diagnostic value of MRI. *AJR Am J Roentgenol.* 2019;212(5):982-7. [[Crossref](#)] [[PubMed](#)]
6. Brucato A, Maestroni S, Masciocco G, Ammirati E, Bonacina E, Pedrotti P. Il coinvolgimento cardiaco nella sindrome di Churg-Strauss [Cardiac involvement in Churg-Strauss syndrome]. *G Ital Cardiol (Rome).* 2015;16(9):493-500. Italian. [[PubMed](#)]
7. Biyik I, Acar S, Ergene O. Left atrial mobile hydatid cyst mimicking left atrial myxoma and mitral stenosis and causing heart failure and arrhythmia. *Int J Cardiovasc Imaging.* 2007;23(2):193-5. [[Crossref](#)] [[PubMed](#)]
8. Sabzi F, Madani H, Dabiri S, Pormotabed A, Faraji R. Thrombotic cardiac apex hydatid cyst. *Indian Heart J.* 2015;67(6):577-80. [[Crossref](#)] [[PubMed](#)] [[PMC](#)]
9. Turan T, Çakmak A, Çapraz M, Aykan AÇ. Interventricular septal cardiac hydatid cyst mimicking hypertrophic cardiomyopathy. *Anadolu Kardiyol Derg.* 2013;13(3):E19-20. [[PubMed](#)]
10. Rasheed K. Hydatid cyst of liver complicated with budd-Chiari syndrome and portal vein thrombosis. *N Am J Med Sci.* 2013;5(3):242-4. [[Crossref](#)] [[PubMed](#)] [[PMC](#)]
11. Sabzi F, Faraji R. Multiple complications by hydatid cyst-induced budd chiari syndrome: a case report. *Iran J Parasitol.* 2017;12(1):148-51. [[PubMed](#)] [[PMC](#)]
12. Guidelines for treatment of cystic and alveolar echinococcosis in humans. WHO Informal Working Group on Echinococcosis. *Bull World Health Organ.* 1996;74(3):231-42. [[PubMed](#)] [[PMC](#)]
13. Brunetti E, Kern P, Vuitton DA; Writing Panel for the WHO-IWGE. Expert consensus for the diagnosis and treatment of cystic and alveolar echinococcosis in humans. *Acta Trop.* 2010;114(1):1-16. [[Crossref](#)] [[PubMed](#)]