

## CASE REPORT

DOI: 10.5336/caserep.2022-91402

# A Case of Primary Thyroid Tuberculosis Presenting with Multinodular Goiter

Oğuzhan Fatih AY<sup>a</sup>, Hülya HAKSEVER<sup>b</sup>, Mehmet Emrah BAYAM<sup>a</sup>, Özgür DAĞLI<sup>c</sup><sup>a</sup>Clinic of General Surgery, Bursa Yüksek İhtisas Education and Research Hospital, Bursa, Türkiye<sup>b</sup>Clinic of Pathology, Bursa Yüksek İhtisas Education and Research Hospital, Bursa, Türkiye<sup>c</sup>Clinic of Infectious Disease, Bursa Yüksek İhtisas Education and Research Hospital, Bursa, Türkiye

**ABSTRACT** Thyroid tuberculosis is a very rare condition with a rate of 0.1-1.15% even in countries with a high prevalence of tuberculosis. In this presentation, we evaluated the management of a patient with a preoperative diagnosis of benign tissue and a pre-diagnosis of multinodular goiter with compression symptoms. After thyroidectomy of our patient who had no special history due to the detection of Langerhans giant cell caseified granuloma-thyroid tuberculosis, postoperative thyroid replacement therapy and infectious diseases outpatient control were planned. Thyroid tuberculosis is not easy to diagnose because there are no specific symptoms. If no other foci are detected after total thyroidectomy, close follow-up is recommended without additional antituberculosis therapy. As the incidence of tuberculosis increases worldwide, thyroid tuberculosis as the unusual involvement of extrapulmonary tuberculosis; it should be kept in mind in the differential diagnosis of nodular lesions of the thyroid gland.

**Keywords:** Thyroid diseases; goiter; tuberculosis

Tuberculosis is still one of the most important causes of morbidity and mortality despite advances in medical techniques and care services. Thyroid tuberculosis (TTB) is a rare condition even in developing countries where tuberculosis is endemic.<sup>1</sup> The incidence of TTB is estimated to be between 0.1-1.15%.<sup>2</sup> TTB is examined in 2 categories as primary and secondary form of the disease. Primary tuberculosis; it is used only for disease localized in the thyroid gland without any other organ involvement. Secondary TTB is a form of disease that spreads from another organ, such as the larynx, lung, by hematogenous, lymphogenous or contiguous means. Clinical diagnosis of the TTB is based on histopathological examination and microbiological cultures since imaging methods are not specific.<sup>3</sup>

## CASE REPORT

A 40-year-old female patient with no known chronic disease and no history of surgery she applied to the

general surgery outpatient clinic with swelling in her neck and mild swallowing difficulty for about 3 years. The patient did not smoke, did not describe weight loss and night sweats. There was no familial history of tuberculosis.

On physical examination, there was no pathological feature except swelling in the neck region.

The patient was clinically euthyroid. Other blood laboratory tests were unremarkable. Thyroid ultrasonography reported as heterogeneous multinodular goiter, the largest of which was 4 cm. There was no obvious pathology in the chest x-ray. Preoperative fine needle aspiration biopsy (FNAB) was consistent with benign findings. Considering the patient's compression symptoms and the size of the nodules, total thyroidectomy was planned. The patient was operated after obtaining consent for further examination, treatment and availability of data for scientific publications.

**Correspondence:** Oğuzhan Fatih AY

Clinic of General Surgery, Bursa Yüksek İhtisas Education and Research Hospital, Bursa, Türkiye

**E-mail:** droguzhanf.ay@gmail.com



Peer review under responsibility of Türkiye Klinikleri Journal of Case Reports.

**Received:** 20 May 2022

**Accepted:** 19 Sep 2022

**Available online:** 21 Sep 2022

2147-9291 / Copyright © 2022 by Türkiye Klinikleri. This is an open access article under the CC BY-NC-ND license (<http://creativecommons.org/licenses/by-nc-nd/4.0/>).

The patient was discharged on the third post-operative day uneventfully. When the patient came to her routine controls, it was seen that the total thyroidectomy material was reported as “caseating granulomatous thyroiditis, nodular hyperplasia, adenomatous nodules” (Figure 1, Figure 2). Thyroid replacement therapy and infectious diseases polyclinic control were recommended to the patient. Since the patient had no respiratory symptoms and was a case of extrapulmonary tuberculosis, sputum acid-resistant bacillus swab sample was not requested at infectious diseases outpatient clinic. The patient was diagnosed with primary thyroid tuberculosis. No additional anti-tuberculosis treatment was given. Post-operative follow-up was recommended to the patient [Figure 2: X400, H&E (same area)].

## DISCUSSION

It is estimated that there are 8.7 million tuberculosis cases per year and 1.45 million deaths related to it.<sup>4</sup> Tuberculosis infection is classified into 2 types: pulmonary and extrapulmonary. Tuberculosis can be seen in many parts of the body in endemic areas. TTB is rare even in these regions.

The reason why the thyroid gland is rarely involved by tuberculosis bacillus is not clear. However, 4 hypotheses are put forward: 1) Colloid material has bactericidal effect. 2) The thyroid gland gets too much blood and stores iodine. 3) Destruction of tuberculosis bacillus due to the activity of increased

phagocytes in hyperthyroidism. 4) Anti-tuberculosis efficacy of thyroid hormones.<sup>2</sup>

Primary TTB is difficult to explain and rare. While it is seen in 2-7% of cases in autopsy series, it is between 0.1-1.15% in pathological examinations. This difference can be understood by the difficulty in diagnosis and not considering TTB in the differential diagnosis.<sup>3</sup> Diagnosis of TTB is difficult, since there are no specific symptoms. It can be asymptomatic or present with various symptoms. It can be seen with diffuse goiter, multinodular goiter and isolated nodule. Pressure symptoms such as dysphagia and hoarseness may be present. Depending on the course of the disease, hypo/hyperthyroidism may be seen.<sup>1</sup> Our patient showed multinodular goiter in euthyroid state and presenting with compression symptoms. Although FNAB is helpful in diagnosis about half of the cases of TTB reported in the literature were diagnosed after surgery.<sup>1</sup> Shin Jie and colleagues diagnosed TTB after hemithyroidectomy.<sup>4</sup> FNAB examination performed in our patient was reported as a benign colloidal nodule and was not compatible with the post-operative outcome.

Although there is no consensus on this issue; in cases of TTB who have undergone total thyroidectomy, further investigations should be performed to detect a different focus and if no other focus is found, close follow-up is recommended without administration of antituberculous drugs. If additional focus is found, additional anti-TB drug should be started for 6 months.<sup>3</sup> Together with the infectious diseases poly-

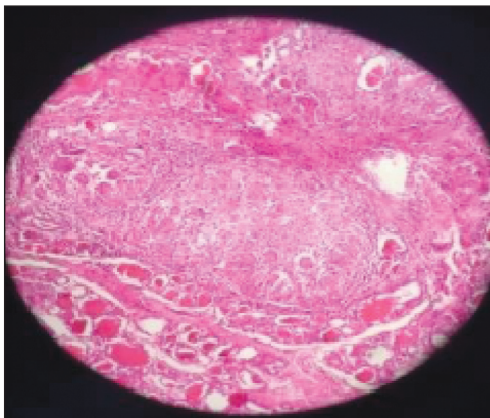


FIGURE 1: X200, H&E, caseified granuloma structure with thyroid follicles and Langhans giant cells.

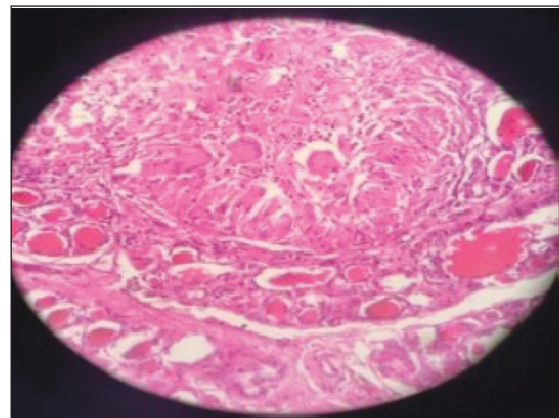


FIGURE 2: X400, H&E (same area).

clinic of our hospital; we suggested that our patient diagnosed with primary TTB should be followed up after total thyroidectomy without antituberculosis treatment.

TTB should be kept in mind in the differential diagnosis of multinodular goiter in endemic regions. Approximate treatment should be evaluated according to the form and clinic of the infection.<sup>2,3</sup>

#### **Source of Finance**

*During this study, no financial or spiritual support was received neither from any pharmaceutical company that has a direct connection with the research subject, nor from a company that provides or produces medical instruments and materials which may negatively affect the evaluation process of this study.*

#### **Conflict of Interest**

*No conflicts of interest between the authors and / or family members of the scientific and medical committee members or members of the potential conflicts of interest, counseling, expertise, working conditions, share holding and similar situations in any firm.*

#### **Authorship Contributions**

**Idea/Concept:** Mehmet Emrah Bayram; **Design:** Oğuzhan Fatih Ay; **Control/Supervision:** Mehmet Emrah Bayram; **Data Collection and/or Processing:** Oğuzhan Fatih Ay; **Analysis and/or Interpretation:** Hülya Haksever; **Literature Review:** Oğuzhan Fatih Ay; **Writing the Article:** Oğuzhan Fatih Ay; **Critical Review:** Özgür Dağlı; **Materials:** Hülya Haksever.

## REFERENCES

1. Bulbuloglu E, Ciralik H, Okur E, Ozdemir G, Ezberci F, Cetinkaya A. Tuberculosis of the thyroid gland: review of the literature. *World J Surg.* 2006;30(2):149-55. [[Crossref](#)] [[PubMed](#)]
2. Oueslati I, Sakka I, Ismail O, Akrouf I, Marghli A, Chihaoui M. Tuberculosis of the thyroid gland presented as a rapid enlargement of a preexisting goiter. *Case Rep Endocrinol.* 2018;2018:4369531. [[Crossref](#)] [[PubMed](#)] [[PMC](#)]
3. Akbulut S, Sogutcu N, Arikanoğlu Z, Bakir S, Ulku A, Yagmur Y. Thyroid tuberculosis in southeastern Turkey: is this the resurgence of a stubborn disease? *World J Surg.* 2011;35(8):1847-52. [[Crossref](#)] [[PubMed](#)]
4. Chan Shin Jie S, Tan CC. A rare case of primary tuberculosis in a solitary thyroid nodule. *Indian J Tuberc.* 2020;67(3):360-2. [[Crossref](#)] [[PubMed](#)]