

A Rare Cause of Calf Pain: Extradigital Glomus Tumor: Case Report

Baldır Ağrısının Seyrek Bir Nedeni: Ekstradijital Glomus Tümörü

Gürsel SAKA, MD, Msc,^a
Salih Murat DURKAYA, MD, Msc,^a
Fatih KÜÇÜKDURMAZ, MD, Msc,^b
Necdet SAĞLAM, MD, Msc,^a
Murat Hakan KARABULUT, MD, Msc^c

Departments of
^aOrthopedics and Traumatology,
^bPathology,
Ümraniye Training and
Research Hospital,
^bDepartment of Orthopedics and
Traumatology,
Bezmiâlem Foundation University
Faculty of Medicine,
İstanbul

Geliş Tarihi/Received: 19.06.2010
Kabul Tarihi/Accepted: 22.04.2011

Yazışma Adresi/Correspondence:
Fatih KÜÇÜKDURMAZ, MD, Msc
Bezmiâlem Foundation University
Faculty of Medicine,
Department of Orthopedics and
Traumatology, İstanbul,
TÜRKİYE/TURKEY
fatihmfk@hotmail.com

ABSTRACT Glomus tumors are rare small benign neoplasms of the dermis or subcutis and originate from the neuromyoarterial glomus body. They most frequently develop in the nail bed of the hands, and their occurrence in other parts of the body is rare. A 25 years old male patient presented to our clinic with calf pain for the last 5 years. Physical examination revealed a 1x1 cm painful, semimobile lesion within the right gastrocnemius muscle. Direct X-rays revealed no pathology. In magnetic resonance imaging, edema was detected in the right gastrocnemius muscle. The mass was excised and histopathologic examination revealed glomus tumor. The patient was cured and no recurrence developed during the 25-month follow-up.

Key Words: Glomus tumor; muscle, skeletal; pain

ÖZET Glomus tümörü cilt veya cilt altı dokusunun nadir görülen, küçük, iyi huylu neoplazmlardır ve nöromiyoarteriyel glomus cisimlerinden köken alır. Bunlar daha sıklıkla elde tırnak yatağında bulunurlar ve vücudun diğer bölgelerinde nadir görülürler. Yirmi beş yaşında bir erkek hasta, 5 yıldır süren baldır ağrısı ile başvurdu. Fizik bakıda 1x1 cm çapında ağrılı, yarı hareketli bir lezyon sağ gastroknemius kası proksimalinde palpe edildi. Doğrudan radyografilerde patoloji görülmedi. Manyetik rezonans görüntüleme taramasında sağ gastroknemius kasının proksimalinde minimal musküler ödem izlendi. Kitle eksize edildi ve histopatolojik tanı glomus tümörü olarak rapor edildi. Postoperatif 25 aylık takip sonucunda hastanın yakınmaları tamamen düzeldi ve nüks izlenmedi.

Anahtar Kelimeler: Glomus tümörü; kas, iskelet; ağrı

Türkiye Klinikleri J Med Sci 2012;32(3):854-8

Glomus tumor, which is also named as glomangioma or glomangiomyoma, is a rare small benign neoplasm of the dermis or subcutis. They are frequently solitary and rarely multiple lesions.^{1,2-5} Although this tumor has been known for many years, Wood first announced it as painful subcutaneous tubercles in 1812 and its histological details were defined by Mason in 1924.^{2,6,7}

Although glomus corpuscles are distributed all around the skin, they are mostly cumulated at the distal phalanx.^{1,8-11} They surround arteriovenous anastomoses of cutaneous tissue and function in the regulation of temperature. Extradigital musculoskeletal tumors are rarely (sporadically) reported in the literature.

An extradigital musculoskeletal tumor, which caused calf pain, is reported in this paper. According to our knowledge, this is the only extradigital glomus tumor case located in the gastrocnemius muscle.

CASE REPORT

A male patient, twenty-five years old, presented to the hospital with gradually increasing pain through the proximal right cruris for the last five years. His complaints began with a trauma while he was playing football. Although he used nonsteroid anti-inflammatory drugs intensively and had physical therapy at different clinics, his complaints did not relieve. The patient stated that the intensity and frequency of pain increased throughout that period. The severe pain was continuous, especially occurring at night, with the touch of sheets and on minimal contact or palpation. During the day, the pain was troublesome when walking fast and with deep flexion while ascending and descending stairs.

PHYSICAL EXAMINATION

A 1x1 cm, extremely sensitive, semi-mobile, nodular lesion was palpated superficially at the proximal right cruris through the midline of the gastrocnemius muscle. The skin was superficially normal in appearance. Although an extremely sensitive point was diagnosed on the right calf with minimal compression, there was no edema, color change or local hyperemia. There was 2 cm disuse atrophy through the midline of the right cruris. Physical examination of the hip and the spine was normal. Neurologic examination of both lower extremities was normal and there was full range of motion.

RADIOLOGY

Direct radiography was normal without any calcification or osseous pathology. In magnetic resonance imaging (MRI) scan, FAT-SAT T2A sequence demonstrated minimal muscular edema in subcutaneous tissue at the coronal slice (Figure 1).

OPERATION

After informed consent was obtained from the patient, the mass was excised with an extended resection including skin and subcutaneous tissues

under general anesthesia (Figure 2). The specimen was reserved for pathologic-histological evaluation (Figure 3 and Figure 4).

PATHOLOGIC EXAMINATION

The resected specimen revealed a 0.4 x 0.3 x 0.3 cm well circumscribed, red-blue, small, and firm nodule in the subcutaneous tissue. Histologic evaluation demonstrated a well-circumscribed nodule, characterized by sheets and occasional nests of uniform, round cells with central hyperchromatic nuclei and pale eosinophilic cytoplasm (glomus cells), surrounded by capillary coil. These tumor cells were strongly positive with smooth muscle actin (SMA) and vimentin.

POSTOPERATIVE EXAMINATION

During the examination immediately after the surgical excision, the patient expressed that his pain and the sensitivity related to palpation had completely disappeared. The patient had no complaints through 25 months of post-operative follow-up.

DISCUSSION

Glomus tumors are benign neoplasms, which are rarely seen and originate from endomyoarterial corpuscles involved in thermoregulation. They frequently develop in middle-aged men and are localized on the distal phalanges of the hands. In English literature, extradigital musculoskeletal glomus tumors are very rare and sporadic cases. It may be difficult to diagnose glomus tumors with atypical localizations. The misdiagnosis or late diagnosis of the tumor is attributed to the nonpalpable nature of the tumor. Under these circumstances, the patient's story and clinical examination is very important.

Glomus tumors are frequently located in the phalanx. Extradigital glomus tumors are also reported. Although they are designated extradigital, they are located on the extremity and extradigital and not located in extremities. Although the majority assume that glomus tumors originate from Sucquet Hayer, an arterial segment of the glomus corpuscle, some authors reported localizations such as gastric, pulmonary, tracheal, intraneural, fallopian tube, which do not include the glomus corpus-

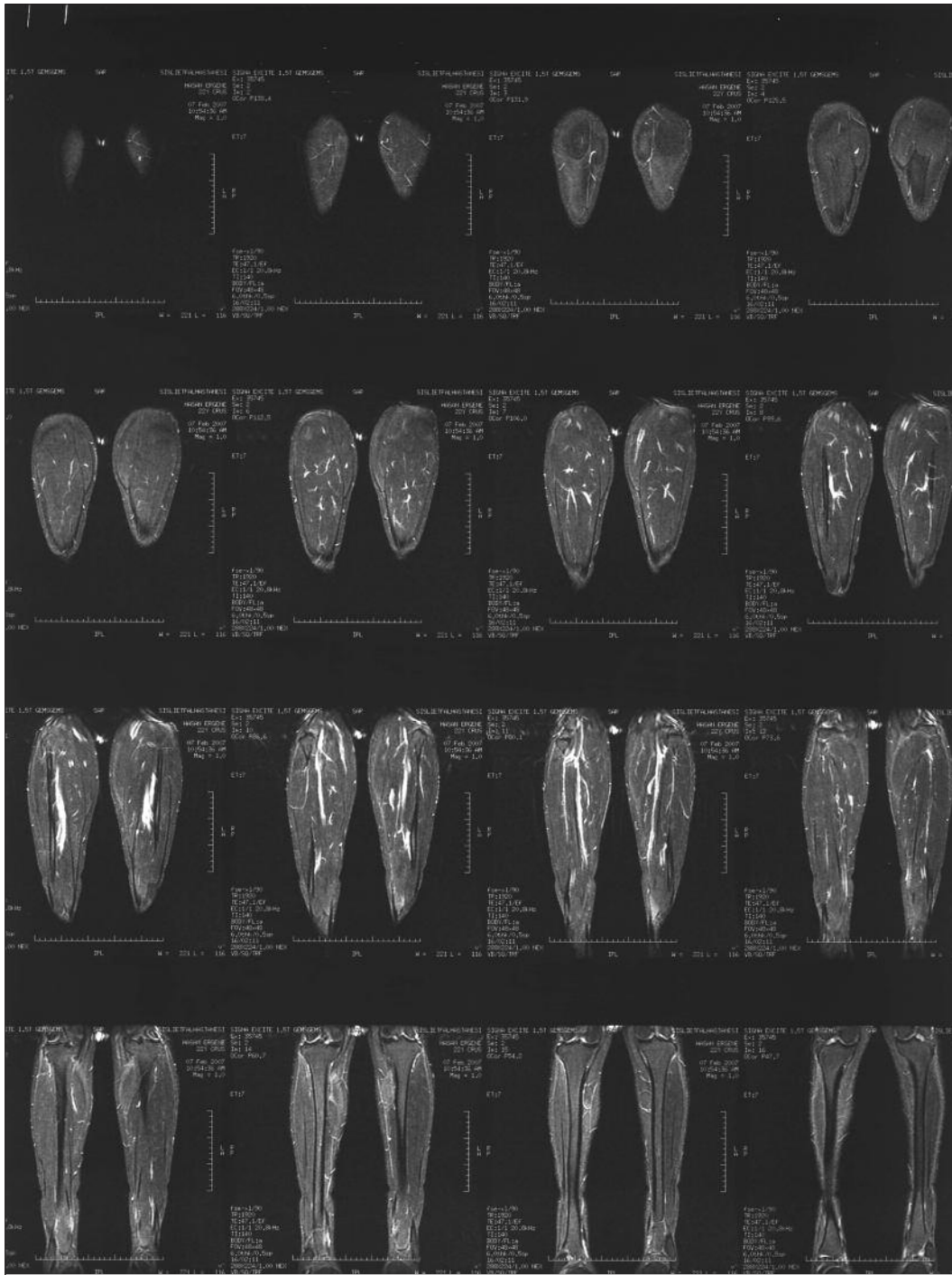


FIGURE 1: Very small hypointense mass located in the subcutaneous tissue on magnetic resonance imaging view of the right thigh.

cle.¹² The extradigital glomus tumor of the extremities may be localized on the thigh, knee, quadriceps, patellar ligament, foot, ankle, heel pad, gastrocnemius muscle, achilles tendon, rotator cuff, wrist, forearm, elbow and triceps tendon.^{1,2,4,6-9,12-}

²⁰ Our extradigital glomus tumor case was located on the extremity and the first case was located within the gastrocnemius muscle. The other report with quadriceps localization is a case with multiple recurrences.

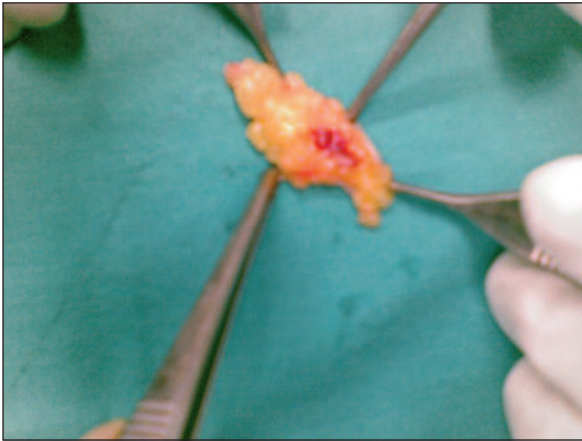

FIGURE 2: Operative view of the tumor after excision. Blood vessels can be seen entering the tumor mass.

(See for colored form <http://tipbilimleri.turkiyeklinikleri.com/>)

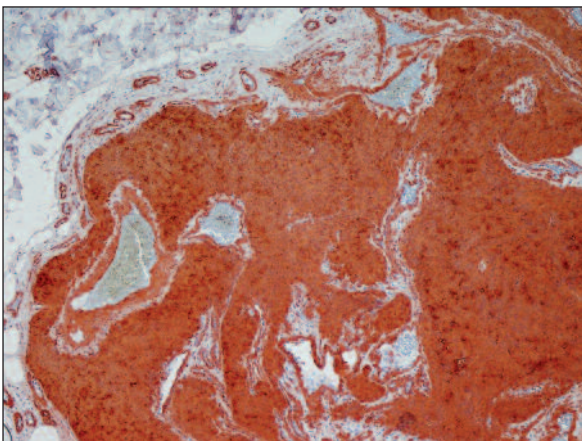


FIGURE 3: Glomus tumor, strong positive immunexpression with smooth muscle actin (SMA) in the glomus cells (SMA,X200).

(See for colored form <http://tipbilimleri.turkiyeklinikleri.com/>)

Glomus tumor has a classical triad of symptoms, which are cold hypersensitivity, pain and pinpoint sensitivity with palpation. Although these constitute the classical triad, some patients may lack some of those symptoms. Classical triad is present between 63% and 100% of patients according to different studies.^{12,13} Localized pain and sensitivity could be diagnosed in 86% of cases but cold intolerance is present in only less than 2% of the cases.¹²

Glomus tumors could be easily differentiated from hemanjiomas or melanomas by cold hypersensitivity, extreme pain despite its small dimension and extreme sensitivity even to light touch.

Disuse atrophy is reported at shoulder, calf, femoral and gluteal muscles in the literature. This complication is partly reversible. In our case, 2 cm disuse atrophy was measured at the midline level of the cruris.

Ultrasonography has a low diagnostic value.^{8,21} However, MRI is the most sensitive radiographic method not only in diagnosis but also in determining the localization of the lesion. The typical appearance of glomus tumor in MRI is decreased signal intensity in T1 and decreased signal intensity in T2-weighted images. MRI has false-negative results in very small-sized lesions. Specificity of MRI for glomus tumor is 50%.¹² Definitive diagnosis is made by means of histopathological investigation.

Malignant transformation is very rare.³ The malignant transformation potential of the tumor depends on the presence of some histologic characteristics like atypia, increased mitotic activity, high nuclear grade. Besides, it is more common in tumors with large extension or deep-localization such as under fascia or visceral localization. Under these circumstances, a wide resection should be planned.³

Treatment is surgical excision.²² Generally, symptoms disappear immediately after surgical resection. The rate of recurrence is between 12% and 33% in the literature.¹² However, it is controversial whether it is actual recurrence or the existence of multiple lesions. Recurrence of these symptoms

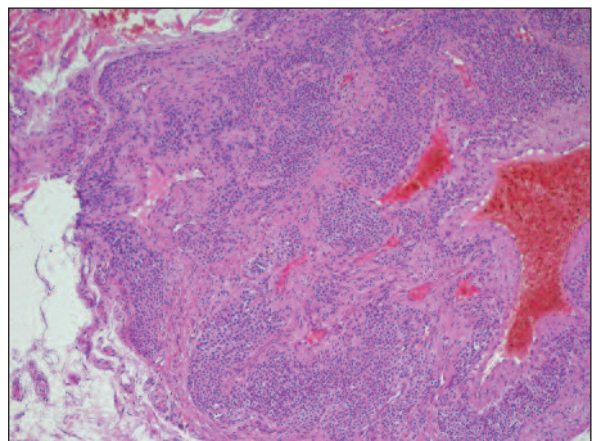


FIGURE 4: Glomus tumor; well-defined sheets of uniform glomus cells surrounding the capillaries (H+E,X200).

(See for colored form <http://tipbilimleri.turkiyeklinikleri.com/>)

within a few days or a week after the operation could refer to insufficient excision whereas the recurrence of post-operative symptoms within two or three years could refer to a multiple tumor.¹²

As a result, it should be kept in mind that glomus tumors may be misdiagnosed as myalgia or sciatica in lower extremity as in our case. Diagnosis is usually made clinically.

REFERENCES

1. Amillo S, Arriola FJ, Muñoz G. Extradigital glomus tumour causing thigh pain: a case report. *J Bone Joint Surg Br* 1997;79(1):104-6.
2. Caughey DE, Highton TC. Glomus tumour of the knee. Report of a case. *J Bone Joint Surg Br* 1966;48(1):134-7.
3. Folpe AL, Fanburg-Smith JC, Miettinen M, Weiss SW. Atypical and malignant glomus tumors: analysis of 52 cases, with a proposal for the reclassification of glomus tumors. *Am J Surg Pathol* 2001;25(1):1-12.
4. Mabit C, Pécout C, Arnaud JP. Glomus tumor in the patellar ligament. A case report. *J Bone Joint Surg Am* 1995;77(1):140-1.
5. Panagiotopoulos E, Maraziotis T, Karageorgos A, Dimopoulos P, Koumoundourou D. A twenty-year delay in diagnosing a glomus knee tumor. *Orthopedics* 2006;29(5):451-2.
6. Smyth M. Glomus-cell tumors in the lower extremity. Report of two cases. *J Bone Joint Surg Am* 1971;53(1):157-9.
7. Quigley JT. A glomus tumor of the heel pad. A case report. *J Bone Joint Surg Am* 1979;61(3):443-4.
8. Chiang ER, Chen TH. Multiple glomus tumors in gastrocnemius muscle: a case report. *Arch Orthop Trauma Surg* 2008;128(1):29-31.
9. Nakamura Y, Nomura T, Ookubo M, Adati T, Harada D. Extradigital glomus tumor causing para-Achilles tendon pain. A case report. *Acta Orthop Belg* 2000;66(5):503-6.
10. Puchala M, Kruczynski J, Szukalski J, Lianeri M. Glomangioma as a rare cause of knee pain. A report of two cases. *J Bone Joint Surg Am* 2008;90(11):2505-8.
11. Okahashi K, Sugimoto K, Iwai M, Kaneko K, Samma M, Fujisawa Y, et al. Glomus tumor of the lateral aspect of the knee joint. *Arch Orthop Trauma Surg* 2004;124(9):636-8.
12. Schiefer TK, Parker WL, Anakwenze OA, Amadia PC, Inwards CY, Spinner RJ. Extradigital glomus tumors: a 20-year experience. *Mayo Clin Proc* 2006;81(10):1337-44.
13. Yoshikawa G, Murakami M, Ishizawa M, Matsumoto K, Hukuda S. Glomus tumor of the musculotendinous junction of the rotator cuff. A case report. *Clin Orthop Relat Res* 1996; (326):250-3.
14. Tomak Y, Dabak N, Ozcan H. Extradigital glomus tumor of the triceps tendon as a cause of elbow pain: a case report. *J Shoulder Elbow Surg* 2003;12(4):401-2.
15. Oztekin HH. Popliteal glomangioma mimicking Baker's cyst in a 9-year-old child: an unusual location of a glomus tumor. *Arthroscopy* 2003;19(7):E19-23.
16. Takei TR, Nalebuff EA. Extradigital glomus tumour. *J Hand Surg Br* 1995;20(3):409-12.
17. Akgün RC, Güler UÖ, Onay U. A glomus tumor anterior to the patellar tendon: a case report. *Acta Orthop Traumatol Turc* 2010;44(3):250-3.
18. Hakverdi S, Kalaci A, Yaldiz M, Akansu B. Glomus tumor of the hip. An unusual location. *Saudi Med J* 2009;30(2):299-301.
19. Wahbi S, Belkourchia E, Bouhouch A, Elkharrazi M, Moustaine MR, Elmanouar M. [Glomus tumor in the quadriceps ligament: a case report]. *Rev Chir Orthop Reparatrice Appar Mot* 2005;91(3):272-5.
20. Chiang ER, Chen TH. Multiple glomus tumors in gastrocnemius muscle: a case report. *Arch Orthop Trauma Surg* 2008;128(1):29-31.
21. Chen SH, Chen YL, Cheng MH, Yeow KM, Chen HC, Wei FC. The use of ultrasonography in preoperative localization of digital glomus tumors. *Plast Reconstr Surg* 2003;112(1):115-9.
22. Sraj SA, Khoury NJ, Afeiche NE, Abdelnoor J. Thigh pain of 5 years' duration in a 48-year-old man. *Clin Orthop Relat Res* 2008;466(9):2291-5.