

Churg-Strauss Syndrome Presenting with Pericardial Effusion: Case Report

Perikardiyal Efüzyon ile Başvuran Churg-Strauss Sendromu

Onur KAYPAKLI,^a
Durmuş Yıldırım ŞAHİN,^a
Oya BAYDAR,^b
İsmail HANTA,^b
Ezgi ÖZYILMAZ,^b
Mehmet KANADAŞI^a

Departments of
^aCardiology,
^bThoracic Medicine,
Çukurova University Faculty of Medicine,
Adana

Geliş Tarihi/Received: 24.03.2011
Kabul Tarihi/Accepted: 26.05.2011

Yazışma Adresi/Correspondence:
Durmuş Yıldırım ŞAHİN
Çukurova University Faculty of Medicine,
Department of Cardiology, Adana,
TÜRKİYE/TURKEY
cardiology79@yahoo.com

ABSTRACT Churg-Strauss Syndrome (CSS) is a rare autoimmune systemic necrotizing vasculitis of unknown cause which is characterized by eosinophilic infiltration of small vessels and extravascular granulomas. Cardiac involvement, the main determinant of prognosis, is seen 17-92% in CSS. Cardiac involvement in CSS includes eosinophilic myocarditis, coronary vasculitis, coronary artery dissection, valvular heart disease, systolic dysfunction, cardiac conduction defects, arrhythmias, pericarditis and ventricular thrombus. Pericardial effusion, which is usually found incidentally with echocardiography, is a well known type of cardiac involvement in CSS and is generally well tolerated. In this report we describe a 24 year old female patient with CSS, presented with exertion and cold related dyspnea, cough, wheezing; and with moderate pericardial effusion, eosinophilia and lung infiltrates.

Key Words: Pericardial effusion; Churg-Strauss syndrome; eosinophilia

ÖZET Churg-Strauss Sendromu (CSS), küçük damarların eozinofilik infiltrasyonu ve ekstrasvasküler granülomlarla karakterize, sebebi bilinmeyen, nadir görülen bir otoimmün sistemik nekrotizan vaskülitir. CSS'de, prognozun temel belirleyicisi olan kardiyak tutulum, %17-92 oranında görülmektedir. CSS'nin kardiyak tutulumu, eozinofilik miyokardit, koroner vaskülit, koroner arter diseksiyonu, kalp kapak hastalığı, sistolik işlev bozukluğu, kardiyak iletim kusurları, aritmi, perikardit ve ventriküler trombus şeklinde görülebilir. Genellikle ekokardiyografi ile tesadüfen saptanan perikardiyal efüzyon, iyi bilinen bir kardiyak tutulum şeklidir ve genellikle iyi tolere edilir. Bu raporda efor ve soğğun tetiklediği nefes darlığı, öksürük, hışıltı ile başvuran, orta derecede perikardiyal efüzyon, eozinofili ve akciğer infiltrasyonları saptanarak CSS tanısı konan 24 yaşında bir kadın hasta sunuldu.

Anahtar Kelimeler: Perikardiyal efüzyon; Churg-Strauss sendromu; eozinofili

Türkiye Klinikleri J Cardiovasc Sci 2013;25(2):78-83

Churg Strauss Syndrome (CSS) is a rare autoimmune systemic necrotizing vasculitis of unknown cause which is characterized by eosinophilic infiltration of small vessels and extravascular granulomas.¹ CSS has three clinical periods. At the initial period, the most common symptoms are asthma and rhinitis, while the second period is characterized by transient lung infiltrates, eosinophilia in peripheral blood and various tissues. At the third period, life-threatening vasculitic involvement of various organs (purpura, peripheral neuropathy, necrotising segmental glomerulonephritis, gastrointestinal hemorrhage or perforation, pleural ef-

fusion, cardiac involvement) is seen. Mortality increases after cardiac involvement.²

The prognosis of the syndrome is usually good. Cardiac involvement, the main determinant of prognosis, is seen 17-92% in CSS.¹⁻³ Cardiac involvement in CSS includes eosinophilic myocarditis, coronary vasculitis (acute myocardial infarction due to epicardial or small artery disease), coronary artery dissection, valvular heart disease (especially mitral regurgitation), systolic dysfunction (acute heart failure), cardiac conduction defects, arrhythmias, pericarditis and ventricular thrombus. Cardiomyopathy is associated with poor prognosis if rapid development of heart failure exists.⁴ Pericardial effusion, which is usually found incidentally with echocardiography, is a well known type of cardiac involvement in CSS and generally well tolerated. In this report we describe a case of CSS presented with dyspnea, pericardial and bilateral pleural effusions.

CASE REPORT

A 24 year old female patient with no history of systemic disease or respiratory symptoms was referred to our hospital because of exertion and cold related dyspnea, wheezing and cough which had started one year earlier. She was diagnosed as asthma 2 years ago, and under leukotriene antagonist, inhaled corticosteroid, long acting beta agonist therapy. In the last two months, her respiratory symptoms were increased and a chest pain was also added. Her chest pain was increasing with lying and decreasing with leaning forward. She was hospitalized at another medical center because of these symptoms and pulmonary infiltrations. Intravenous antibiotics and intravenous methylprednisolone therapy was started. After treatment, although parenchymal infiltrations were particularly declined, the complete resolution could not be obtained. The patient was discharged before the treatment completed. After discontinuation of methylprednisolone her symptoms have increased again. The patient was hospitalized with pericardial, bilateral pleural and intra-abdominal free fluid at the cardiology department. In first physical examination, her blood

pressure and pulse were within normal limits. There was no froth or other pathological sound and murmur in the heart auscultation. In the lung auscultation, there were roncus and rales at bilateral lower and middle lung areas. Electrocardiography was normal. Cardiomegaly, parenchymal infiltrations at right paracardiac area, lateral part of right middle zone and left lower lobe were observed at the X-Ray (Figure 1). There was severe reversible airway obstruction on pulmonary function tests. Blood count and peripheral smear showed significant eosinophilia (white blood cell: 20.500/uL and eosinophils: 57%). The other laboratory parameters were normal. Moderate pericardial effusion was found in echocardiography (apex 10 mm, posterior wall 22 mm, lateral wall 16 mm, right ventricle 10 mm). Ejection fraction was normal. No wall motion abnormality was detected. In maxillofacial coronal computed tomography (CT) right maxillary, ethmoidal, sphenoidal, frontal, left maxillary and ethmoidal chronic sinusitis, in thorax CT/ High Resolution CT mediastinal and right hilar lymphadenopathy (<1 mm), pericardial effusion and bilateral diffuse infiltration areas were identified (Figure 2). All these symptoms, clinical and laboratory findings were supposed for CSS. Bronchoscopy showed extensive mucus plugs in the right system configuration. Right middle lobe bronchoalveolar lavage (BAL) was performed. Due to tachycardia and fall of saturation parenchymal biopsy was not obtained. Eosinophilia was not found in the BAL samples. Mucosal biopsy was reported as superficial bronchial mucosa. RF was positive, but ANA, c-ANCA and p-ANCA were negative. Abdominal ultrasound, neurological examination, EMG and eye examination were normal. Because the amount and location of pericardial effusion is not suitable, pericardiocentesis was not performed. With present findings, four of the six criteria of American College of Rheumatology (radiologically identified mobile or transient pulmonary infiltrates, paranasal sinus abnormalities, eosinophilia (>10%) at different white blood cell count, asthma) were present in our patient. Patient was diagnosed as CSS. Intravenous methylprednisolone (0.5

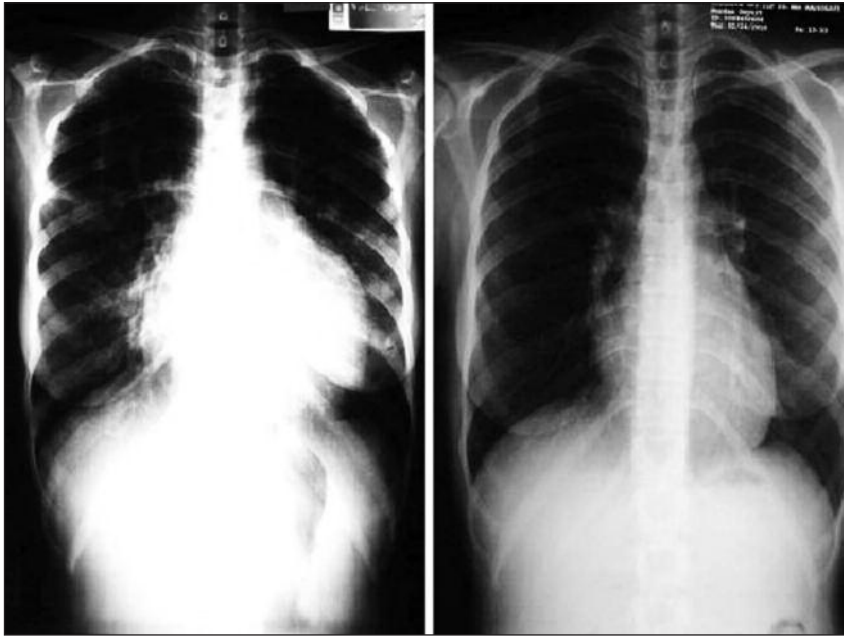


FIGURE 1: Thorax X-RAY images before treatment and after two weeks of treatment.

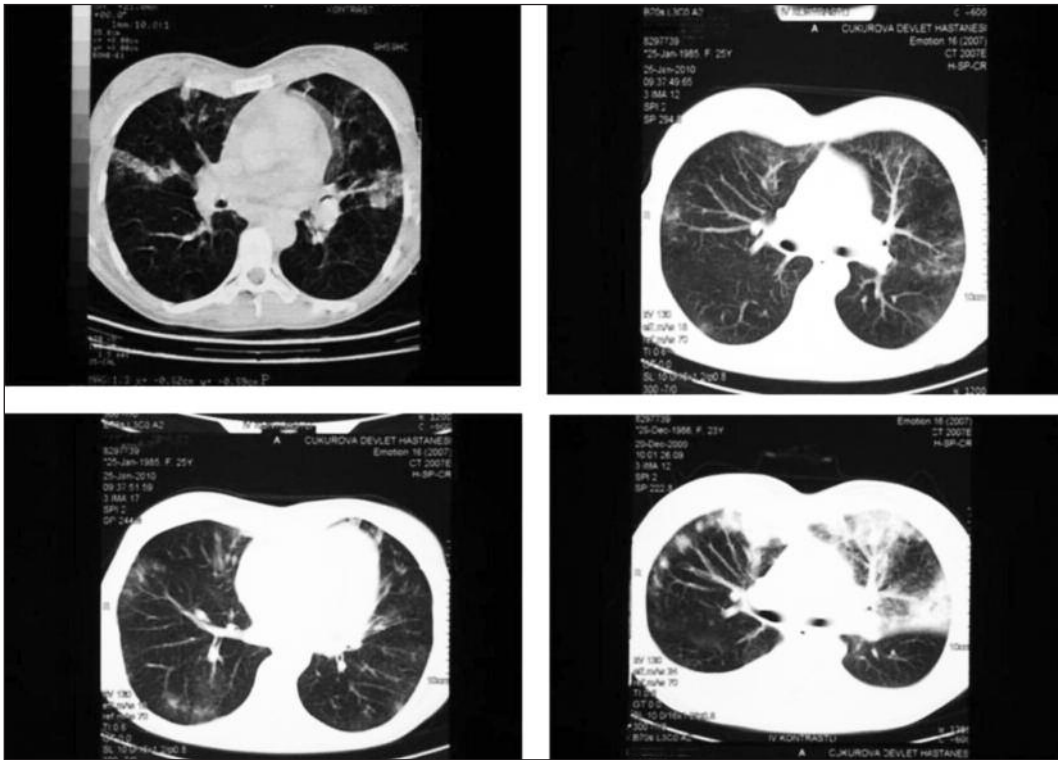


FIGURE 2: Thorax CT images before treatment.

mg/kg/day) treatment was started. Dyspnea progressively decreased after treatment and her control respiratory function tests were within normal

limits. The control echocardiography showed significant reduction of pericardial effusion at 6 months following (Figure 3).

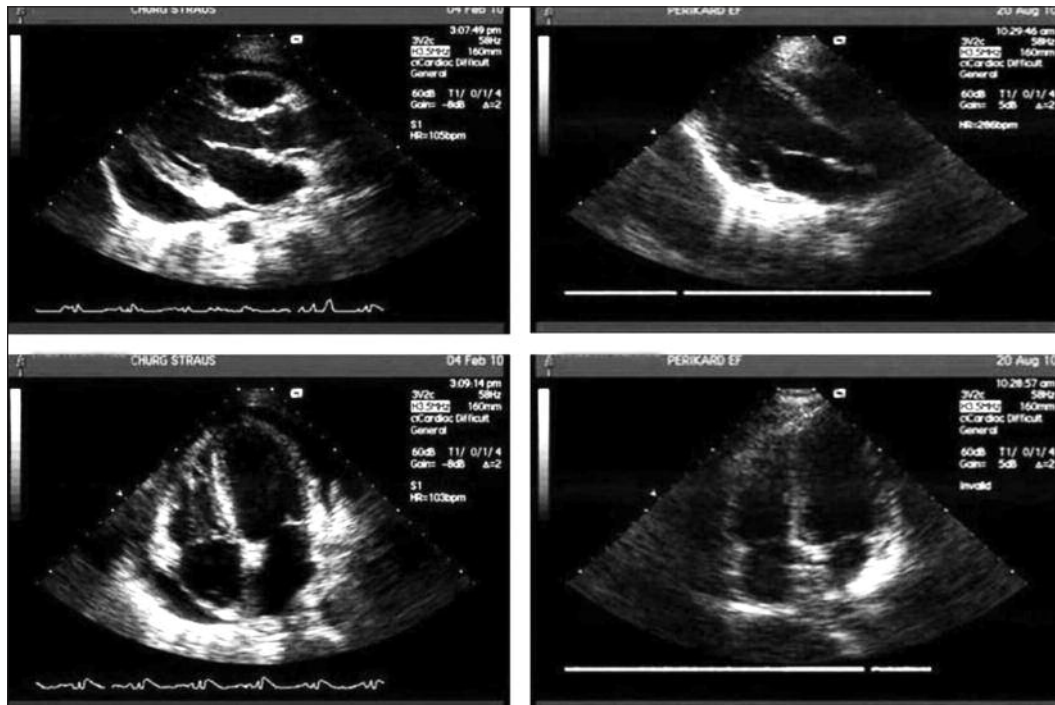


FIGURE 3: Echocardiography images before treatment and after six months of treatment.

DISCUSSION

CSS is a rare systemic disease, which must be thought when frequent symptoms such as allergic asthma and allergic rhinitis; and systemic vasculitis with multiple organ involvement or peripheral blood eosinophilia are seen together. The typical emergence of the disease includes late onset form of asthma and allergic rhinitis, blood eosinophilia and non-specific findings of vasculitis. (Fever, arthralgia, myalgia, weight loss, kidney failure, abdominal pain, cardiac involvement).^{4,5}

Even though in the first pathological identification of CSS the most common position that granuloma formation seen in the heart is pericardial region,¹ the most common emergence of cardiac involvement is heart failure due to myocarditis and coronary vasculitis and a small amount of pericardial effusion.^{6,7} In our patient, no myocardial involvement was observed in contrast to the typical form of emergence. Although there was no myocardial biopsy, myocardial involvement was not considered because there was no finding of myocardial involvement such as systolic dysfunction,

transmission defects or arrhythmias. In our case there was a cardiac involvement with moderate pericardial effusion and without myocardial involvement and heart failure. In CSS myocardial damage occurs with three basic mechanisms. At first, the disease causes direct eosinophilic myocardial damage, second myocardial ischemia caused by vasculitis. At last replacement of myocardium with granulomas and scar tissue develop. Recovery of cardiac damage is rare.³

Taking other diseases with systemic vasculitis into account, prognosis of CSS is better. In the study of Guillevin and colleagues,⁸ in the patients taking low dose steroid for persistent asthma 10-year survival ranged from 79% to 73%. However, the prognosis is worse in patients with cardiac involvement. Cardiac involvement is a poor prognostic marker. At the study of Lanham and colleagues⁴ in CSS the cause of death in 48% of patients was cardiac involvement. The criteria that American Rheumatology Association set for CSS in 1990 are: asthma, eosinophilia (>10%) at various white blood cell count, mononeuropathy (containing multiplex) or polyneuropathy, radiologically

identified mobile or transient pulmonary infiltrates, paranasal sinus abnormalities, and a biopsy sample that includes a blood vessel with extravascular eosinophiles. Four of the six criteria required for diagnosis were calculated with 85% sensitivity, specificity of 99.7%.⁹ As because our patient has four of the six criteria of American College of Rheumatology, (radiologically identified mobile or transient pulmonary infiltrates, paranasal sinus abnormalities, eosinophilia at different white blood cell count, asthma) the patient was diagnosed as CCS. And the positive response to treatment given also supported the diagnosis. Lung tissue biopsy could not be taken because of patient's clinical worsening during bronchoscopy. No pericardio-centesis could be done because of the inappropriate location and amount of pericardial effusion. So there could be no investigation on pericardial effusion and biopsy sample.

The combination of asthma and eosinophilia distinguishes this syndrome from other types of vasculitis like microscopic PAN, Wegener's syndrome. The presence of asthma separates CSS from other blood disorders such as eosinophilic leukemia, hypereosinophilic syndrome.¹⁰ CSS is one of the ANCA associated vasculitis. Although it varies between sources, the ANCA positivity in CSS is between 38% and 80 (particularly perinuclear ANCA type).⁹⁻¹¹ It has been shown that the distribution of organ involvement changes within ANCA positive or negative CSS. As presented in our case of cardiac involvement is more frequently seen in ANCA negative CCS. In our case there was no renal involvement. Renal biopsy was not per-

formed, but there was no finding of renal involvement such as the loss of renal function or proteinuria. Similarly, ANCA negative CSS has been shown to have less renal involvement.¹¹

Steroids are the basic drugs in the treatment of CSS which can provide remission and improvement in survival.¹⁰ In the recurrent disease or in patients with severe necrotizing vasculitic involvement such as cardiac and gastrointestinal involvement, cyclophosphamide therapy is recommended to be added to treatment.¹² Due to the very good response to steroid therapy, and the absence of myocardial involvement and heart failure, combination therapy was not used in our patient.

The differential diagnosis of pericardial effusions includes several etiological factors such as viral and bacterial infections, tuberculosis, myopericarditis, hypothyroidism, systemic autoimmune diseases, aortic dissection. Even though it is very rare compared with other causes in the diagnosis of pericardial effusion, CSS should be considered in cases with particularly asthma, allergic rhinitis, peripheral blood eosinophilia.

CONCLUSION

The present case illustrates that even though it is a very rare cause of pericardial effusion, if it comes to mind and is detected; cardiac involvement of CSS can successfully be treated without permanent damage in heart. Since cardiac involvement is a leading cause of death, it is very important to detect cardiac involvement as soon as possible.

REFERENCES

1. Churg J, Strauss L. Allergic granulomatosis, allergic angiitis, and periarteritis nodosa. *Am J Pathol* 1951;27(2):277-301.
2. Hasley PB, Follansbee WP, Coulehan JL. Cardiac manifestations of Churg-Strauss syndrome: report of a case and review of the literature. *Am Heart J* 1990;120(4):996-9.
3. Agard C, Rendu E, Leguern V, Ponge T, Masseur A, Barrier JH, et al. Churg-Strauss syndrome revealed by granulomatous acute pericarditis: two case reports and a review of the literature. *Semin Arthritis Rheum* 2007; 36(6):386-91.
4. Lanham JG, Elkon KB, Pusey CD, Hughes GR. Systemic vasculitis with asthma and eosinophilia: a clinical approach to the Churg-Strauss syndrome. *Medicine (Baltimore)* 1984; 63(2):65-81.
5. Çiçek D, Kandi B, Demir B, Turgut T, Dağlı F. Churg-Strauss syndrome: A case resembling erythema multiforme: differential diagnosis. *Turkiye Klinikleri J Med Sci* 2008;28(6):1002-5.
6. Hasley PB, Follansbee WP, Coulehan JL. Cardiac manifestations of Churg-Strauss syndrome: report of a case and review of the literature. *Am Heart J* 1990;120(4):996-9.
7. Terasaki F, Hayashi T, Hirota Y, Okabe M, Suwa M, Deguchi H, et al. Evolution to dilated cardiomyopathy from acute eosinophilic pericarditis in Churg-Strauss syndrome. *Heart Vessels* 1997;12(1):43-8.

8. Guillevin L, Pagnoux C, Mouthon L. Churg-strauss syndrome. *Semin Respir Crit Care Med* 2004;25(5):535-45.
9. Masi AT, Hunder GG, Lie JT, Michel BA, Bloch DA, Arend WP, et al. The American College of Rheumatology 1990 criteria for the classification of Churg-Strauss syndrome (allergic granulomatosis and angiitis). *Arthritis Rheum* 1990;33(8):1094-100.
10. Noth I, Streck ME, Leff AR. Churg-Strauss syndrome. *Lancet* 2003;361(9357):587-94.
11. Sablé-Fourtassou R, Cohen P, Mahr A, Pagnoux C, Mouthon L, Jayne D, et al. Antineutrophil cytoplasmic antibodies and the Churg-Strauss syndrome. *Ann Intern Med* 2005;143(9):632-8.
12. Vlahodimitris I, Kyrtsos MC, Lionakis N, Votizas V, Moyssakis I. Transient left ventricular dysfunction in Churg Strauss syndrome: a case report. *Cases J* 2009;2:6564.