

# Absence of Human Papillomavirus Antigens in Cutaneous Soft Fibromas

## DERİNİN YUMUŞAK FİBROMLARINDA İNSAN PAPİLLOMA VİRÜSÜ ANTİJENLERİNİN NEGATİFLİĞİ

Mukadder KOÇAK\*, Emel ERKEK\*, Önder BOZDOĞAN\*\*, Ahu BİROL\*, Pınar ATASOY\*\*

\* Yrd.Doç.Dr., Dept. of Dermatology, Medical School of Kırıkkale University,

\*\* Yrd.Doç.Dr., Dept. of Pathology, Medical School of Kırıkkale University, Kırıkkale, TURKEY

### Summary

**Background:** The cause of skin tags is unknown, although aging, obesity, diabetes mellitus, pregnancy, menopause, acromegaly and genetic susceptibility have been implicated as potential etiological factors. Recently a role for human papillomaviruses have been postulated in the development of these lesions.

**Objective:** The aim of the present study was to elucidate a role for human papillomaviruses in the etiopathogenesis of skin tags. In addition, the association of skin tags with diabetes mellitus and obesity has been questioned.

**Methods:** For this purpose lesional biopsy samples from 37 patients with skin tags were studied by immunohistochemical method for the expression of HPV antigens. As laboratory evaluation, fasting and postprandial serum glucose and fecal occult blood test were routinely performed for each patient.

**Results:** Immunohistochemical examination showed that all but one (2.7 %) of the 37 lesional biopsy specimens lacked HPV antigens. Thirteen patients (35.1 %) had a body mass index greater than 30 (obese). Fasting and/ or postprandial serum glucose values were abnormal in 14 patients (37.8 %).

**Conclusion:** These findings indicate that routine evaluation of carbohydrate metabolism may be important in patients presenting with multiple skin tags and that HPV can be excluded from the list of potential etiological factors in these lesions.

**Key Words:** Soft fibroma, Skin tags, Diabetes mellitus, Obesity, Human papillomavirus

T Klin J Dermatol 2003, 13:86-90

### Özet

**Giriş:** Derinin yumuşak fibromlarının gerçek nedeni bilinmemekle birlikte deri yaşlanması, şişmanlık, diyabet, gebelik, menopoz, akromegali ve genetik yatkınlık ile ilişkili olabilecekleri ileri sürülmektedir. Son zamanlarda insan papilloma virüsleri de yumuşak fibrom oluşumunda potansiyel etyolojik faktör olarak suçlanmışlardır.

**Amaç:** Bu çalışmada yumuşak fibrom etyopatogenezinde insan papilloma virüslerinin rolünün araştırılması amaçlanmış ve bu lezyonların diyabet ve obezite ile ilişkileri de sorgulanmıştır.

**Hastalar ve Yöntem:** Bu amaçla 37 hastanın lezyonel deri örneklerinde immünohistokimyasal metod ile HPV antijenleri çalışılmıştır. Her hastadan açlık ve tokluk kan şekeri ve gayitada gizli kan tetkikleri rutin olarak istenmiştir.

**Bulgular:** Lezyonel deri biyopsilerinden yalnızca birinde (2.7 %) HPV antijen varlığı saptanmıştır. On-üç hastanın (35.1 %) vücut kütle indeksi 30'un üstünde hesaplanmıştır. Açlık ve/ veya tokluk kan şekeri 14 hastada (37.8 %) yüksek bulunmuştur.

**Sonuç:** Bu bulgular çok sayıda yumuşak fibrom ile başvuran hastalarda karbonhidrat metabolizmasının değerlendirilmesi gerektiğine işaret etmekte ve insan papilloma virüslerinin bu lezyonların etyolojisinde rolü olmadığını düşündürmektedir.

**Anahtar Kelimeler:** Yumuşak fibrom, Diyabet, Obezite; İnsan papilloma virüsü

T Klin Dermatoloji 2003, 13:86-90

Skin tags (soft fibromas= acrochordons) are benign connective tissue tumours of the dermis that present as soft, skin-coloured to brown, pedunculated or occasionally filiform protrusions (1-4). The lesions usually occur on the flexuras of middle aged and elderly patients (1,3). Aside from

their unsightly appearance, the lesions are harmless and usually do not cause any discomfort (1,5). Histologically, they reveal a papillomatous acanthotic or a thin epidermis overlying a loose fibrous tissue similar to that of the papillary dermis (4,6,7). Skin tags do not contain cutaneous nerves. The

lack of innervation aids in their painless removal by simple scissor excision through the stalk (8).

The cause of skin tags is unknown, although aging, obesity, diabetes mellitus, pregnancy, menopause, acromegaly and genetic susceptibility have been implicated as potential etiological factors (1-5,9-13). Multiple skin tags have been proposed to serve as cutaneous markers for identifying patients at increased risk of having noninsulin-dependent diabetes mellitus (1,3,14). It has also been suggested that eruptive skin tags represent a cutaneous sign of asymptomatic colonic polyps and/ or colon carcinomas (10,11,15).

Human papillomaviruses (HPVs) are small double-stranded, intranuclearly replicating DNA viruses with a pronounced tropism for stratified epithelium (16-20). There are at least 80 isolated different types, which can be divided into those infecting cutaneous surfaces and those infecting mucosal surfaces (16,20). While most HPVs cause benign proliferative lesions, there is a subset of 'high-risk' HPVs which cause premalignant or malignant lesions of the mucosal and cutaneous epithelium (16-18,20,21). Recently it has been suggested that HPVs are etiologically involved in the development of skin tags (22).

The present study was designed to question a possible role for HPVs in the etiopathogenesis of skin tags. For this purpose lesional biopsy samples from skin tags were studied by immunohistochemical method for the expression of HPV antigens. In addition we aimed at evaluating the associated disorders, such as diabetes mellitus and obesity, previously implicated to have causal roles in the development of these lesions.

## **Patients and Methods**

### ***Selection of Patients***

This study was designed as a prospective investigation comprising 37 consecutive patients with skin tags diagnosed at the Dermatology Department of Kırıkkale University Faculty of Medicine between June 2000 and January 2001. Except for the presence of coexistent HPV-associated mucocutaneous lesions (warts and condylomas) on physical examination, there was no other exclusion

criterion. The patients were questioned for history of diabetes, presence of gastrointestinal symptoms, family history of colonic polyps and/ or carcinoma. For each patient, the number, site and color of skin tags and whenever present, the associated cutaneous disorders were recorded. A laboratory evaluation consisting of fasting and postprandial serum glucose and fecal occult blood testing was routinely ordered. Body mass index (BMI) of each patient was calculated as weight/ height<sup>2</sup>.

Skin tags were diagnosed by typical clinical features and histology. The biopsy samples were obtained by scissor excision of the largest lesion from the neck or axillae. To avoid HPV contamination and hence false positive results, lesions from the inguinal region were not sampled. Biopsy specimens were fixed in 10 % formalin and embedded in paraffin.

### ***Immunohistochemical Analysis***

Five micron-thick sections were obtained by microtome and transferred into adhesive slides. The sections were kept in the autoclave at 37°C for 16 hours and at 60°C for 20 minutes. Then they were deparaffinized and dehydrated by immersion into xylene twice for ten minutes and into alcohol twice for two minutes. Then, the specimens were incubated in 3% H<sub>2</sub>O<sub>2</sub> for five minutes to inhibit activation of endogenous peroxidases. All preparations were transferred into citrate buffer (pH: 6.6) and kept in the microwave oven (750 watt) twice for five minutes. By using Shandon Sequenza<sup>™</sup> manual staining device for standardization, the preparations were incubated for 90 minutes in HPV antibodies (polyclonal; prediluted; DAKO; Denmark). Classical avidin-biotin-peroxidase method and AEC chromogen (3-amino-9-ethylcarbasole) were applied for immunohistochemical demonstration of HPV antigens. Biopsy samples from palmoplantar warts served as positive control samples for HPV antigens. A negative control was performed in all of our cases by omitting the primary antibody for HPV, which in all instances resulted in negative immunoreactivity.

Mayer's hematoxylin was used as counterstain and slides were examined by light microscopy. An

intranuclear red pattern of staining was considered as positive HPV immunoreactivity.

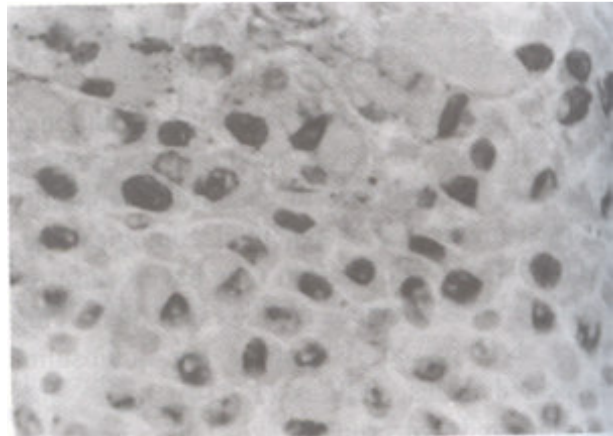
### Results

The patients with skin tags comprised 13 males and 24 females. The age range was 15-77 years (mean: 50.27; median: 49.00). None of the patients had medical or family history of colon polyps and/ or carcinoma. Twelve patients (32.4 %) had history of previously diagnosed diabetes mellitus.

On physical examination, the skin tags were confined to skin areas exposed to friction. The neck (n=36), axillae (n=3), groin (n=2) and abdominal wall (n=2) were involved in decreasing frequency with solitary (n=1) or multiple (n=36) flesh colored (n=18) to hyperpigmented (n=19) polypoid lesions. The number of skin tags varied in each patient, ranging from solitary to profuse crops of lesions over 500 in number (mean: 36.6; median: 15.0). The BMI of patients ranged from 17.8 to 41.8 (mean: 28.98; median: 28.8). Three (8.1 %) of the 37 patients had a BMI lower than 25 (normal weight), 21 patients (56.8 %) had a BMI between 25 and 29.9 (overweight) and 13 patients (35.1 %) had a BMI greater than 30 (obese).

Fasting and/ or postprandial serum glucose values were abnormal in 14 patients (37.8 %); 12 had a history of manifest diabetes mellitus; whereas 2 patients had their initial diagnoses during this study by serial testing for fasting and postprandial serum glucose values. None of the patients had positive occult blood in fecal specimens. Twenty-five patients had associated other cutaneous disorders, namely pruritus (n=11), xerosis (n=7), vitiligo (n=3), syringoma (n=1), seborrheic keratosis (n=1), urticaria (n=1) and xanthesma (n=1).

Immunohistochemical examination showed that only one (2.7 %) of the 37 lesional biopsy specimens expressed HPV antigens, as diffuse intranuclear staining in the upper epidermis. Internal positive controls (palmoplantar wart samples) consistently demonstrated strong expression of HPV antigens (Figure 1).



**Figure 1.** Strong nuclear HPV positivity in verruca plantaris, used as a positive internal control in the present study (IHC for HPV X 400).

### Discussion

Skin tags have been consistently associated with diabetes mellitus (4,9). Multiple skin tags have been proposed to serve as cutaneous markers for identifying patients having noninsulin-dependent diabetes mellitus (1,3,14). According to previous studies, 26.3-62.8 % of patients with skin tags have associated overt diabetes (1,3,13). In the present study, the prevalence of diabetes was 37.8 %, a figure reflecting the necessity of serum glucose evaluation in patients presenting with multiple skin tags. It has been suggested that skin tags are more directly a marker of raised fasting circulating insulin levels rather than fasting glucose levels, implying a relation with insulin resistance (14). Hypothetically, the fibroblast proliferation in skin tags have been related to the activation of insulin-like growth factor-1 receptors on fibroblast cell surface by hyperinsulinemia (4,14).

The number of skin tags has been reported to increase with weight (11). According to previous data, 28.7 % of affected patients with skin tags are obese (3,9,13). In our study, obesity prevalence was 35.1 %. This figure increased to 91.9 % when overweight patients were included. Obesity is another factor known to cause insulin resistance at receptor levels and high circulating insulin levels (4,14). The development of skin tags in obese patients has also been linked to insulin-mediated epidermal hyperproliferation (14).

Skin tags have been initially reported to be highly sensitive and predictive marker for adenomatous and hyperplastic colonic polyps and colon carcinomas (10). However, subsequent studies on larger patient groups have demonstrated that skin tags were not very specific and did not constitute a risk factor for polyposis coli or colon neoplasms in asymptomatic patients from general population (10,23,24). In the present study there was no patient with a family history of colon disorders or positive fecal occult blood test. Skin tags are no longer used as a marker for earlier and more intensive gastrointestinal screening than is currently recommended for the general population (23). For patients with skin tags and abdominal symptoms, annual fecal occult blood testing and flexible rectosigmoidoscopy are recommended; followed by colonoscopy if family history is positive for polyposis or malignancy (24).

The report by Dianzani et al (22) in 1998 on the presence of HPVs in skin tags has aroused enthusiasm and surprise, considering the lack of a documented interhuman transmission for skin tags. The authors detected HPV-6 and -11 DNA in 88 % of 49 soft fibromas sequentially analysed by dot blot hybridization and polymerase chain reaction (PCR) and suggested that HPV might play a potential etiopathogenetic role in the development of skin tags. However, as our knowledge, there is no subsequent study confirming this association. Akar et al (5) studied 34 soft fibroma biopsy samples by PCR for the presence of HPV by using primers capable of detecting all subtypes of the virus. They also performed type-specific PCR for HPV-6, -11, -16, -18 and obtained no positive signals. The authors concluded that HPV is not etiologically involved in skin tags. In the present study, HPV antigens were absent in 97.3 % of samples by immunohistochemical analysis. These findings cast a shadow on the primary contributory role of HPVs in the development of skin tags and raise the question of false positivity for the results obtained by Dianzani et al (22). With the advent of PCR technology, HPV DNA can now be detected even within biopsy specimens that appear normal on gross and microscopic examination; this is referred

to as latent infection (20). While the mere presence of HPV within lesional skin can not be considered as proof for an etiological role, the absence of virus in the vast majority of biopsy specimens may render the virus as innocent bystander.

In conclusion, the results of the present study suggest that patients with multiple skin tags should be evaluated for a possible derangement in carbohydrate metabolism and that HPVs might be excluded from the list of potential etiological factors.

## REFERENCES

1. Thappa DM. Skin tags as markers of diabetes mellitus: an epidemiological study in India. *J Dermatol* 1995; 22: 729-31.
2. Banik R, Lubach D. Skin tags: localization and frequencies according to sex and age. *Dermatologica* 1987; 174: 180-3.
3. Kahana M, Grossman E, Feinstein A, Ronnen M, Cohen M, Millet MS. Skin tags: a cutaneous marker for diabetes mellitus. *Acta Derm Venereol* 1987; 67: 175-7.
4. Mathur SK, Bhargava P. Insulin resistance and skin tags. *Dermatology* 1997; 195: 184.
5. Akar A, Taştan HB, Kubar A, Erbil H, Gür AR. Is there any etiological role of human papillomavirus in cutaneous soft fibromas? *T Klin J Dermatol* 2000; 10: 169-70.
6. Mesenchymal and neural tumors: Acrochordon. In: Braun-Falco O; Plewig G, Wolff HH, Burgdorf WHC, eds. *Dermatology*, 2nd ed. Berlin: Springer-Verlag, 1996: 1556-7.
7. MacKie RM. Epidermal skin tumours: Skin tags. In: Champion RH, Burton JL, Burns DA, Breathnach SM, eds. *Textbook of dermatology*, 6 th ed. Oxford: Blackwell Scientific Publ, 1998: 1661.
8. Pennys NS. Skin tags do not contain cutaneous nerves. *Arch Dermatol* 1990; 126: 1654-5.
9. Levine N. Brown patches, skin tags on axilla. Are this patient's velvety plaques related to his obesity and diabetes? *Geriatrics* 1996; 51: 27.
10. Graffeo M, Cesari P, Buffoli F, Mazzola A, Salmi A, Paterlini A. Skin tags: markers for colonic polyps? *J Am Acad Dermatol* 1989; 21: 1029-30.
11. Ochsendorf FR, Leopolder-Ochsendorf A, Holtermüller K-H, Milbradt R. Weiche Hautfibrome: Untersuchung ihrer Einflußgrößen und ihrer diagnostischen Bedeutung für Kolonneoplasien. *Hautarzt* 1990; 41: 207-11.
12. Graham-Brown RAC. The ages of man and their dermatoses: Skin tags. In: Champion RH, Burton JL, Burns DA, Breathnach SM, eds. *Textbook of dermatology*, 6 th ed. Oxford: Blackwell Scientific Publ, 1998: 3273.
13. Weismann K. Skin disorders and diabetes mellitus. In: Champion RH, Burton JL, Burns DA, Breathnach SM, eds. *Textbook of dermatology*. 6th ed. Oxford: Blackwell Scientific Publ, 1998: 2673-7.

14. Norris PG, McFadden J, Gale E, Griffiths WAD. Skin tags are more closely related to fasting insulin than fasting glucose levels. *Acta Derm Venereol* 1988; 68: 367-8.
15. Rodriguez-Serna M, Martinez A, Perez A, Medina E, Aliaga A. Eruptive skin tags and keratoacanthomas in a patient with prolactinoma and colonic polyposis. *Dermatology* 1994; 189: 215-6.
16. McMurray HR, Nguyen D, Westbrook TF, McAnce DJ. Biology of human papillomaviruses. *Int J Exp Pathol* 2001; 82: 15-33.
17. Basile Jr, Zacny V, Münger K. The cytokines tumor necrosis factor- $\alpha$  (TNF- $\alpha$ ) and TNF-related apoptosis-inducing ligand differentially modulate proliferation and apoptotic pathways in human keratinocytes expressing the human papillomavirus-16 E7 oncoprotein. *J Biol Chem* 2001; 276: 22522-8.
18. Flores ER, Allen-Hoffmann BL, Lee D, Lambert PF. The human papillomavirus type 16 E7 oncogene is required for the productive stage of the viral life cycle. *J Virol* 2000; 74: 6622-31.
19. Sehgal VN, Koranne RV, Srivastava SB, Gupta MM, Luthra UK. Clinicopathology and immunohistochemistry of genital warts. *Int J Dermatol* 1988; 27: 690-4.
20. Nebesio CL, Mirowski GW, Chuang T-Y. Human papillomavirus: clinical significance and malignant potential. *Int J Dermatol* 2001; 40: 373-9.
21. Biliris KA, Koumantakis E, Dokianakis DN, Sourvinos G, Spandidos DA. Human papillomavirus infection in non-melanoma skin cancers in immunocompetent hosts. *Cancer Letters* 2000; 161: 83-8.
22. Dianzani C, Calvieri S, Pierangeli A, Imperi M, Bucci M, Degener AM. The detection of human papillomavirus DNA in skin tags. *Br J Dermatol* 1998; 138: 649-51.
23. Brendler SJ, Watson RD, Katon RM, Parsons ME, Howatt JL. Skin tags are not a risk factor for colorectal polyps. *J Clin Gastroenterol* 1989; 11: 299-302.
24. Chobanian SJ. Skin tags and colonic polyps-a gastroenterologist's perspective. *J Am Acad Dermatol* 1987; 16: 407-9.

---

**Geliş Tarihi:** 05.06.2002

**Yazışma Adresi:** Dr. Emel ERKEK  
Kırıkkale Üniversitesi Tıp Fakültesi  
Dermatoloji AD, KIRIKKALE  
emelerkek@hotmail.com