

# Evaluation of the Effect of Ultrasonic and Sonic Activation Systems on Root Canal Filling Quality in Resin Primary Molars: *In Vitro* Study

## Rezin Süt Molar Dişlerde Ultrasonik ve Sonik Aktivasyon Sistemlerinin Kök Kanal Dolgu Kalitesine Etkisinin Değerlendirilmesi: *In Vitro* Çalışma

<sup>ID</sup> Burcu GÜÇYETMEZ TOPAL<sup>a</sup>, <sup>ID</sup> Seda FALAKALOĞLU<sup>b</sup>, <sup>ID</sup> Esra Nur AKGÜL<sup>a</sup>, <sup>ID</sup> Ceren AKTUNA BELGİN<sup>c</sup>

<sup>a</sup>Afyonkarahisar University of Health Sciences Faculty of Dentistry, Department of Pediatric Dentistry, Afyonkarahisar, Türkiye

<sup>b</sup>İstanbul Health and Technology University Faculty of Dentistry, Department of Endodontics, İstanbul, Türkiye

<sup>c</sup>Hatay Mustafa Kemal University Faculty of Dentistry, Department of Oral and Maxillofacial Radiology, Hatay, Türkiye

**ABSTRACT Objective:** The aim of this study is to evaluate the effect of different filling methods on canal filling quality in resin primary molar teeth prepared with two different preparation techniques. **Material and Methods:** For the study, 60 maxillary primary second molar teeth obtained from resin block were used. Root canals were prepared using a manual #K-file (n=30) and a VDW Rotate™ System (n=30) rotary instrument. Each group was divided into 3 subgroups according to the filling technique used (n=10): Calci-Paste® syringe (control group); Calci-Paste® syringe and Uc-One® (ultrasonic activation); Calci-Paste® syringe and Eddy® (sonic activation). The quality of the canal filling (under filled, optimal filled, overfilled) and the presence/absence of voids were assessed using cone beam computed tomography. SPSS (Statistical Package for Social Science, IBM SPSS®, version 26, Chicago, USA) program was used for statistical analysis. **Results:** There was no significant difference between the different preparation and filling techniques in terms of filling volume and length. In the study, voids were detected in all three filling methods, but the highest void filling was found in the Calci-Paste® syringe +ultrasonic activation group (48%). The manual preparation and syringe group had the most optimally filled teeth but there was no significant difference between the groups (For preparation methods p=0.573; for filling methods p=0.976). **Conclusion:** In this study, it was found that sonic and ultrasonic systems did not improve the quality of root canal filling in resin primary molars and ultrasonic activation caused more voids.

**Keywords:** Primary teeth; root canal therapy; cone-beam computed tomography; root canal obturation

**ÖZET Amaç:** Bu çalışmanın amacı, iki farklı preparasyon tekniği ile hazırlanan rezin süt molar dişlerde farklı dolum yöntemlerinin kanal dolum kalitesi üzerine etkisini değerlendirmektir. **Gereç ve Yöntemler:** Çalışmada rezin bloktan elde edilmiş 60 adet maksiller süt 2. molar diş kullanıldı. Kök kanallarının preparasyonu manuel #K-tipi eğe (n=30) ve VDW Rotate™ System (n=30) döner alet kullanılarak yapıldı. Her grup kullanılan dolum tekniğine göre 3 alt gruba ayrıldı (n=10): Calci-Paste® enjektör (kontrol grubu); Calci-Paste® enjektör ve Uc-One® (ultrasonik aktivasyon); Calci-Paste® enjektör ve Eddy® (sonik aktivasyon). Kanal dolumunun kalitesi (eksik dolum, optimal dolum, taşkın dolum) ve boşluk varlığı/yokluğu konik ışınli bilgisayarlı tomografi kullanılarak değerlendirildi. İstatistiksel analiz için SPSS (Statistical Package for Social Science, IBM SPSS®, version 26, Chicago, ABD) programı kullanıldı. **Bulgular:** Farklı preparasyon ve dolum teknikleri arasında dolum hacmi ve uzunluğu açısından anlamlı bir fark bulunmamıştır (p>0,05). Bu çalışmada, her üç dolum yönteminde boşluk saptandı ancak en fazla boşluklu dolum Calci-Paste® enjektör+ultrasonik aktivasyon (%48) grubunda bulundu. Manuel preparasyon ve enjektör grubu en optimal doluma sahipti ancak gruplar arasında anlamlı bir fark bulunmadı (preparasyon yöntemleri için p=0,573; dolgu yöntemleri için p=0,976). **Sonuç:** Bu çalışmada, rezin süt molar dişlerde sonik ve ultrasonik sistemlerin kök kanal dolumunun kalitesini artırmadığı ve ultrasonik sistemlerin daha fazla boşluğa neden olduğu bulunmuştur.

**Anahtar Kelimeler:** Süt dişi; kök kanal tedavisi; konik ışınli bilgisayarlı tomografi; kök kanal obtürasyonu

**Correspondence:** Esra Nur AKGÜL

Afyonkarahisar University of Health Sciences Faculty of Dentistry, Department of Pediatric Dentistry, Afyonkarahisar, Türkiye  
E-mail: nurakgul1996@gmail.com



Peer review under responsibility of Türkiye Klinikleri Journal of Dental Sciences.

Received: 04 Oct 2023

Received in revised form: 21 Feb 2024

Accepted: 27 Feb 2024

Available online: 14 Mar 2024

2146-8966 / Copyright © 2024 by Türkiye Klinikleri. This is an open access article under the CC BY-NC-ND license (<http://creativecommons.org/licenses/by-nc-nd/4.0/>).

Pulpectomy, which preserves primary teeth until the physiological exfoliation process for function, appearance and speech, is a widely preferred treatment option in children.<sup>1</sup> Successful root canal treatment relies on thorough debridement, effective chemomechanical preparation, and three-dimensional (3D) hermetic seal without damaging the successor permanent tooth germ.<sup>2</sup> However, achieving complete pulpectomy is challenging due to the intricate root canal system of primary dentition. Narrow and ribbon-shaped canals, lateral branching or partial fusion of canals, sharp curvatures, deposition of secondary dentin, physiological resorption, and cooperation problems of children complicate successful root canal preparation and obturation.<sup>1,3,4</sup>

Manual or rotary instruments may be utilised for preparing root canals. Manual instrumentation using K-files is a commonly used technique in primary dentistry, however it has many restrictions, such as the inability to effectively clean root canals, step, perforation or zip formation, canal transport or instrument breakage.<sup>4,5</sup> Despite the limitations of manual instruments, rotary instruments have been recommended due to their efficiency, speed, and advantages of providing homogeneous filling.<sup>6,7</sup>

Obturation with optimum length and quality placed sealing is required for a successful endodontic treatment in primary teeth.<sup>7,8</sup> A root canal system that is sealed hermetically prevents microleakage between the root canal and the periapical tissues, inhibiting the growth of resilient microorganisms and the entrance of harmful bacterial substances into the periapical region.<sup>8</sup>

Numerous materials have been used to fill root canals in primary teeth, of which  $\text{Ca(OH)}_2$ /iodoform pastes are often preferred because of their antibacterial effect, healing properties and rapid resorption when overfilled.<sup>9,10</sup> They are used with their provided premixed syringe as recommended by the manufacturer, but various obturation techniques such as lentulo spiral, pressure syringe, endodontic irrigation needle and NaviTip™ system have been described to increase the filling quality.<sup>11-13</sup> In the limited number of studies, ultrasonic and sonic activation devices have also been tested as a primary root canal filling

technique, but the results are conflicting due to different methods.<sup>14-16</sup>

Today, 3D software in dentistry is gaining popularity in many areas.<sup>20</sup> Using cone beam computed tomography (CBCT) data from an extracted tooth, this method facilitates the acquisition of a human tooth model with the same morphology.<sup>17</sup> Physiological root resorption in primary teeth occurs shortly after root completion, making it difficult to maintain a standard in vitro study of endodontic treatments.<sup>18</sup> Therefore, resin teeth obtained from extracted teeth and prepared with 3D software provide an advantage in providing the standardization between samples in these studies.

The aim of this study was to evaluate the performance of three various obturation methods (ultrasonic activation+premixed syringe, sonic activation+premixed syringe and premixed syringe alone) on the quality of root canal filling of resin molar teeth which prepared with two different preparation techniques. The null hypothesis of the studies was, there is no difference among techniques according to percentage obturated volume (POV), filling quality of root canals and void formation.

## MATERIAL AND METHODS

This study was approved by the Ethics Committee of Afyonkarahisar Health Sciences University (date: September 2, 2022, no: 2022/11/454) in compliance with the Declaration of Helsinki.

### SAMPLE PREPARATION

For the study, freshly extracted non-carious one maxillary second human primary molar with fully formed apices was chosen. Following decoronation, a manual K file (#10 size, VDW, Munich, Germany) placed into canals until the can be seen in the apical foramen of the tooth. The working length (WL) was measured to be one millimeter shorter than the apex. Radiographic images of molar were taken by CBCT (GXDP-700; Gendex Dental Systems), with settings of 60 kVp and 7 mA. The “Tooth Segmentation” option in RealGUIDE 5.0 software (3diemme Software Corp) was used to segment the CBCT data and create a 3D model. Subsequently, the obtained CBCT scan

data were turned into .stl files, enabling their utilization with the 3D printer (Ackuretta FreeShape 120, Ackuretta Technologies). A mixture of resin (KeyVest, Keystone Ind.) with barium sulphate (12.5%) was prepared to achieve radiopacity. The WL was established 1 mm shorter than that point. Then, the root canals were manually prepared with hand files up to size 20, rinsed with distilled water and dried with paper points.

Sixty 3D-printed maxillary second primary molars were randomly assigned to two groups of thirty teeth each, based on the root canal shaping method. Each group was divided into 3 subgroups, with each subgroup having 10 teeth, based on the preferred obturation technique. The distribution of primary molars is shown in the flow chart (Figure 1).

### ROOT CANAL PREPARATION

3D printed resin teeth were placed in polyvinyl siloxane impression material (Express™ XT Putty Quick, 3M ESPE Germany) for stabilization during the root canal instrumentation process. The apical foramina were blocked with modelling wax. A single experienced paediatric dentist performed all instrumentation. A 30-gauge TruNatomy (Dentsply Sirona) irrigation needle was used with a total irrigation volume of 20 milliliters of distilled water. Between the preparation with each file in all groups, the needle

was inserted up to two millimeters short of the WL.

- Manual K-file group: The root canals were prepared with K files (VDW) using a step-back method. The canals were prepared with a #25 Master Apical File. This was followed by a step-back to #40.

- VDW ROTATE™ group: Root canals were prepared using VDW. Rotate™ 20.05 and 25.06 up to WL. The instruments were operated at a torque of 2 N.cm and a speed of 300 rpm.

### ROOT CANAL FILLING

The root canals were obturated using various obturation techniques with Calci-Paste® (Pyrax Polimars, Uttarakhand, INDIA), a commercially available calcium hydroxide-iodoform paste (Figure 2).

- Calci-Paste® syringe (control group): The prepared canals were filled with canal sealer using a Calci-Paste® syringe. The procedure was repeated at least twice until backfilling was observed in the canal mouth.

- Calci-Paste® syringe +Uc-One® ultrasonic activation group: The prepared canals were filled using a Calci-Paste syringe and indirect ultrasonic activation. The paste was injected by placing the Calci-Paste syringe into the canal. During the injection, an ultrasonic tip (Uc-One®, Epdent, Korea) will be placed in contact with the Calci-Paste® syringe. The

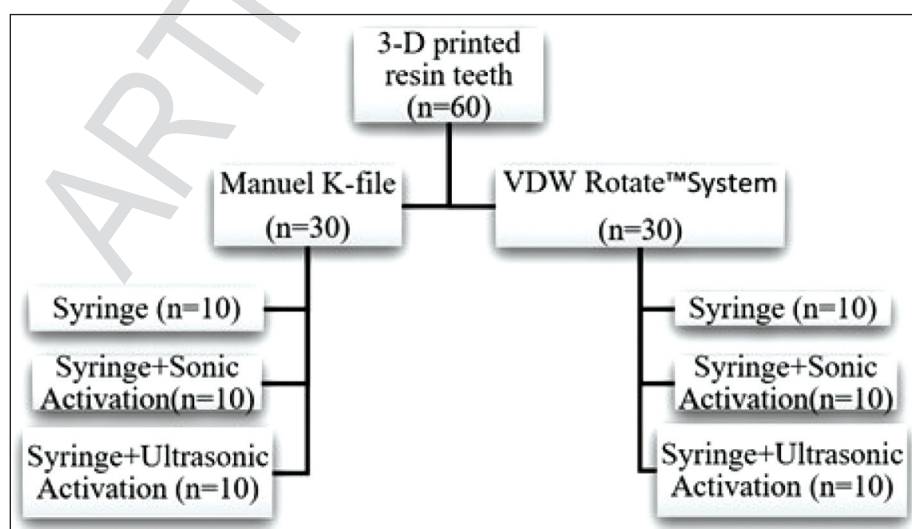
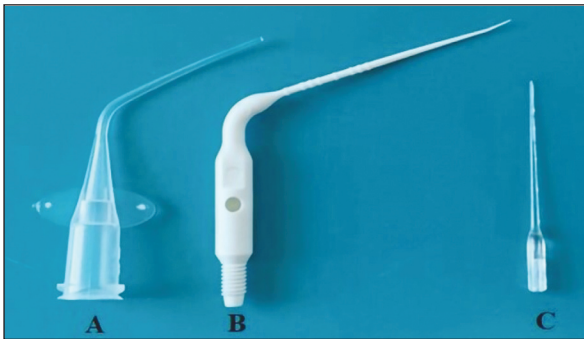


FIGURE 1: Flow chart.



**FIGURE 2:** Obturation Methods A) Calci-Paste® syringe tip, B) EDDY® tip, C) Uc-One® tip.

procedure was repeated at least twice until backfilling was observed in the canal mouth.

■ **Calci-Paste® syringe +Eddy® sonic activation group:** The prepared channels were filled using a Calci-Paste syringe and sonic activation. The paste was injected by placing the Calci-Paste® syringe into the canal. The air-scaler was adjusted to a frequency of 6000 Hz and plastic tips of Eddy® (TA-200-S4H, MICRON Co., Tokyo, Japan) was placed 2 millimeters shorter than the WL. The procedure was repeated at least twice until backfilling was observed in the canal mouth. For all groups, assuming the canal was completely filled, a rubber stopper 1 mm shorter than the WL was placed around the filling tool and a moist pellet of cotton was used to gently press the material into the canal (Figure 3).

#### RADIOGRAPHIC EVALUATION

All scans were acquired using same CBCT (KaVO 3D Op Pro, Biberach, Germany) and scanning procedure (90 kV, 5.0 mA, 4.07s, 8x15 centimeters field

of view, 380µm voxel size, 0.38 millimeters slice thickness). The length and quality of the canal filling were assessed.

#### VOLUMETRIC MEASUREMENTS

Volumetric measurements of the pulp was conducted through manual segmentation, utilizing the ITK-SNAP v. 3.8.0 software (Cognitica, Philadelphia, PA, USA, opensource software, [www.itksnap.org](http://www.itksnap.org)).<sup>23</sup> The CBCT scans were transferred to the software in the DICOM format. Firstly, the polygon selection tool and the “active label” were selected, which allows to manually mark the boundaries of the area to be segmented. The examiner established a threshold range (-200 to -50 for the lower threshold and 400 to 700 for the upper threshold) to determine the start and end of the segmentation procedure. Consequently, all pixels within this area were selected to construct the 3D pulp image. Pulp boundaries were marked on each axial section and accuracy was checked on sagittal and coronal sections. After the pulp boundaries were determined, “interpolate along a single axis” was marked and the missing points were automatically included in the boundaries by the program. The accuracy of the marked areas in all three sections was checked and the volume calculation in mm<sup>3</sup> was automatically done by the program. For this study, we evaluated CBCT images using maximum intensity projection with a thickness of 2.7 mm. One dentomaxillofacial radiologist with seven years of experience in CBCT image evaluation and segmentation performed all volumetric measurements. The radiologist had no prior knowledge of the patient’s clinical



**FIGURE 3:** 3D-printed resin teeth samples for root canal obturation.

data. The analysis was conducted on a laptop (Dell 14-in. liquid-crystal display monitor with 1.366×768 pixels; Dell, Round Rock, TX, USA), in a dimly lit and quiet room. Image contrast, brightness, and zoom were adjustable while pulp contouring and volume measurement were performed.

The data from these scans were used to calculate the post-obtured volume of the root canal for each of the filling materials in each sample (Figure 4). The following formula was used to calculate the POV for each canal:

$$\text{POV} = \frac{\text{Post-obtured root canal volume (Y)}}{\text{Pre-obtured root canal volume (X)}} \times 100 = (Y/X) \times 100.$$

The radiographic quality of the obturation was assessed by evaluating the length of the obturation and the presence or absence of voids.

The quality of obturation was assessed as:<sup>20</sup>

- Under filled- All canals were filled >2 millimeters short of the apex.
- Optimal filled- One or more of canals with filling paste that ends at the apex or up to <2 millimeters short of the apex.
- Over filled- Any canal with extruded filling paste beyond the apex.

## STATISTICAL ANALYSIS

The SPSS package program (Statistical Package for Social Science, IBM SPSS®, version 26, Chicago, USA) was used for the statistical analysis. Two-way analysis of variance test was performed to examine the effects of preparation method and filling methods on the POV. Homogeneity of variances was evaluated by Levene's test. Mann-Whitney U test was used to comparing the methods. Chi-square test was used for the analysis of the quality of filling.  $p < 0.05$  was set as statistically significant for all statistical tests.

## RESULTS

The total mean filling percentage of the root canals in the study was  $87.17 \pm 5.46$  (Table 1). The effects of the preparation methods ( $p = 0.071$ ) or filling methods ( $p = 0.731$ ) alone and their interaction (preparation method x filling method,  $p = 0.917$ ) on the filling percentage were not found as statistically significant (Table 2).

Voids were detected in all three filling method groups, the distribution of voids according to filling methods is shown in the Table 3. There were no voids in 58.3% ( $n = 35$ ) of the resin teeth included in the

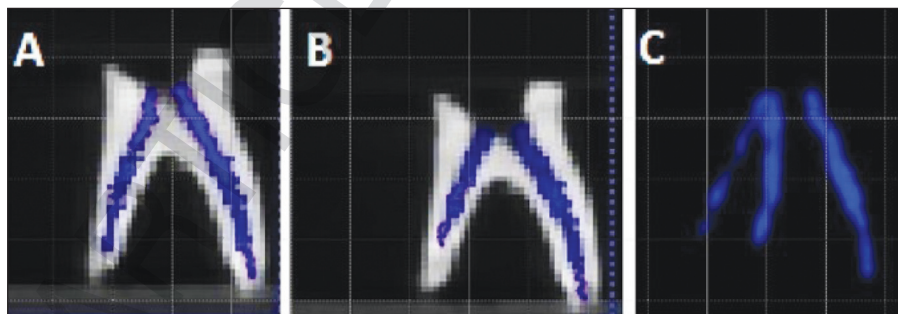


FIGURE 4: Cone-beam computed tomography image of volumetric filling in vertical plane.

TABLE 1: Comparison of the mean POV of groups.

		Preparation method		
		Manual	Rotary	Total
Filling methods	Syringe	84.84±5.20	88.16±4.42	86.50±4.99
	Syringe+sonic activation	85.55±8.75	89.20±4.54	87.88±6.92
	Syringe+ultrasonic activation	86.19±5.44	88.07±2.84	87.13±4.33
	Total	85.86±6.47	88.47±3.90	87.17±5.46

POV: Percentage obtured volume.

**TABLE 2:** The effects of preparation and filling methods on the POV.

Parameters	Sum of squares	df	Mean square	F	p value
Preparation methods	102.6	1	102.6	3.39	0.071
Filling methods	19.1	2	9.54	0.32	0.731
Preparation*filling	5.25	2	2.62	0.09	0.917

R squared: 0.072; POV: Percentage obturated volume; df: Degree of freedom.

**TABLE 3:** Distribution of voids of filling by preparation and obturation method.

		No void	With void	p value
Preparation method	Manuel	60% (21)	36% (9)	0.115
	Rotary instrument	40% (14)	64% (16)	
Filling method	Syringe	40% (14) <sup>a</sup>	24% (6) <sup>a</sup>	0.048
	Syringe+sonic activation	37.1% (13) <sup>a</sup>	28% (7) <sup>a</sup>	
	Syringe+ultrasonic activation	22.9% (8) <sup>a</sup>	48% (12) <sup>b</sup>	

Each subscript letter denotes a subset of void categories whose column proportions do not differ significantly from each other at the 0.05 level.

**TABLE 4:** Comparison of quality of obturation between the different root canal preparation methods.

		Underfilled % (n)	Optimally filled % (n)	Overfilled % (n)	p value
Preparation method	Manual	44.4 (12)	58.3 (14)	44.4 (4)	0.573
	Rotary instrument	55.6 (15)	41.7 (10)	55.6 (5)	

**TABLE 5:** Comparison of quality of obturation between the different obturation methods.

		Underfilled % (n)	Optimally Filled % (n)	Overfilled % (n)	p value
Filling method	Syringe	29.6 (8)	37.5 (9)	33.3 (3)	0.976
	Syringe+sonic activation	37 (10)	29.2 (7)	33.3 (3)	
	Syringe+ultrasonic activation	33.3 (9)	33.3 (8)	33.3 (3)	

study; however, voids were observed in 41.7% (n=25). Voids were more commonly found in the syringe+ultrasonic activation group (48%).

Table 4 shows the quality of obturation in each group, 45% (n=27) of the teeth were underfilled, 40% (n=24) were optimally filled and 15% (n=9) were overfilled. The manual preparation and syringe group had the most optimally filled teeth but there was no significant difference between the groups (for preparation methods p=0.573; for filling methods p=0.976) (Table 5).

## DISCUSSION

Root canal treatment in primary teeth presents some unique challenges compared to permanent teeth due to anatomical and developmental differences. For this

reason, filling of primary root canals has been carefully considered and many methods have been evaluated to increase the quality of root canal filling in the previous studies.<sup>21,22</sup> However, it was seen that a consensus could not be reached in the previous studies. We assessed the success of sonic and ultrasonic activation on the root canal filling of resin teeth. It was found that there was no difference between the methods in terms of POV and filling quality, but there was a significant difference between three methods with regard to void formation.

Today, it is feasible to assess the effectiveness of various instrumentation and treatment methods by producing standardized resin-based models with 3D printing technology using CBCT in conjunction with evolving technology.<sup>8</sup> Laboratory studies on extracted human teeth may be a more accurate reflection

tion of clinical conditions, but it is difficult to find a sufficient number of standardised primary teeth with the similar canal morphology.<sup>23</sup> To overcome these difficulties, resin teeth were obtained from the CBCT image of extracted primary human teeth. To the best of authors' knowledge, this is the first study which evaluated the filling quality of root canals in resin primary teeth.

In the study, assessment of various filling techniques in resin primary teeth was done with CBCT which is a non-invasive procedure which provides a 3-dimensional image of the morphological characteristic. While micro or spiral computed tomography (CT) has been used for volumetric measurement of obturation materials, CBCT has several advantages over spiral CT. These include lower effective radiation dose, lower cost, smaller volume, faster and easier image acquisition, and interactive display modes such as multiplanar reconstruction.<sup>28-31</sup> Because of the advantages of CBCT, we evaluated the quality of root canal filling of resin teeth with CBCT. But one of the limitations of the present study is that smaller voids cannot be detected by CBCT effectively.<sup>21</sup>

In the accessible literature, the studies evaluated the filling quality of root canals in primary teeth is limited and the results are conflicting. In previous studies, some authors have reported improved seal quality with rotary files in primary teeth, while Govindaraju et al. and Preethy et al. found the obturation quality of manual and rotary files to be similar, as in our study.<sup>27-30</sup> The similar results of preparation methods may be explained with the studies which reported that the rotary instruments with a greater than 4% taper have been shown to be more efficient than manual files in preparing root canals.<sup>31</sup> The contradictory results could be attributed to the differences of the materials and methods of the studies, such as types of teeth, files, and obturation materials.

Recently, it was suggested that the ultrasonic activation may be applied to root canal filling materials to adapt them to the root canals in permanent teeth.<sup>32-34</sup> The usage of ultrasonic activation during endodontic treatments of primary teeth are very limited in accessible literature. In the study of Özer et al., authors evaluated the groups with digital radiography,

and they found that ultrasonic group showed similar acceptable score to the proprietary syringe alone for the length and the quality of primary teeth root canal fillings.<sup>14</sup> In another study Ozturk et al. evaluated the quality of filling with micro-CT and their findings were that ultrasonic activation did not increase the efficiency of root canal obturation in primary teeth.<sup>16</sup> Ultrasonic activation did not improve root canal obturation quality in primary teeth, as found in studies by Özer et al., and Ozturk et al.<sup>14,16</sup> The result can be related to the canal morphology of the primary teeth. The thin root canals of primary teeth may not have enough volume to show the effect of ultrasonic activation.<sup>16</sup> In addition, another reason may be that the filling material could not pass into the lateral and accessory canals due to use of resin teeth in the study.

The sonic and ultrasonic activation were compared in primary teeth obturation only in one study.<sup>14</sup> The authors used a different sonic activator system (Endoactivator®) with Metapex® syringe and they found that the ultrasonic and sonic activators showed similar acceptable scores to the Metapex® syringe alone for the quality of primary tooth root canal fillings.<sup>14</sup> In the current study, we evaluated the effect of sonic activation on the quality of root canal filling of resin teeth using a sonic activated irrigation system made from elastic polyamide with a size of 25.04. Similar to previous study, the differences between mean filling percentages of root canals and quality of root fillings in sonic and ultrasonic groups were not found statistically significant. The polymer tip of the ultrasonic activator operates at higher frequencies (25-30 kHz) compared to EDDY (6 kHz), although its effects on canal filling success were found to be similar. The similar results of the two systems can be attributed to the fact that they were examined on resin teeth, not on human teeth with accessory canals.

One of the most significant factors in the quality of a root canal filling is the presence of voids. Particularly large voids can cause leaks that allow bacterial growth and may require retreatment. Although many techniques with lentulospiral, NaviTip™ system, insulin, anesthetic or tuberculin syringe have been tried to prevent voids, authors emphasized that it is very difficult to completely eliminate them.<sup>12,21,22</sup> In the

present study, 41.7% of the resin teeth have voids. In previous studies, Ca (OH)<sub>2</sub>/iodoform pastes were used with different obturation techniques, but the authors stated that the most successful results were obtained in terms of void formation, similar to our study, when used with its proprietary syringe.<sup>11,12,35</sup>

In the present study, the voids were detected in all three obturation methods, but they were more commonly found in the syringe+ultrasonic activation group (48%). In a study, ultrasonic activation group was the second group with the most void after the endodontic irrigation needles. The authors noted that there were no significant differences in void amounts or locations between the control group and the other groups.<sup>14</sup> In another study, the void volume percentage of the ultrasonic activation+lentulo group was found to be similar to lentulo alone and the previous injection technique.<sup>16</sup> On the contrary, one study on permanent teeth found statistically less voids in the ultrasonic activation group than in the lentulo spiral group.<sup>15</sup> The different results might be attributed to differences in the type of the obturation material, the technique used for preparation, the type of teeth, the type of radiographies and differences in the skills of operators.<sup>12,21</sup>

Our study has some limitations due to the fact that it was performed on resin teeth. To ensure standardization in studies conducted on primary teeth, 3D printed resin replicas were used. However, it is known that the accessory and lateral canals cannot be imitated in resin teeth, and the differences in dentin hardness, moisture and radiopacity do not exactly mimic human teeth.<sup>36,37</sup> Additionally, in future studies it may be possible to obtain more accurate models by using micro-CT.

## CONCLUSION

The present study showed no significant differences between the different preparation and obturation techniques considering the POV and length of root canal obturation. Otherwise, void formation was more commonly found in the syringe+ultrasonic activation group. To save time in treating pediatric patients, it is best to use the proprietary syringe with calcium hydroxide-iodoform paste, according to the authors.

### Source of Finance

*During this study, no financial or spiritual support was received neither from any pharmaceutical company that has a direct connection with the research subject, nor from a company that provides or produces medical instruments and materials which may negatively affect the evaluation process of this study.*

### Conflict of Interest

*No conflicts of interest between the authors and / or family members of the scientific and medical committee members or members of the potential conflicts of interest, counseling, expertise, working conditions, share holding and similar situations in any firm.*

### Authorship Contributions

**Idea/Concept:** Burcu Güçyetmez Topal, Seda Falakaloğlu; **Design:** Burcu Güçyetmez Topal, Seda Falakaloğlu, Ceren Aktuna Belgin; **Control/Supervision:** Burcu Güçyetmez Topal; **Data Collection and/or Processing:** Burcu Güçyetmez Topal, Seda Falakaloğlu, Ceren Aktuna Belgin; **Analysis and/or Interpretation:** Burcu Güçyetmez Topal, Seda Falakaloğlu; **Literature Review:** Burcu Güçyetmez Topal, Esra Nur Akgül; **Writing the Article:** Burcu Güçyetmez Topal, Esra Nur Akgül; **Critical Review:** Seda Falakaloğlu; **References and Fundings:** Burcu Güçyetmez Topal, Esra Nur Akgül; **Materials:** Burcu Güçyetmez Topal, Seda Falakaloğlu, Esra Nur Akgül.

## REFERENCES

1. Fuks AB, Guelmann M, Kupietzky A. Current developments in pulp therapy for primary teeth. *Endod Topics*. 2012;23(1):50-72. [https://www.academia.edu/77608324/Current\\_developments\\_in\\_pulp\\_therapy\\_for\\_primary\\_teeth](https://www.academia.edu/77608324/Current_developments_in_pulp_therapy_for_primary_teeth)
2. Kojima K, Inamoto K, Nagamatsu K, Hara A, Nakata K, Morita I, et al. Success rate of endodontic treatment of teeth with vital and nonvital pulps. A meta-analysis. *Oral Surg Oral Med Oral Pathol Oral Radiol Endod*. 2004;97(1):95-9. PMID: 14716263.
3. Salama FS, Anderson RW, McKnight-Hanes C, Barenie JT, Myers DR. Anatomy of primary incisor and molar root canals. *Pediatr Dent*. 1992;14(2):117-8. PMID: 1502120.
4. Silva LA, Leonardo MR, Nelson-Filho P, Tanomaru JM. Comparison of rotary and manual instrumentation techniques on cleaning capacity and instrumentation time in deciduous molars. *J Dent Child (Chic)*. 2004;71(1):45-7. PMID: 15272656.
5. Kandaswamy D, Venkateshbabu N, Porkodi I, Pradeep G. Canal-centering ability: An endodontic challenge. *J Conserv Dent*. 2009;12(1):3-9. PMID: 20379433; PMCID: PMC2848810.

6. Barr ES, Kleier DJ, Barr NV. Use of nickel-titanium rotary files for root canal preparation in primary teeth. *Pediatr Dent*. 1999;21(7):453-4. PMID: 10633522.
7. Singhal M, Chaudhary CP, Anand R, Singh N, Sahni T. Recent advancements of indirect pulp capping in primary teeth: a review]. *Journal of Advanced Medical*. 2015;3(5):78-82. <https://jamsr.com/uploadfiles/29.RECENTADVANCEMENTSOFFINDIRECT-PULPCAPPINGINPRIMARYTEETH.20151204082855.pdf>
8. Nagaveni NB, Yadav S, Poornima P, Bharath KP, Mathew MG, Naveen Kumar PG. Volumetric evaluation of various obturation techniques in primary teeth using cone beam computed tomography - An in vitro study. *J Indian Soc Pedod Prev Dent*. 2017;35(3):244-8. PMID: 28762351.
9. Nurko C, Garcia-Godoy F. Evaluation of a calcium hydroxide/iodoform paste (Vi-tapex) in root canal therapy for primary teeth. *J Clin Pediatr Dent*. 1999;23(4):289-94. PMID: 10551129.
10. Estrela C, Mamede Neto I, Lopes HP, Estrela CR, Pécora JD. Root canal filling with calcium hydroxide using different techniques. *Braz Dent J*. 2002;13(1):53-6. PMID: 11870964.
11. Vashista K, Sandhu M, Sachdev V. Comparative evaluation of obturating techniques in primary teeth: an in vivo study. *Int J Clin Pediatr Dent*. 2015;8(3):176-80. PMID: 26628851; PMCID: PMC4647036.
12. Aragão AC, Pintor AVB, Marceliano-Alves M, Primo LG, Silva ASS, Lopes RT, et al. Root canal obturation materials and filling techniques for primary teeth: In vitro evaluation in polymer-based prototyped incisors. *Int J Paediatr Dent*. 2020;30(3):381-9. PMID: 31811738.
13. Marques RPS, Moura-Netto C, Oliveira NM, Bresolin CR, Mello-Moura ACV, Mendes FM, et al. Physicochemical properties and filling capacity of an experimental iodoform-based paste in primary teeth. *Braz Oral Res*. 2020;34:e089. PMID: 32785478.
14. Özer S, Şen Tunç E, Kalyoncuoğlu E, Gülcan B. Evaluation of different root canal filling methods in primary teeth. *Meandros Medical and Dental Journal*. 2018;19(2):132-7. <https://meandrosmedicaljournal.org/archives/archive-detail/article-preview/evaluation-of-different-root-canal-filling-methods/19508>
15. Orhan AI, Tatli EC. Evaluation of root canal obturation quality in deciduous molars with different obturation materials: an in vitro micro-computed tomography study. *Biomed Res Int*. 2021;2021:6567161. PMID: 34307660; PMCID: PMC8272653.
16. Ozturk G, Aydinbelge M, Gumus H. Comparison of various root canal filling materials and obturation techniques for primary teeth using microcomputed tomography. *J Adv Oral Res*. 2022;13(1):53-61. <https://journals.sagepub.com/doi/10.1177/23202068211036148>
17. Yahata Y, Masuda Y, Komabayashi T. Comparison of apical centring ability between incisal-shifted access and traditional lingual access for maxillary anterior teeth. *Aust Endod J*. 2017;43(3):123-8. PMID: 28084663; PMCID: PMC5509534.
18. Chougule RB, Padmanabhan MY, Mandal MS. A comparative evaluation of root canal length measurement techniques in primary teeth. *Pediatr Dent*. 2012;34(3):53-6. PMID: 22795146.
19. Yushkevich PA, Piven J, Hazlett HC, Smith RG, Ho S, Gee JC, et al. User-guided 3D active contour segmentation of anatomical structures: significantly improved efficiency and reliability. *Neuroimage*. 2006;31(3):1116-28. PMID: 16545965.
20. Coll JA, Sadrian R. Predicting pulpectomy success and its relationship to exfoliation and succedaneous dentition. *Pediatr Dent*. 1996;18(1):57-63. PMID: 8668572.
21. Jafarzadeh M, Saatchi M, Jafarnejadi P, Gooran M. Digital radiographic evaluation of the quality of different root canal obturation techniques in deciduous mandibular molars after preparation with rotary technique. *J Dent (Shiraz)*. 2019;20(3):152-8. PMID: 31579688; PMCID: PMC6732179.
22. Aminabadi NA, Asl Aminabadi N, Jamali Z, Shirazi S. Primary tooth pulpectomy overfilling by different placement techniques: A systematic review and meta-analysis. *J Dent Res Dent Clin Dent Prospects*. 2020;14(4):250-61. PMID: 33575016; PMCID: PMC7867685.
23. Pasternak-Júnior B, Sousa-Neto MD, Silva RG. Canal transportation and centring ability of RaCe rotary instruments. *Int Endod J*. 2009;42(6):499-506. PMID: 19298575.
24. Hiremath MC, Srivastava P. Comparative evaluation of endodontic pressure syringe, insulin syringe, jiffy tube, and local anesthetic syringe in obturation of primary teeth: An in vitro study. *J Nat Sci Biol Med*. 2016;7(2):130-5. PMID: 27433062; PMCID: PMC4934101.
25. Nezam S, Mukherjee CG, Shukla JN, Jha A, Khan SA, Tanwar AS. Comparative evaluation of efficacy of obturation techniques in deciduous teeth using cone-beam computed tomography: An In Vivo Study. *Int J Clin Pediatr Dent*. 2021;14(1):75-80. PMID: 34326588; PMCID: PMC8311760.
26. Demiralp KÖ, Kamburoğlu K, Güngör K, Yüksel S, Demiralp G, Uçok O. Assessment of endodontically treated teeth by using different radiographic methods: an ex vivo comparison between CBCT and other radiographic techniques. *Imaging Sci Dent*. 2012;42(3):129-37. PMID: 23071962; PMCID: PMC3465754.
27. Ochoa-Romero T, Mendez-Gonzalez V, Flores-Reyes H, Pozos-Guillen AJ. Comparison between rotary and manual techniques on duration of instrumentation and obturation times in primary teeth. *J Clin Pediatr Dent*. 2011;35(4):359-63. PMID: 22046692.
28. Crespo S, Cortes O, Garcia C, Perez L. Comparison between rotary and manual instrumentation in primary teeth. *J Clin Pediatr Dent*. 2008;32(4):295-8. PMID: 18767460.
29. Govindaraju L, Jeevanandan G, Subramanian E. Clinical evaluation of quality of obturation and instrumentation time using two modified rotary file systems with manual instrumentation in primary teeth. *J Clin Diagn Res*. 2017;11(9):ZC55-ZC8. PMID: 29207834; PMCID: PMC5713856.
30. Preethy NA, Jeevanandan G, Mathew MG, Subramanian EM. Evaluation of quality of obturation using two different rotary files and hand files in primary teeth: a randomized controlled trial. *Int J Clin Pediatr Dent*. 2021;14(4):471-4. PMID: 34824498; PMCID: PMC8585900.
31. Elayouti A, Chu AL, Kimionis I, Klein C, Weiger R, Löst C. Efficacy of rotary instruments with greater taper in preparing oval root canals. *Int Endod J*. 2008;41(12):1088-92. PMID: 19133098.
32. Guimaraes BM, Amoroso-Silva PA, Alcalde MP, Marciano MA, de Andrade FB, Duarte MA. Influence of ultrasonic activation of 4 root canal sealers on the filling quality. *J Endod*. 2014;40(7):964-8. PMID: 24935544.
33. Deveaux E, Dufour D, Boniface B. Five methods of calcium hydroxide intracanal placement: an in vitro evaluation. *Oral Surg Oral Med Oral Pathol Oral Radiol Endod*. 2000;89(3):349-55. PMID: 10710462.
34. Wiese PEB, Silva-Sousa YT, Pereira RD, Estrela C, Domingues LM, Pécora JD, et al. Effect of ultrasonic and sonic activation of root canal sealers on the push-out bond strength and interfacial adaptation to root canal dentine. *Int Endod J*. 2018;51(1):102-11. PMID: 28543092.
35. Walia T, Ghanbari AH, Mathew S, Ziadlou AH. An in vitro comparison of three delivery techniques for obturation of root canals in primary molars. *Eur Arch Paediatr Dent*. 2017;18(1):17-23. PMID: 27885586.
36. Ordinola-Zapata R, Bramante CM, Duarte MA, Cavenago BC, Jaramillo D, Versiani MA. Shaping ability of reciproc and TF adaptive systems in severely curved canals of rapid microCT-based prototyping molar replicas. *J Appl Oral Sci*. 2014;22(6):509-15. PMID: 24918662; PMCID: PMC4307764.
37. Reymus M, Stawarczyk B, Winkler A, Ludwig J, Kess S, Krastl G, et al. A critical evaluation of the material properties and clinical suitability of in-house printed and commercial tooth replicas for endodontic training. *Int Endod J*. 2020;53(10):1446-54. PMID: 32623735.