

# Conjunctival MALT Lymphoma: Case Report

## Konjonktivanın MALT Lenfoması

Sevdegül MUNGAN,<sup>a</sup>  
Şafak ERSÖZ,<sup>a</sup>  
Adem TÜRK,<sup>b</sup>  
Neşe KAKLIKKAYA,<sup>c</sup>  
Nurettin AKYOL<sup>b</sup>

Departments of  
<sup>a</sup>Pathology,  
<sup>b</sup>Ophthalmology,  
<sup>c</sup>Clinical Microbiology,  
Karadeniz Technical University  
Faculty of Medicine, Trabzon

Geliş Tarihi/Received: 27.12.2010  
Kabul Tarihi/Accepted: 10.11.2011

Yazışma Adresi/Correspondence:  
Sevdegül MUNGAN  
Karadeniz Technical University  
Faculty of Medicine,  
Pathology Department, Trabzon,  
TÜRKİYE/TURKEY  
sevdegulaydin@yahoo.com

**ABSTRACT** Mucosa associated lymphoid tissue (MALT) lymphoma (marginal zone B-cell lymphoma of MALT according to the World Health Organization classification) is one of the low-grade non-Hodgkin's lymphomas. The majority of non-Hodgkin's lymphomas of the ocular adnexa are extranodal marginal zone B-cell lymphomas of the mucosa associated lymphoid tissue, also known as MALT lymphoma. In 8% of cases, it arises from the conjunctiva. Lymphoid tumors of the conjunctiva may appear as isolated neoplasms or a part of a systemic disease. In this study, we presented a case of primary conjunctival lymphoma and discussed the etiology, diagnosis and treatment with reference to previous studies and reviews.

**Key Words:** Lymphoma, B cell, marginal zone; conjunctiva; etiology; therapy

**ÖZET** Mukoza ile ilişkili lenfoid doku (MALT) lenfoması (Dünya Sağlık Örgütü sınıflamasına göre MALT'nin marjinal zon B-hücreli lenfoması) bir düşük dereceli non-Hodgkin lenfoma türüdür. Oküler adneks non-Hodgkin lenfomalarının çoğu MALT lenfoması olarak bilinen, mukozal lenfoid dokunun ekstranodal B-hücreli marjinal zon lenfomasıdır. Hastalık vakalarının %8'inde konjonktivadan köken almaktadır. Konjonktivanın lenfoid tümörleri izole bir tümör olarak ya da sistemik bir hastalığın parçası olarak ortaya çıkabilmektedir. Burada, primer konjonktival lenfomalı bir olgu sunulmuş ve önceki çalışmalar ve derlemeler ışığında hastalığın etiyolojisi, tanı ve tedavisi tartışılmıştır.

**Anahtar Kelimeler:** Lenfoma, B hücreli, marjinal bölge; konjonktiva; etiyoloji; tedavi

**Türkiye Klinikleri J Med Sci 2012;32(5):1440-4**

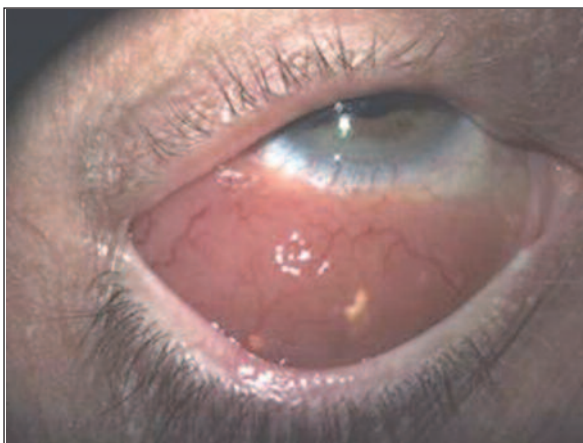
The conjunctiva, lacrimal gland and the lacrimal drainage system are encompassed in the common mucosal immune system, mucosa associated lymphoid tissue (MALT).<sup>1</sup> Lymphoid tumors of the conjunctiva may appear as isolated neoplasms or a part of a systemic disease, tend to remain localized for many years and have better prognosis than other low grade lymphomas.<sup>2</sup> It was first described in 1983 by Isaacson and Wright and now it is well-established in the revised European-American lymphoma (REAL) classification of lymphoid neoplasms and the more recently published World Health Organization classification system.<sup>3</sup> The typical clinical presentation of conjunctival lymphoma is a painless unilateral 'Salmon Patch'.<sup>4</sup> Primary lymphoid tumors of conjunctiva are well described, may affect both eyes but conjunctival metastasis from systemic spread seems to be rare.<sup>5-6</sup> The diagnosis is difficult, immunohistochemistry

may be necessary to differentiate malignant lymphoid infiltration from lymphoid hyperplasia or chronic conjunctivitis.

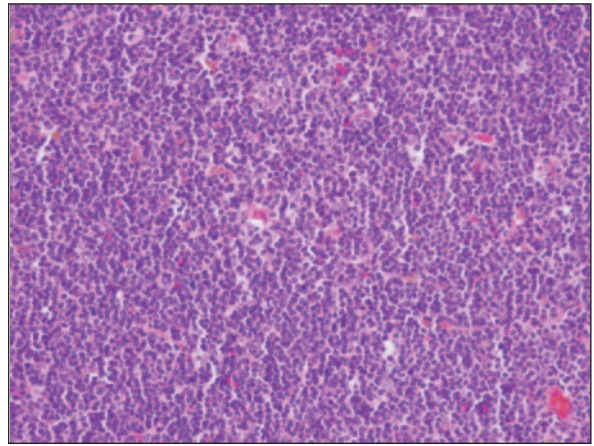
## CASE REPORT

A 60-year-old man presented to the ophthalmology clinic with a history of slowly growing, large swelling lesion in his left bulbar conjunctiva. He also suffered from motility problems of the left eye. On ophthalmologic examination, there was an approximately 2.5 cm diameter salmon colored lesion on his conjunctiva (Figure 1). There were neither systemic symptoms nor history of fever, weight loss or lymphadenopathy. Routine hematological and biochemical investigations were within normal limits.

The patient underwent excisional biopsy of the conjunctival lesion. Gross examination revealed a 2.5 cm diametered grey-brown solid lesion. On microscopic examination, the lesion had a nodular pattern, comprising of a mixture of small and large lymphocytes including prominent centrocytes and centroblasts. Neoplastic lymphocytes also infiltrated the surface epithelium. Mitotic division was not common in atypical lymphocytes (Figure 2). In immunohistochemical study, the neoplastic lymphoid cells were positive for the B-cell marker CD20 (Figure 3), kappa (Figure 4A), and negative for T-cell marker CD3 (Figure 5), CD5 and Cyclin D1, CD 43, CD10 and lambda (Figure 4B).



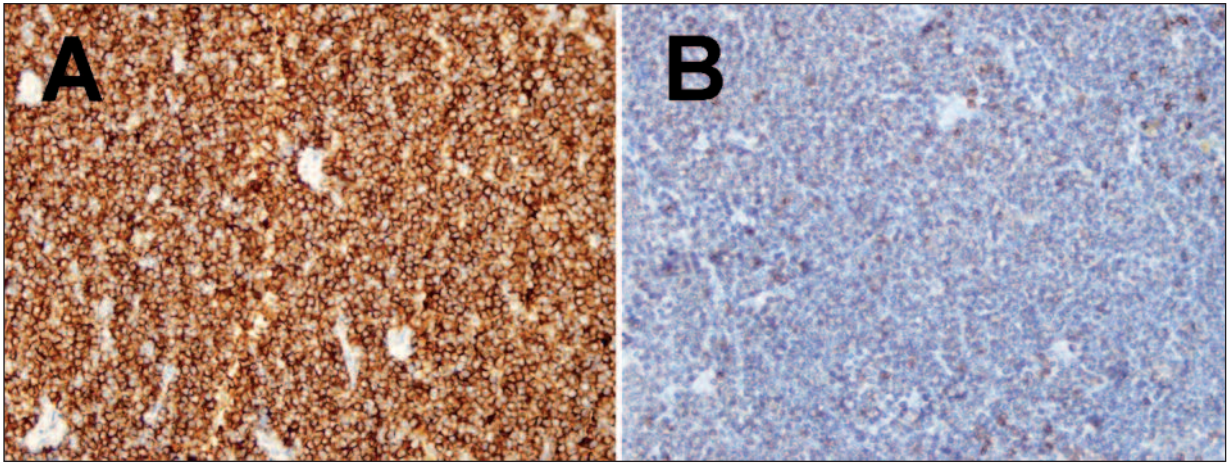
**FIGURE 1:** A Salmon-colored, large swelling lesion in left bulbar conjunctiva. (See for colored form <http://tipbilimleri.turkiyeklinikleri.com/>)



**FIGURE 2:** Neoplastic lymphoid infiltration (HE X 400). (See for colored form <http://tipbilimleri.turkiyeklinikleri.com/>)

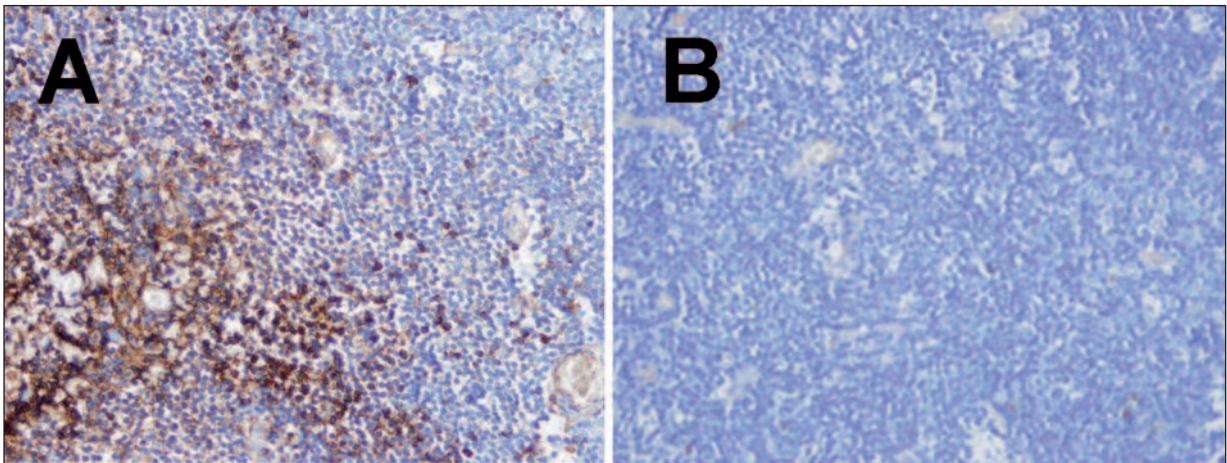
In whole body scan by computerized tomography (CT) no organ or lymph node involvement was present. The final pathologic diagnosis was primary MALT lymphoma with the absence of lymph node, organ or bone marrow involvement. The patient was given radiotherapy at a dose of 30 Gy. Six months of follow-up showed an improvement with shrinkage of the mass. The disease remained localized and did not show systemic involvement.

We also evaluated the role of *Helicobacter pylori* in the pathogenesis of MALT lymphoma by screening for *Helicobacter pylori* DNA in the conjunctival lymphoma tissue through polymerase chain reaction (PCR) technique. DNA for PCR was extracted from the tissue using a commercial DNA extraction kit (QIAamp DNA Mini Kit, Qiagen, Hilden, Germany). A PCR specific for *Helicobacter pylori* was used with a single primer pair derived from the nucleotide sequence of the urease A gene of *Helicobacter pylori* HPU1(5'GC-CAATGGTAAATTAGTT3') and HPU(5'CTCCT-TAATTGTTTTTAC3'). PCR reactions were performed as described by Clayton et al.<sup>7</sup> Negative control was performed using a reaction mixture with PCR grade water substituting the template DNA. Template DNA for positive control was obtained from a *Helicobacter pylori* infected, formalin-fixed, paraffin-embedded tissue. *Helicobacter pylori* was negative by PCR analysis technique in our case. The patient gave written informed consent for the publication of this case report.



**FIGURE 3: A)** CD20 positivism of the neoplastic lymphoid cells by immunohistochemical staining (IHK X 400) **B)** The neoplastic lymphoid cells are negative for CD3 by immunohistochemical staining (CD3 X 400)

(See for colored form <http://tipbilimleri.turkiyeklinikleri.com/>)



**FIGURE 4: A.** Neoplastic cells are positive with Kappa immunoglobulin (Kappa x 400) **B.** Neoplastic cells are negative with Lambda immunoglobulin by immunohistochemical staining (Lambda x 400).

(See for colored form <http://tipbilimleri.turkiyeklinikleri.com/>)

## DISCUSSION

The pathogenesis of the conjunctival MALT lymphoma is not known. It is thought to originate from acquired MALT in the conjunctiva. The lymphoma may arise from MALT as a result of chronic inflammation by persistent infections or autoimmune disorders.<sup>8-11</sup> A possible connection between ocular region MALT lymphoma and *Helicobacter pylori* has been reported by Lee et al in 2009.<sup>9</sup> They studied 15 cases of conjunctival lymphoma and isolated *Helicobacter pylori* by PCR from all patients and none of the controls. However in another

study by Sjö et al, *Helicobacter pylori* DNA was not detected in any of 13 conjunctival MALT lymphoma patients with PCR.<sup>10</sup> They claimed that *Helicobacter pylori* did not play an important role in the development of conjunctival MALT lymphoma. Other infectious agents (*Chlamydia*, Adenovirus, Herpes) and autoimmune diseases are other risk factors for MALT lymphoma of the conjunctiva.<sup>9</sup> In autoimmune diseases the increased lymphoma risk is mainly because of a high inflammatory activity and correlates with the severity of disease.<sup>11</sup> A number of reports suggest the role of *Chlamydia psittaci* in ocular MALT lymphoma

etiopathogenesis. Aigelsreiter et al. reported 15 positive results for *Chlamydia psittaci* in 13 ocular MALT lymphoma patients. He concluded that *Chlamydia psittaci* infection was associated with nongastrointestinal MALT lymphomas and autoimmune precursor lesions, suggesting possible involvement of *Chlamydia psittaci* induced antigenic driven MALT lymphomagenesis.<sup>12</sup>

Zhang et al. studied 38 ocular adnexal MALT lymphoma cases and detected genetic abnormalities in 60% of cases but no *Chlamydia psittaci* positivity. They reported that *Chlamydia psittaci* was not associated with ocular adnexal MALT lymphoma.<sup>13</sup> While several studies have reported an association with *Chlamydia psittaci* in certain geographic regions, this association is not universal and other predisposing conditions may exist.<sup>14</sup> Our case has not been investigated for *Chlamydia psittaci*.

The differential diagnosis is very important. It is very difficult for a pathologist to differentiate benign lymphoid hyperplasia or chronic conjunctivitis from malignant low-grade lymphoid infiltration. It is also challenging to differentiate MALT lymphoma from other small lymphocytic lymphomas and from mantle cell lymphoma with marginal zone pattern. We differentiated small lymphocytic lymphomas by immunohistochemical negativity of CD5 and CD23; cyclin D1 was also negative for mantle lymphoma.<sup>3,12</sup> Some techniques like immunohistochemistry or molecular techniques like PCR and fluorescent in situ hybridization (FISH) may be helpful for the definitive diagnosis.<sup>15-16</sup>

The differential diagnosis includes chronic conjunctivitis and benign lymphoid hyperplasia.<sup>9</sup> In chronic conjunctivitis and benign lymphoid hyperplasia, lymphoid infiltration consists of both CD20-positive B cells and CD3-positive T cells. In our case, neoplastic lymphoid infiltration showed diffuse CD20 positivity and assessment of clonality was demonstrated by immunoglobulin kappa light chain (monoclonality) restriction immunohistochemically.

Some immunohistochemical markers are also important in the prognosis of the disease. The prognosis of MALT lymphoma (extranodal low grade

B-cell non-Hodgkin's lymphoma) is better than nodal non-Hodgkin's lymphomas.<sup>11</sup> Wenzel et al reported that MALT lymphoma might express CD5 rarely but aberrant CD5 expression was suggested as a marker for early dissemination, aggressive clinical course and possibility of relapse after local radiotherapy.<sup>17</sup> Also Nola et al reported that CD43 positive ocular lymphomas were associated with a higher rate of distant metastases and lymphoma-related death.<sup>18</sup> Our current case was negative for CD5 and CD43.

MALT lymphoma of conjunctiva has a favorable prognosis. The estimated 5-year overall survival was approximately 93%.<sup>2</sup> Some authors recommend radiotherapy for all subtypes of primary lymphoma.<sup>6</sup> On the other hand, Matsuo et al reported the results of different treatment choices in 13 conjunctival MALT lymphoma patients.<sup>19</sup> While five of 13 patients received 30 Gy radiotherapy to remaining conjunctival lesions after the biopsy, the remaining 8 cases were simply observed without any medication. Seven of these 8 patients showed spontaneous regression of the conjunctival lesions 1 to 5 years after the biopsy.<sup>19</sup> Kiratli H. et al reported a lacrimal gland MALT lymphoma in 1999 without any supplemental therapy. No systemic dissemination or local recurrence occurred during a follow-up of 26 months.<sup>20</sup> According to these reports of spontaneous regression of conjunctival MALT lymphoma following excisional biopsy for histopathological diagnosis, patients may be monitored without any additional therapy.<sup>21</sup>

Our case was treated by low dose local radiotherapy. Some authors recommend radiotherapy for all subtypes of lymphoma. In addition, new therapeutic approaches such as intraocular chemotherapy, cryotherapy or injection of interferon have been investigated in small groups of patients.<sup>18,22-24</sup>

In conclusion, most of the conjunctival lymphoma patients present with low-grade B-cell lymphoma of MALT type. The pathogenesis of the disease is not known clearly but some hypotheses were discussed above. MALT lymphoma of the conjunctiva has an excellent prognosis. The diag-

nosis of conjunctival lymphoma is not easy; thus, a lymphoma reference pathologist is usually required to differentiate chronic conjunctivitis for difficult

cases. This case was reported for the importance of the diagnosis because of its excellent prognosis and to prevent invasive treatment options.

## REFERENCES

- Knop E, Knop N. Lacrimal drainage-associated lymphoid tissue (LDALT): a part of the human mucosal immune system. *Invest Ophthalmol Vis Sci* 2001;42(3):566-74.
- Shields CL, Shields JA, Carvalho C, Rundle P, Smith AF. Conjunctival lymphoid tumors: clinical analysis of 117 cases and relationship to systemic lymphoma. *Ophthalmology* 2001;108(5):979-84.
- Lim SH, Kang M, Son J. Extranodal marginal zone B cell lymphoma of mucosa-associated lymphoid tissue type of the ocular adnexa: retrospective single institution review of 95 patients. *Indian J Ophthalmol* 2011;59(4):273-7.
- Pichierri P, Martone G, Loffredo A, Traversi C, Polito E. In vivo confocal microscopy in a patient with conjunctival lymphoma. *Clin Experiment Ophthalmol* 2008;36(1):67-9.
- Suh CO, Shim SJ, Lee SW, Yang WI, Lee SY, Hahn JS. Orbital marginal zone B-cell lymphoma of MALT: radiotherapy results and clinical behavior. *Int J Radiat Oncol Biol Phys* 2006;65(1):228-33.
- Reiser M, Josting A, Diehl V, Engert A. Primary lymphoma of the conjunctiva--a rare manifestation of indolent non-Hodgkin's lymphoma. *Ann Hematol* 2001;80(5):311-3.
- Clayton CL, Kleanthous H, Coates PJ, Morgan DD, Tabaqchali S. Sensitive detection of *Helicobacter pylori* by using polymerase chain reaction. *J Clin Microbiol* 1992;30(1):192-200.
- Nazligul Y. [*Helicobacter pylori* and upper gastrointestinal diseases: review]. *Turkiye Klinikleri J Gastroenterohepatol* 2009;16(2): 69-75.
- Sjö LD. Ophthalmic lymphoma: epidemiology and pathogenesis. *Acta Ophthalmol* 2009;87 Thesis 1:1-20.
- Lee SB, Yang JW, Kim CS. The association between conjunctival MALT lymphoma and *Helicobacter pylori*. *Br J Ophthalmol* 2008;92(4):534-6.
- Ioannidis JP, Vassiliou VA, Moutsopoulos HM. Long-term risk of mortality and lymphoproliferative disease and predictive classification of primary Sjögren's syndrome. *Arthritis Rheum* 2002;46(3):741-7.
- Aigelsreiter A, Gerlitz T, Deutsch AJ, Leitner E, Beham-Schmid C, Beham A, et al. Chlamydia psittaci infection in nongastrointestinal extranodal MALT lymphomas and their precursor lesions. *Am J Clin Pathol* 2011;135(1):70-5.
- Zhang D, Dong L, Li H, Jin H, Ye H, Zhou X, et al. Ocular adnexal mucosa-associated tissue lymphoma in Northern China: high frequency of numerical chromosomal changes and no evidence of an association with *Chlamydia psittaci*. *Leuk Lymphoma* 2010;51(11):2031-8.
- Bayraktar S, Bayraktar UD, Stefanovic A, Losos IS. Primary ocular adnexal mucosa associated lymphoid tissue lymphoma (MALT): single institution experience in a large cohort of patients. *Br J Haematol* 2011;152(1):72-80.
- Nağıyev T, Köksal F, Abaylı B, Yula E. [A comparison of culture and GLMM-PCR methods for detecting *Helicobacter pylori* in antral and corpus biopsy specimens in patients with gastroduodenal disorders]. *Turkiye Klinikleri J Med Sci* 2010;30(3):919-24.
- da Cunha Santos G, Ko HM, Geddie WR, Boerner SL, Lai SW, Have C, et al. Targeted use of fluorescence in situ hybridization (FISH) in cytospin preparations: results of 298 fine needle aspirates of B-cell non-Hodgkin lymphoma. *Cancer Cytopathol* 2010;118(5):250-8.
- Wenzel C, Dieckmann K, Fiebiger W, Mannhalter C, Chott A, Raderer M. CD5 expression in a lymphoma of the mucosa-associated lymphoid tissue (MALT)-type as a marker for early dissemination and aggressive clinical behaviour. *Leuk Lymphoma* 2001;42(4):823-9.
- Nola M, Lukenda A, Bollmann M, Kalauz M, Petroveci M, Bollmann R. Outcome and prognostic factors in ocular adnexal lymphoma. *Croat Med J* 2004;45(3):328-32.
- Matsuo T, Yoshino T. Long-term follow-up results of observation or radiation for conjunctival malignant lymphoma. *Ophthalmology* 2004;111(6):1233-7.
- Kiratli H, Söylemezoglu F, Bilgiç S, Ruacan Ş. Mucosa-associated lymphoid tissue lymphoma of the lacrimal gland. *Ophthalm Plast Reconstr Surg* 1999;15(4):272-9.
- Matsuo T, Ichimura K, Yoshino T. Spontaneous regression of bilateral conjunctival extranodal marginal zone B-cell lymphoma of mucosa-associated lymphoid tissue. *J Clin Exp Hematop* 2007;47(2):79-81.
- Cellini M, Possati GL, Puddu P, Caramazza R. Interferon alpha in the therapy of conjunctival lymphoma in an HIV+ patient. *Eur J Ophthalmol* 1996;6(4):475-7.
- Eichler MD, Fraunfelder FT. Cryotherapy for conjunctival lymphoid tumors. *Am J Ophthalmol* 1994;118(4):463-7.
- Fishburne BC, Wilson DJ, Rosenbaum JT, Neuwelt EA. Intravitreal methotrexate as an adjunctive treatment of intraocular lymphoma. *Arch Ophthalmol* 1997;115(9):1152-6.