

## CASE REPORT

DOI: 10.5336/caserep.2024-104873

# Isolated Left Hypoglossal Nerve Palsy Secondary to Left Internal Carotid Artery Dissection

<sup>1</sup>Mürüvvet POYRAZ<sup>a</sup>, <sup>2</sup>Nur Beyza TÜKEK<sup>b</sup>, <sup>3</sup>Aslım ZADIKOĞLU TEKYAN<sup>c</sup>, <sup>4</sup>Zeliha MATUR<sup>a</sup>

<sup>a</sup>Bezmîâlem University Faculty of Medicine, Department of Neurology, İstanbul, Türkiye

<sup>b</sup>Tekirdağ Saray State Hospital, Clinic of Internal Medicine, Tekirdağ, Türkiye

<sup>c</sup>Bakırköy Kızılay Medical Center, Clinic of Neurology, İstanbul, Türkiye

**ABSTRACT** Unilateral hypoglossal palsy, a rare condition causing one-sided tongue weakness or paralysis, often arises from medullary lesions but can also relate to other cranial nerve deficits from subarachnoid, skull base, or extracranial lesions. We report a rare case of isolated left hypoglossal nerve palsy due to left internal carotid artery (ICA) dissection. A woman in her 40s presented with dysphagia, dysarthria, and left-sided tongue weakness following a dental intervention. She experienced persistent headaches, which subsided over two weeks. Neurological examination revealed left tongue deviation and atrophy. Magnetic resonance angiography showed dissection of the distal cervical ICA with an intramural thrombus. The patient was treated with antiplatelet therapy and advised on physiotherapy for tongue and speech rehabilitation. At three-month follow-up, she showed recovery of tongue paresis and dysarthria. ICA dissection can cause isolated hypoglossal nerve palsy, highlighting the need to consider this diagnosis in cranial nerve palsy cases without trauma history.

**Keywords:** Internal carotid dissection; unilateral hypoglossal nerve palsy; tongue atrophy

Unilateral hypoglossal (12<sup>th</sup> cranial nerve) nerve palsy is a rare condition characterized by weakness or paralysis of one side of the tongue. While it typically arises from medullary lesions, it can also manifest in association with other lower cranial nerve deficits in cases of subarachnoid space, skull base, and extracranial lesions involving other motor and sensory pathways.

We present a rare case of isolated left hypoglossal nerve palsy resulting from left internal carotid artery (ICA) dissection.

## CASE REPORT

A female patient in her 40s presented with complaints of difficulty swallowing (dysphagia), slurred speech (dysarthria), and weakness on the left side of her tongue. We learned that she had trouble chewing and

swallowing any liquid or solid substance following a headache that began after her dental intervention last month. She complained of headaches that began at the back of her neck and gradually subsided over a 15-day period. Her past medical history was unremarkable, including medication use, infection, or trauma. She denied smoking or alcohol consumption. She had no history of head or neck surgery.

Her temperature was 36.5°C, blood pressure was 110/70 mm/Hg, pulse 76/min. She was conscious, oriented, and cooperative. Upon neurological examination, the patient's tongue deviated to the left, and the left side of the tongue was atrophic with weakness on the leftward protrusion (Figure 1). The duration of these symptoms (dysphagia, dysarthria, tongue weakness) was not entirely clear, but they all seemed to have developed within the past few weeks.

### TO CITE THIS ARTICLE:

Poyraz M, Tükek NB, Zadikoğlu Tekyan A, Matur Z. Isolated left hypoglossal nerve palsy secondary to left internal carotid artery dissection. Türkiye Klinikleri J Case Rep. 2025;33(1):27-30.

**Correspondence:** Nur Beyza TÜKEK

Tekirdağ Saray State Hospital, Clinic of Internal Medicine, Tekirdağ, Türkiye

**E-mail:** beyza.tuekek@hotmail.com

Peer review under responsibility of Türkiye Klinikleri Journal of Case Reports.

**Received:** 21 Jul 2024

**Accepted:** 24 Sep 2024

**Available online:** 30 Sep 2024

2147-9291 / Copyright © 2025 by Türkiye Klinikleri. This is an open access article under the CC BY-NC-ND license (<http://creativecommons.org/licenses/by-nc-nd/4.0/>).



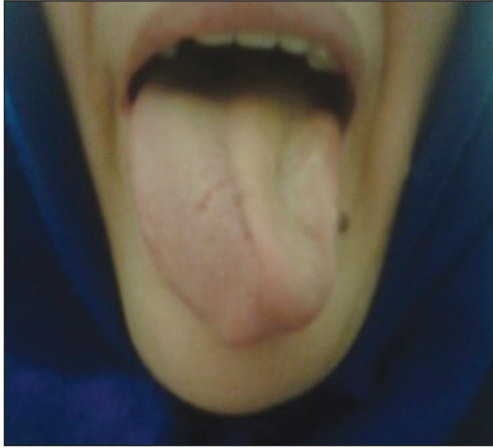

FIGURE 1: Tongue examination of the patient.

Her facial strength was normal, and the remaining cranial nerve and upper and lower limb examinations were normal. The systemic examinations were also normal.

Biochemistry and complete blood count were within normal limits. C-reactive protein, erythrocyte sedimentation rate were normal. Viral hepatitis, Epstein-Barr virus immunoglobulin M (IgM), cytomegalovirus IgM, human immunodeficiency virus and syphilis serology were negative. Serum glucose was 90 mg/dL, and lipid levels were normal. The rheumatologic panel was unremarkable. A chest X-ray (posteroanterior view) had no abnormalities. Cranial and cervical magnetic resonance imaging (MRI) with MR angiography was performed. There was no evidence of tumor, space-occupying lesion, or de-

myelinating disease on cranial MRI. Cervical MR angiography revealed dissection of the distal cervical ICA and intramural thrombus adjacent to the vessel, consistent with the clinical picture (Figure 2).

The patient was diagnosed with hypoglossal nerve palsy secondary to ICA dissection and received antiplatelet therapy with clopidogrel. After antiplatelet therapy, the patient was recommended physiotherapy for tongue movements and speech. At three-month follow-up, improvement in language paralysis and dysarthria was observed.

Written informed consent was obtained from the patient before the report was written.

## DISCUSSION

The hypoglossal nerve innervates all intrinsic and extrinsic muscles of the tongue except the palatoglossus.<sup>1</sup> The cell bodies of the hypoglossal nerve are located in the hypoglossal nucleus, which is situated dorsally to the vagus in the midline of the medulla. Fibers from the hypoglossal nucleus pass ventrally lateral to the medial lemniscus and emerge from the medulla as roots between the pyramids and the inferior olivary nuclei. These roots combine to form the hypoglossal nerve, which exits the base of the skull through the hypoglossal canal. Descending behind the ICA and the vagus nerve, it makes a loop, traveling laterally and posteriorly to these structures to reach the root of the tongue.

Different pathologies in different segments can cause hypoglossal nerve damage. These segments in-

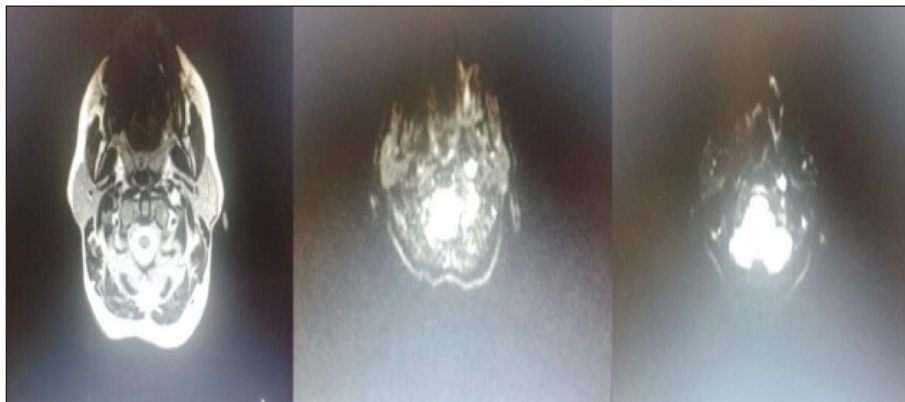


FIGURE 2: a, b, c) Magnetic resonance imaging angiography images with left distal internal carotid dissection.

clude the medulla oblongata, subarachnoid space, skull base, exit of the hypoglossal canal, and upper neck. Due to the proximity of the hypoglossal nerve to the internal jugular vein and ICA, it can be damaged in pathologies related to cervical vessels (such as carotid artery aneurysm, dissection, trauma, glomus jugulare tumor, metastasis) or during surgical treatments of these pathologies.<sup>2</sup>

In the etiology of hypoglossal nerve damage, 100 cases were reviewed, and the etiology revealed tumors in 49 patients, gunshot wounds in 12, stroke in 6, hysteria in 6, multiple sclerosis in 6, surgical interventions in 5, Guillain-Barré neuropathy in 4, and infection in 4 patients.<sup>3</sup> In another study in which 245 cases were evaluated retrospectively, the causes of hypoglossal nerve palsy were found to be postoperative (29.3%, the most of carotid endarterectomy), idiopathic (15.1%), primary neoplastic (14.2%), metastatic malignancy (13.0%), inflammatory (7.3%), radiation (6.1%), and traumatic (4.1%).<sup>4</sup> According to Combarros, there are 10 main causes in the etiology of isolated hypoglossal nerve damage. These include skull base metastasis, hypoglossal nerve schwannoma, carcinomatous meningitis, radiation neuropathy, trauma resulting from gunshot wounds and carotid endarterectomy, extracranial ICA dissection, dolichoectatic vertebral artery, infectious mononucleosis, post-vaccination neuropathy, and reversible idiopathic cases.<sup>5</sup> Cases secondary to tracheal intubation and teeth extraction have also been reported.<sup>6-8</sup>

ICA dissection-induced hypoglossal nerve palsy is rarely reported. Causes of ICA dissection include specific traumas such as coughing, vomiting, unusual sleeping positions, hair washing at beauty salons, and shaking the head to music, as well as connective tissue disorders like Marfan's syndrome, osteogenesis imperfecta, Ehlers-Danlos syndrome, hypertension, migraine, autosomal dominant polycystic kidney disease, and hyperhomocysteinemia.<sup>9</sup> In spontaneous dissection cases, fibromuscular dysplasia (FMD) should also be considered. Our patient's involvement was unilateral without the characteristic beaded string appearance of FMD. Mokri et al. found cranial nerve palsy in 12% of patients with spontaneous dissection. Cranial nerve palsy in ICA dissection is caused by ei-

ther compression or stretching of the nerve by the enlarged artery or damage to the vessels supplying the nerve.<sup>10</sup>

Common symptoms of cervical artery dissection include headache and ipsilateral neck pain for vertebral artery involvement, and periorbital, frontal, and upper cervical pain for ICA involvement.<sup>11</sup> Horner's syndrome and hemispheric ischemic stroke can also accompany these symptoms. Isolated hypoglossal nerve palsy may be the only presenting sign.

In ICA dissection, sub-adventitial bleeding between the tunica media and adventitia can expand the artery's outer wall, forming a pseudoaneurysm. On MRI, this appears as a crescent-shaped T1 high signal (mural hematoma) on fat-suppressed T1-weighted images, with varying luminal narrowing. A study of 71 carotid artery dissection patients found that nearly half had pseudoaneurysms. Initial presentations were similar between patients with and without pseudoaneurysms; however, painful Horner's syndrome and dysfunction of the 9<sup>th</sup> and 12<sup>th</sup> cranial nerves were more common with aneurysms. During follow-up, patients with aneurysms showed no transient ischemic attacks, strokes, or signs of aneurysm rupture or compression.<sup>12</sup>

The diagnosis of ICA dissection is typically made with cranial MRI, MR or CT angiography in such patients. Digital subtraction angiography remains the gold standard in diagnosing dissection.<sup>13</sup> In our case, ICA dissection, which we believe occurred following cervical hyperextension during the dental treatment, and the resulting isolated hypoglossal nerve palsy were detected. ICA dissection should be considered in cases of cranial nerve palsy, regardless of the presence of a trauma history.

Antiplatelet or anticoagulant drugs are commonly used in the treatment of cervical artery dissection. Among patients without evidence of stroke, the risk of stroke is predominantly highest within the first two weeks.<sup>14</sup> Therefore, prompt administration of antithrombotic therapy is crucial to mitigate this risk. Despite the common use of these treatments, further research is necessary to determine the optimal type and duration of antithrombotic therapy for effective stroke prevention in these patients.

### Source of Finance

During this study, no financial or spiritual support was received neither from any pharmaceutical company that has a direct connection with the research subject, nor from a company that provides or produces medical instruments and materials which may negatively affect the evaluation process of this study.

### Conflict of Interest

No conflicts of interest between the authors and / or family members of the scientific and medical committee members or members of the potential conflicts of interest, counseling, expertise,

working conditions, share holding and similar situations in any firm.

### Authorship Contributions

**Idea/Concept:** Mürüvvet Poyraz, Nur Beyza Tükek; **Design:** Mürüvvet Poyraz; **Control/Supervision:** Mürüvvet Poyraz, Zeliha Matur; **Data Collection and/or Processing:** Aslın Zadıkoğlu Tekyan, Mürüvvet Poyraz; **Analysis and/or Interpretation:** Aslın Zadıkoğlu Tekyan, Mürüvvet Poyraz; **Literature Review:** Nur Beyza Tükek; **Writing the Article:** Mürüvvet Poyraz, Nur Beyza Tükek; **Critical Review:** Zeliha Matur; **References and Findings:** Nur Beyza Tükek, Aslın Zadıkoğlu Tekyan; **Materials:** Aslın Zadıkoğlu Tekyan.

## REFERENCES

- Kim SY, Naqvi IA. Neuroanatomy, Cranial Nerve 12 (Hypoglossal) [Updated 2022 Nov 7]. In: StatPearls [Internet]. Treasure Island (FL): StatPearls Publishing; 2024. Available from: [\[Link\]](#)
- Sweeney PJ, Hanson MR. Cranial neuropathies. In: Bradley WG, Darof RB, Fenichel GM, Jankovic J, eds. Neurology in Clinical Practice. 4th ed. Philadelphia: Butterworth Heineman; 2004. p.2120-3.
- Keane JR. Twelfth-nerve palsy. Analysis of 100 cases. Arch Neurol. 1996;53(6):561-6. [\[Crossref\]](#) [\[PubMed\]](#)
- Stino AM, Smith BE, Temkit M, Reddy SN. Hypoglossal nerve palsy: 245 cases. Muscle Nerve. 2016;54(6):1050-4. [\[Crossref\]](#) [\[PubMed\]](#)
- Combarros O, Alvarez de Arcaya A, Berciano J. Isolated unilateral hypoglossal nerve palsy: nine cases. J Neurol. 1998;245(2):98-100. [\[Crossref\]](#) [\[PubMed\]](#)
- Hong SJ, Lee JY. Isolated unilateral paralysis of the hypoglossal nerve after transoral intubation for general anesthesia. Dysphagia. 2009;24(3):354-6. [\[Crossref\]](#) [\[PubMed\]](#)
- Cinar SO, Seven H, Cinar U, Turgut S. Isolated bilateral paralysis of the hypoglossal and recurrent laryngeal nerves (Bilateral Tapia's syndrome) after transoral intubation for general anesthesia. Acta Anaesthesiol Scand. 2005;49(1):98-9. [\[Crossref\]](#) [\[PubMed\]](#)
- De Santis F, Martini G, Thüringen P, Thaler M, Mani G, Steckholzer K. Internal carotid artery dissection after inferior alveolar nerve block for third molar dental care presented as hypoglossal nerve palsy. Vasc Endovascular Surg. 2012;46(7):591-5. [\[Crossref\]](#) [\[PubMed\]](#)
- Haneline MT, Rosner AL. The etiology of cervical artery dissection. J Chiropr Med. 2007;6(3):110-20. [\[Crossref\]](#) [\[PubMed\]](#) [\[PMC\]](#)
- Mokri B, Silbert PL, Schievink WI, Piepgras DG. Cranial nerve palsy in spontaneous dissection of the extracranial internal carotid artery. Neurology. 1996;46(2):356-9. [\[Crossref\]](#) [\[PubMed\]](#)
- Haneline MT, Lewkovich G. Identification of internal carotid artery dissection in chiropractic practice. J Can Chiropr Assoc. 2004;48(3):206-10. [\[PubMed\]](#) [\[PMC\]](#)
- Touzé E, Randoux B, Méary E, Arquizan C, Meder JF, Mas JL. Aneurysmal forms of cervical artery dissection : associated factors and outcome. Stroke. 2001;32(2):418-23. [\[Crossref\]](#) [\[PubMed\]](#)
- Mes M, Palczewski P, Szczudlik P, Łusakowska A, Maj E, Gawel M. Hypoglossal nerve palsy as an isolated syndrome of internal carotid artery dissection: A review of the literature and a case report. Neurol Neurochir Pol. 2018;52(6):731-5. [\[Crossref\]](#) [\[PubMed\]](#)
- Morris NA, Merkler AE, Gialdini G, Kamel H. Timing of incident stroke risk after cervical artery dissection presenting without ischemia. Stroke. 2017;48(3):551-55. Erratum in: Stroke. 2018;49(10):e308. [\[Crossref\]](#) [\[PubMed\]](#) [\[PMC\]](#)