






## Pregnancy and Klippel-Trenaunay Syndrome

 Ersin ÇİNTESUN,<sup>a</sup>  
 Ayşe Gül KEBAPÇILAR,<sup>a</sup>  
 Setenay Arzu YILMAZ,<sup>a</sup>  
 Serra AKAR,<sup>a</sup>  
 Çetin ÇELİK<sup>a</sup>

<sup>a</sup>Department of Obstetrics and Gynecology,  
Selcuk University Faculty of Medicine,  
Konya

Received: 13.12.2017  
 Received in revised form: 21.03.2018  
 Accepted: 22.03.2018  
 Available online: 17.09.2018

Correspondence:  
 Ersin ÇİNTESUN  
 Selcuk University Faculty of Medicine,  
 Department of Obstetrics and Gynecology,  
 Konya, TURKEY  
 ersincintesun@gmail.com

This work was presented as a poster at  
 12<sup>th</sup> Congress of the European Society of  
 Gynecology, 18-21 October, Barcelona.

**ABSTRACT** Klippel-Trenaunay syndrome (KTS) is a congenital disease, characterized by two major features: vascular malformations and localized disturbed growth of bone or soft tissue. The risk of thromboembolic disease and bleeding is high in KTS. Therefore, obstetric and anesthetic management in pregnancies with KTS can be very complex. We aimed to report and discuss a rare case of a patient with KTS and pregnancy.

**Keywords:** Klippel-Trenaunay syndrome; varicose vein; pregnancy complications

**K**lippel-Trenaunay syndrome (KTS) is a congenital disease that is characterized by vascular malformations and localized disturbed growth of bone or soft tissue.<sup>1</sup> KTS has a rare incidence and estimated prevalence of 1 in 30 000-100 000 liveborn neonates.<sup>2</sup> The association of pregnancy with KTS is very rare.<sup>3</sup>

The etiology of KTS is not well-understood; however, it is most likely the result of a somatic mosaic activating mutation in the PIK3CA gene.<sup>4</sup> Somatic mosaic mutations are typically not transmitted to offspring and KTS is considered to be a non-hereditary disease.<sup>4</sup> Several theories that have been proposed include abnormalities of the sympathetic nervous system and persistence of fetal microscopic small arterio-venous anastomoses.<sup>5</sup> KTS may also be accompanied by lymphatic drainage defects following extremity growth.<sup>1</sup>

Both the disturbed growth and the vascular malformations in KTS generally affect the extremities; however, the vascular malformations often affect a larger area of the body and may extend to the trunk and pelvic region, including external and internal genitalia.

Since normal physiological changes during pregnancy increase the risk of thromboembolic disease and bleeding, obstetric and anesthetic management of KTS during pregnancy can be quite complex.<sup>6</sup> We aimed to report and discuss a rare case of pregnancy in a patient with KTS managed in our clinic.

## CASE REPORT

The patient was a 22 year-old female who was admitted to the obstetrics clinic upon referral at 36<sup>th</sup> gestational week due to KTS coexisting with her pregnancy. Her obstetric history was gravidity 1 and parity 0. She had been diagnosed with KTS in childhood and had not received any treatment due to absence of symptoms until 5 years earlier. That year she had undergone varicose vein surgery in her left leg because of pain. She weighed 65 kg. She had no family history of KTS or thrombosis. Throughout her pregnancy she did not receive prophylactic low-molecular-weight heparin (LMWH).

The left leg of the patient was 5 cm longer than her right leg and the left leg and arm were hypertrophied. Abnormal presences of varicose veins were noted on the left leg. The left side of the patient's body and both sides of her face and hands were sharply demarcated, dark and light red (Figures 1-4). Multiple vaginal venous varicosities, which blocked the introitus and diffuse cervical hemangiomas were observed on physical examination. During the examination, uterine contractions were detected and the patient was hospitalized.

PT, aPTT, INR were all within reference range. After a cardiovascular surgery consultation, the patient began taking enoxaparin sodium (Ok-sapar 6000 ANTI-XA IU/0.6 mL Koçak Farma, Tekirdağ, Turkey) and wore elastic compression stockings.

After five days of hospitalization, uterine contractions increased and cervical dilation began. Abdominal ultrasonography showed no abnormal vascularity on the anterior surface of the abdomen. Cesarean section was performed under general anesthesia due to obstructive varicose veins in the vulvovaginal region. Regional anesthesia could not be performed because vascular anomalies of the neuraxial region could not be assessed. She delivered a healthy male infant weighing 2,950 g, with Apgar scores of 8 and 9 at 1 and 5 minutes, respectively. Upon delivery, neonatal exam of the newborn by a pediatrician was unremarkable. 20 IU of Oxytocin (Synpitan forte, Koçak Farma, Turkey)

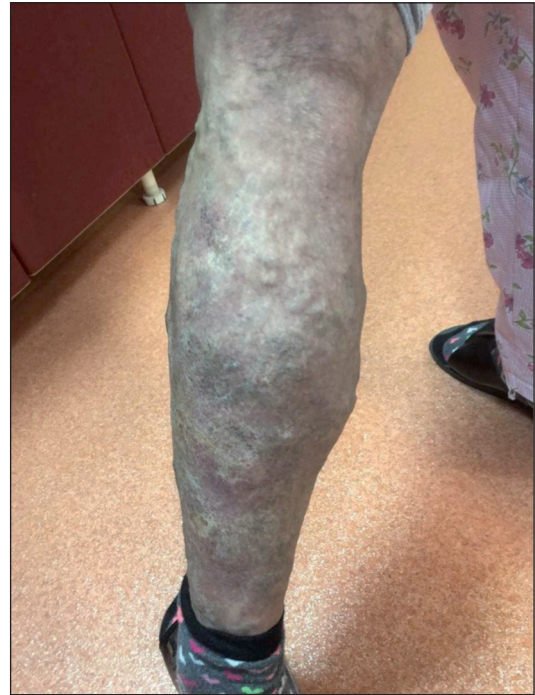

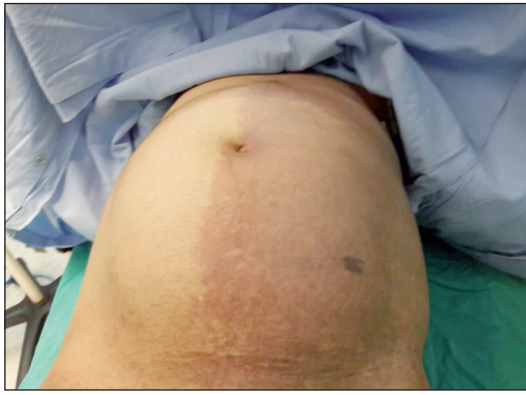
FIGURE 1: The image of the patient's leg.

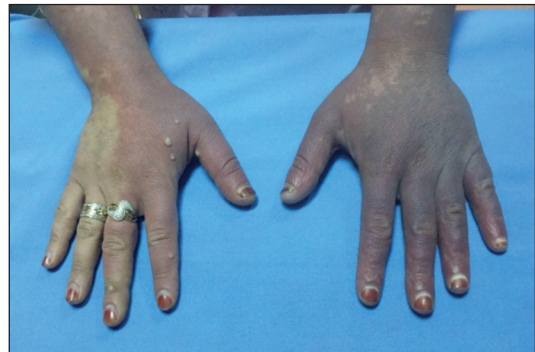

FIGURE 2: The image of the patient's hands.

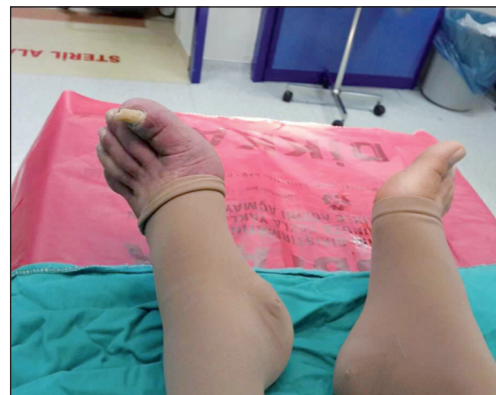

FIGURE 3: The image of the patient's feet.



**FIGURE 4:** The image of the patient's abdomen.

was administered as part of a standard procedure in our clinic for prevention of postpartum hemorrhage. LMWH prophylaxis and early mobilization were performed at fourth hour postoperatively. The subcutaneous LMWH was prescribed for six weeks after delivery. There were no complications in the postpartum period. The patient's informed consent was obtained for publication of her case.

## DISCUSSION

Pregnancies in patients with KTS can be difficult to manage due to the myriad of vascular anomalies and thromboembolic complications.<sup>3</sup> Despite previous reports of KTS in the literature, details on prognosis and management are lacking.<sup>3</sup> However, it is well-known that due to the vascular alterations in pregnancy such as rise in venous pressure, cardiac output and venous stillness, KTS is further exacerbated. Subsequently, these patients are prone to experience thromboembolic and hemorrhagic complications during pregnancy.

There is an increased risk of rectal, vaginal or vulvar bleeding in pregnancies complicated by KTS due to vessel anomalies. Ultrasound evaluation is useful for selecting the route of delivery as well as in the regular assessment of patients with vessel anomalies. In some cases, a widespread varicosity involving the vulvovaginal area can lead to narrowing of the birth canal, necessitating cesarean section.<sup>7</sup> Pelvic and cerebral or spinal vessel anomalies may increase the risk of complications. Vascular anomalies are associated with low platelet counts and coagulation disorders as well as stroke.<sup>8</sup>

The presence of vessel anomalies in the spine may lead to the occurrence of hematomas upon administration of regional anesthetics. Due to the presence of varicose veins blocking the vaginal introitus, our patient underwent cesarean section. Regional anesthesia could not be performed because the vascular structures adjacent to the lumbosacral vertebra could not be assessed.

Bleeding risk in pregnant patients with KTS can be reduced by meticulous identification of pelvic vessel abnormalities in order to determine the route of delivery. Antenatal sonography is used for assessing the presence of vessel anomalies within the uterus.<sup>9</sup> To prevent traumatic puncture of these vessels, magnetic resonance imaging (MRI), which detects angiodyplastic vascular structures, is recommended.<sup>3</sup> It is crucial to consult with anesthetists and cardiovascular surgeons before delivery. If there is no vascular anomaly in the lumbosacral region, regional anesthesia can be performed. General anesthesia was administered to our patient because the presence of such anomalies could not be ruled out on MRI.

In women with KTS, few cases were published reporting postpartum hemorrhage.<sup>10</sup> Selective arterial embolization and stitching were used in a patient with deep tears in the vagina following vaginal birth.<sup>10</sup> In patients with KTS, some cases had severe bleeding in the gastrointestinal, urinary tracts.<sup>11,12</sup> Since KTS has a diverse course, a general treatment protocol does not exist and therapy should be individualized.

Anticoagulant therapy such as aspirin or heparin could effectively prevent thromboembolic diseases.<sup>13</sup> Elastic compressive socks and LMWH prophylaxis were started before and after delivery to prevent postpartum thrombosis due to the presence of varicosities in our patient. We did not use aspirin because of the possibility of surgery. In addition, we tried to reduce the risk of thromboembolism by early mobilization of the patient.

Multidisciplinary management of these patients should include a team of gynecologists, anesthesiologists, vascular surgeons and hematologists. Except for obstetric conditions that may compli-

cate the disease, KTS itself is not an indication for cesarean section. In the literature, there are some spontaneous delivery cases.<sup>6</sup> The caesarean section may be complicated by abnormal vascular malformations. In the postpartum period, prophylactic anticoagulation is usually recommended. We chose caesarean section because of varicose veins located in the vulvovaginal region and cervical hemangiomas, which are commonly seen in KTS.

As a result, obstetric and anesthetic management in pregnancies with KTS can be very complex. Because it requires a multidisciplinary approach, follow-up and treatment in advanced centers will be appropriate. In addition, a large series of cases are needed to establish a clear consensus in follow-up and treatment.

### Source of Finance

*During this study, no financial or spiritual support was received neither from any pharmaceutical company that has a direct connection with the research subject, nor from a company that provides or produces medical instruments and materials which may negatively affect the evaluation process of this study.*

### Conflict of Interest

*No conflicts of interest between the authors and / or family members of the scientific and medical committee members or members of the potential conflicts of interest, counseling, expertise, working conditions, share holding and similar situations in any firm.*

### Authorship Contributions

*All authors contributed equally while this study preparing.*

## REFERENCES

1. Wassef M, Blei F, Adams D, Alomari A, Baselga E, Berenstein A, et al. Vascular anomalies classification: recommendations from the International Society for the Study of Vascular Anomalies. *Pediatrics* 2015;136(1):e203-14.
2. Horbach SE, Lokhorst MM, Oduer CE, Middeldorp S, van der Post JA, van der Horst CM. Complications of pregnancy and labour in women with Klippel-Trénaunay syndrome: a nationwide cross-sectional study. *BJOG* 2017;124(11):1780-8.
3. Rebarber A, Roman AS, Roshan D, Blei F. Obstetric management of Klippel-Trenaunay syndrome. *Obstet Gynecol* 2004;104(5 Pt 2):1205-8.
4. Freed D, Stevens EL, Pevsner J. Somatic mosaicism in the human genome. *Genes (Basel)* 2014;5(4):1064-94.
5. Jacob AG, Driscoll DJ, Shaughnessy WJ, Stanson AW, Clay RP, Gloviczki P. Klippel-Trenaunay syndrome: spectrum and management. *Mayo Clin Proc* 1998;73(1):28-36.
6. Güngör Gündogan T, Jacquemyn Y. Klippel-trenaunay syndrome and pregnancy. *Obstet Gynecol Int* 2010;2010:706850.
7. Neubert AG, Golden MA, Rose NC. Kasabach-Merritt coagulopathy complicating Klippel-Trenaunay-Weber syndrome in pregnancy. *Obstet Gynecol* 1995;85(5 Pt 2):831-3.
8. Pollack RN, Quance DR, Shatz RM. Pregnancy complicated by the Klippel-Trenaunay syndrome. A case report. *J Reprod Med* 1995;40(3):240-2.
9. Richards DS, Cruz AC. Sonographic demonstration of widespread uterine angiomatosis in a pregnant patient with Klippel-Trenaunay-Weber syndrome. *J Ultrasound Med* 1997;16(9):631-3.
10. Koch A, Aïssi G, Gaudineau A, Sananes N, Murtada R, Favre R, et al. [Klippel-Trenaunay syndrome and pregnancy: difficult choice of delivery from a case and a review of the literature]. *J Gynecol Obstet Biol Reprod (Paris)* 2014;43(7):483-7.
11. Kocaman O, Alponat A, Aygün C, Gürbüz Y, Sarısoy HT, Celebi A, et al. Lower gastrointestinal bleeding, hematuria and splenic hemangiomas in Klippel-Trenaunay syndrome: a case report and literature review. *Turk J Gastroenterol* 2009;20(1):62-6.
12. Rotholtz N, Bun ME, Laporte M, Sandra L, Carlos P, Mezzadri N. Rectal bleeding in Klippel-Trenaunay syndrome: treatment with laparoscopic ultralow anterior resection with intersphincteric dissection. *Surg Laparosc Endosc Percutan Tech* 2009;19(5):e206-9.
13. Stein SR, Perlow JH, Sawai SK. Klippel-Trenaunay-type syndrome in pregnancy. *Obstet Gynecol Surv* 2006;61(3):194-206.