

CASE REPORT

DOI: 10.5336/caserep.2020-78197

Abdominal Cocoon Syndrome and Internal Hernia Due to Hysterectomy Operation

^{ID} Taha Furkan ERTÜRK^a, ^{ID} Turgay ŞİMŞEK^a, ^{ID} Sertaç Ata GÜLER^a,
^{ID} Alican GÜREŞİN^a, ^{ID} Sezai TARHAN^a

^aDepartment of General Surgery, Kocaeli University Faculty of Medicine, Kocaeli, TURKEY

ABSTRACT Abdominal cocoon syndrome (ACS) is a rare condition with primary and secondary forms, may cause acute or chronic intestinal obstruction as a result of encasing the abdominal organs with a fibrocollagenous membrane. It is a cause of mechanical obstruction which is hard to diagnose preoperatively. Definitive diagnosis is mostly achieved under laparotomy. Management of the treatment process becomes difficult when it is associated with other abdominal pathologies. In our case; a sixtyfive-year-old woman was operated and diagnosed with ACS and internal herniation. An anastomosis was performed by resecting intestinal loops. But an anastomotic leak was detected. The patient underwent second operation and a stoma was performed. For surgical management of ACS, we recommend avoiding forming an anastomosis when resection of intestinal loops is required. We think that forming a stoma instead of an anastomosis and early nutritional support will be the most appropriate choice in reducing the complication rates.

Keywords: Ileus; intestinal obstruction; hysterectomy; peritonitis

Abdominal cocoon syndrome (ACS) is a rare condition which is also defined by names such as sclerosing encapsulated peritonitis and primary sclerosing peritonitis. It occurs with acute or chronic intestinal obstruction as a result of a fibrocollagenous membrane covering all or a part of the small intestine.¹ The etiology of primary form is unknown. Factors such as peritoneal dialysis, ventriculoperitoneal shunt, recurrent peritonitis attacks, some medications and previous abdominal surgery are the most known causes of secondary form. It is difficult to diagnose preoperatively and it is usually diagnosed and treated during laparotomy.² The most common symptoms are nausea, vomiting, absence of defecation and abdominal distension due to intestinal obstruction.³

We want to present a case that we operated for ACS and internal herniation which we think both

were secondary to ovarian cancer surgery. Also an anastomotic leak is observed in this case.

CASE REPORT

A 65-year-old woman presented to emergency department with abdominal pain, nausea, vomiting and absence of defecation for 3 days. Prior to presentation, these complaints were recurring and regressing spontaneously. She had a total abdominal hysterectomy and bilateral salpingo-oophorectomy operation with the diagnosis of ovarian cancer and received adjuvant chemotherapy treatment two years ago. In addition, she had a total thyroidectomy operation due to multinodular goiter 30 years ago and was using levothyroxine sodium. She had no other chronic diseases. On physical examination; the abdomen was distended, she had tenderness and defense at lower

Correspondence: Taha Furkan ERTÜRK
Department of General Surgery, Kocaeli University Faculty of Medicine, Kocaeli, TURKEY
E-mail: dr.tahafurkanerturk@gmail.com



Peer review under responsibility of Türkiye Klinikleri Journal of Case Reports.

Received: 30 Jul 2020

Received in revised form: 07 Dec 2020

Accepted: 11 Jan 2021

Available online: 23 Feb 2021

2147-9291 / Copyright © 2021 by Türkiye Klinikleri. This is an open access article under the CC BY-NC-ND license (<http://creativecommons.org/licenses/by-nc-nd/4.0/>).

quadrants. In laboratory examination results; leukocyte was 6.9×10^7 /uL and C-reactive protein (CRP) was 76.5 mg/dL. Other parameters were normal. Computed tomography (CT) revealed distension of small bowels and there was a suspicion of internal herniation or small bowel volvulus at midline level (Figure 1). We decided to perform laparotomy due to acute intestinal obstruction.

A fibrotic peritoneal surface was seen during laparotomy. It was observed that an encapsulated peritoneal tissue covered the small bowel loops after 250 centimeters from the treitz ligament, right colon and transverse colon mesos (Figure 2). Conglomerated small bowel and colon loops were separated from the encapsulated fibrotic peritoneal tissue (Figure 3). The fibrotic tissue was dense and surrounding all loops in a regular form. In addition to this fibrotic tissue, there were many irregular weak adhesions between the small bowel loops. Also, a transmezenteric internal

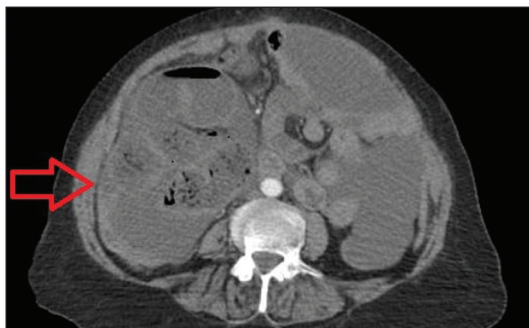


FIGURE 1: Conglomerated and dilated small bowel loops (preoperative computed tomography view).

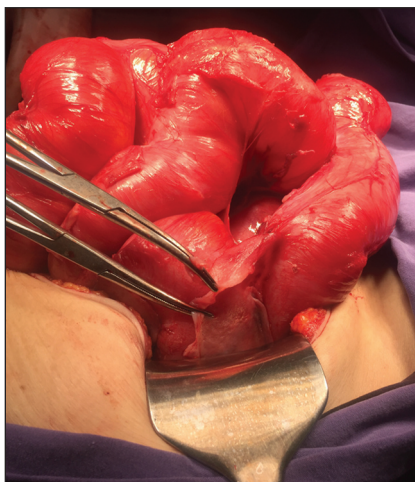


FIGURE 2: Fibrotic membrane covering small bowel loops (partially excised).

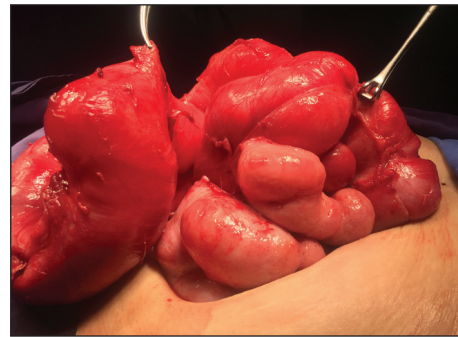


FIGURE 3: Conglomerated small bowel loops.

herniation was observed in the cavity. Approximately 80 centimeters of a small bowel part was conglomerated and had implant suspicious lesions on it. Bridectomy could not be performed for this part and right colon. So an anastomosis was performed by resecting the right colon and this small bowel part. Total parenteral nutrition (TPN) support began on the first postoperative day. Gas discharge and defecation occurred on the third day and enteral nutrition began on the 4th day. On the 6th day, intestinal contents were noticed on the drain. The patient underwent second operation and an anastomotic leak was detected. A double barrel stoma was performed. After the second operation, she tolerated the enteral nutrition and had no intraabdominal abscess or sepsis findings. She was discharged on the 10th day after the first operation.

In histopathological examination, a fibrous tissue covering the serosa of the small bowels and high-grade serous carcinoma infiltration on the serosal surfaces of the small intestine and colon was reported.

Informed consent was obtained from our patient and she signed permission to publish her story.

DISCUSSION

ACS is a rare disease with acute or chronic intestinal obstruction findings. If obstruction findings are recurrent, it should be considered in differential diagnosis. While its primary form is idiopathic, its secondary form may occur due to abdominal operations, peritoneal dialysis, ventriculoperitoneal shunt, washing the abdomen with povidine iodine, systemic lupus erythematosus, and the use of some beta-blocker drugs.⁴ In our case, ACS and internal

herniation were found together secondary to ovarian cancer operation.

Patients refer to the clinic with nonspecific symptoms such as nausea, vomiting, abdominal distension, absence of defecation. In some patients, an abdominal mass can be palpated on physical examination.⁵ Findings in imaging modalities are also generally nonspecific such as symptoms. Air-fluid levels due to obstruction can be revealed with abdominal X-ray. CT imaging is useful for diagnosis but findings may not be pathognomic. In addition to nonspecific intestinal obstruction findings on CT images, a peritoneal membrane that surrounding the intestine can be seen in some patients.⁴ A few studies which used magnetic resonance imaging (MR) for the diagnosis have been reported. In a study comparing contrast enhanced MR enterography with contrast enhanced CT images, no significant difference was found in the findings and it was stated that using MR may be appropriate in patients for whom radiation exposure or contrast use is undesirable.⁶ In our case, CT imaging was performed and no specific findings were found for ACS.

Although physical examination findings and imaging methods are evaluated together, it is obvious that it is difficult to diagnose preoperatively in many cases. Yip and Lee mentioned 4 main clinical features to assist in preoperative diagnosis.⁷ These features are; a young female patient with intestinal obstruction that could not be associated with an obvious reason, history of similar attacks which resolved spontaneously, a mass presence on abdominal palpation, distension in addition to abdominal pain and vomiting. Although ACS is generally seen in young adolescent women, it can be seen in all age groups as in our patient. Also, presence of a mass was not detected on physical examination in our case.

The definitive diagnosis is made during laparotomy in many cases. Exploration is difficult and should be done carefully due to the fibrotic tissue that covers small bowels in a capsulated form and adhesions between the small bowel loops. It is hard to separate fibrotic tissue from loops. Trying to separate fibrotic tissue can easily cause bowel wall injury and perforation.

In our case, resection and anastomosis were performed and anastomotic leak occurred. There are studies in the literature which report anastomotic leaks in such cases and recommend avoiding anastomosis formation.^{8,9} Diagnostic laparotomy and nutritional support, only excision of the capsule, resection of intestines and forming stomas are other surgical methods. If the patient has no acute abdominal signs, conservative treatment is recommended. In these patients, nasogastric decompression, TPN support and avoiding enteral feeding are recommended.^{9,10} In addition to intestinal obstruction, enterocutaneous fistula, small bowel necrosis and malnutrition are other important complications.^{3,8} ACS may rarely cause infertility in women if the fibrous sac encapsulates the fallopian tubes and blocks the fimbria movements.¹¹ In the presence of acute abdominal findings, the patient should be checked for these complications. Post-operative complication rates decreased in patients who preoperatively received TPN support.⁵ Although preoperative support is recommended, surgery may be the first option in some cases.

ACS is a rare disease with difficulty in diagnosing preoperatively. The diagnosis is mostly made during laparotomy. In particular, its secondary form may be associated with other abdominal pathologies. Apart from the difficulty of exploration, when combined with other pathologies such as internal herniation, resection may be required. Based on our case; in surgical interventions, we recommend avoiding forming an anastomosis when resection of intestinal loops is required. We think that ending the operation with a stoma and early nutritional support is the most appropriate choice to reduce complication rates.

Source of Finance

During this study, no financial or spiritual support was received neither from any pharmaceutical company that has a direct connection with the research subject, nor from a company that provides or produces medical instruments and materials which may negatively affect the evaluation process of this study.

Conflict of Interest

No conflicts of interest between the authors and / or family members of the scientific and medical committee members or members of the potential conflicts of interest, counseling, expertise, working conditions, share holding and similar situations in any firm.

Authorship Contributions

Idea/Concept: Taha Furkan Ertürk, Turgay Şimşek; **Design:** Taha Furkan Ertürk, Sertaç Ata Güler; **Control/Supervision:** Turgay Şimşek, Sertaç Ata Güler; **Data Collection and/or Processing:** Taha Furkan Ertürk, Alican Güreşin, Sezai Tarhan; **Analysis**

and/or Interpretation: Taha Furkan Ertürk, Turgay Şimşek; **Literature Review:** Taha Furkan Ertürk, Sezai Tarhan; **Writing the Article:** Taha Furkan Ertürk; **Critical Review:** Turgay Şimşek, Alican Güreşin; **Materials:** Taha Furkan Ertürk, Turgay Şimşek; **Other:** Turgay Şimşek, Taha Furkan Ertürk, Sezai Tarhan.

REFERENCES

1. Deeb LS, Mourad FH, El-Zein YR, Uthman SM. Abdominal cocoon in a man: preoperative diagnosis and literature review. *J Clin Gastroenterol.* 1998;26(2):148-50. [[Crossref](#)] [[PubMed](#)]
2. Chew MH, Sophian Hadi I, Chan G, Ong HS, Wong WK. A problem encapsulated: the rare peritoneal encapsulation syndrome. *Singapore Med J.* 2006 ;47(9):808-10. [[PubMed](#)]
3. Akbulut S, Yagmur Y, Babur M. Coexistence of abdominal cocoon, intestinal perforation and incarcerated Meckel's diverticulum in an inguinal hernia: A troublesome condition. *World J Gastrointest Surg.* 2014;6(3):51-4. [[Crossref](#)] [[PubMed](#)] [[PMC](#)]
4. Sharma D, Nair RP, Dani T, Shetty P. Abdominal cocoon-A rare cause of intestinal obstruction. *Int J Surg Case Rep.* 2013;4(11):955-7. [[Crossref](#)] [[PubMed](#)] [[PMC](#)]
5. Li N, Zhu W, Li Y, Gong J, Gu L, Li M, et al. Surgical treatment and perioperative management of idiopathic abdominal cocoon: single-center review of 65 cases. *World J Surg.* 2014;38(7):1860-7. [[Crossref](#)] [[PubMed](#)]
6. Jovani M, Baticci F, Bonifacio C, Omodei PD, Malesci A. Abdominal cocoon or idiopathic encapsulating peritoneal sclerosis: magnetic resonance imaging. *Dig Liver Dis.* 2014;46(2):192-3. [[Crossref](#)] [[PubMed](#)]
7. Yip FW, Lee SH. The abdominal cocoon. *Aust N Z J Surg.* 1992;62(8):638-42. [[Crossref](#)] [[PubMed](#)]
8. Kaplan M, Atabek NM, Salman B, Durmuş O, Abbasova A, Mustafayev X. Bir olgu nedeniyle sklerozan enkapsüle peritonit [A case report of sclerosing encapsulating peritonitis]. *Genel Tıp Derg.* 2002;12(4):147-150. [[Link](#)]
9. Kittur DS, Korpe SW, Raytch RE, Smith GW. Surgical aspects of sclerosing encapsulating peritonitis. *Arch Surg.* 1990;125(12):1626-8. [[Crossref](#)] [[PubMed](#)]
10. Çolak Ş, Bektaş H. Abdominal cocoon syndrome: A rare cause of acute abdomen syndrome. *Ulus Travma Acil Cerrahi Derg.* 2019;25(6):575-9. [[Link](#)]
11. Yu R, Ya Y, Ni X, Fan G. Imaging and treatment of idiopathic abdominal cocoon in 9 patients. *Exp Ther Med.* 2020;19(1):651-7. [[PubMed](#)] [[PMC](#)]