

# Bilobar Thyroid Agenesis: Rare Case

## Bilobar Tiroid Agenezisi: Nadir Olgu

Gökhan AKKURT,<sup>a</sup>  
 Hakan BULUŞ,<sup>a</sup>  
 Hakan ATAŞ,<sup>a</sup>  
 Alper YAVUZ,<sup>a</sup>  
 Mustafa ALİMOĞULLARI,<sup>a</sup>  
 Utku TANTOĞLU,<sup>a</sup>  
 Altan AYDIN<sup>a</sup>

<sup>a</sup>Department of Surgery,  
 Keçiören Training and Research Hospital,  
 Ankara

Geliş Tarihi/Received: 18.10.2016  
 Kabul Tarihi/Accepted: 16.12.2016

Yazışma Adresi/Correspondence:  
 Gökhan AKKURT  
 Keçiören Training and Research Hospital,  
 Department of Surgery, Ankara,  
 TURKEY/TÜRKİYE  
 drakkurt06@gmail.com

This study was presented as a poster at  
 20<sup>th</sup> National Surgical Congress'16, 13-17 April  
 2016, Antalya, Turkey.

**ABSTRACT** Bilobar thyroid agenesis is a quite rare congenital anomaly which occurs because of the defects or genetic factors, during the embryological development of thyroid tissue. Although it is usually detected incidentally, symptoms like nutrition disorders, cold and dry skin, constipation, lethargy and growth retardation in childhood may lead to diagnosis. In patients with thyroid agenesis, hypothalamic-pituitary-thyroid axis works in a different way and combination of hypothyroidism and other thyroid disorders are seen more frequently. Females are more commonly affected than males (3:1 ratio), and the cases are frequently in the form of thyroid hemiagenesis of left lobe. We present a 27 years-old female patient who has been suffering from hand tremor, sweating and lethargy since about 2 years old that detected bilobar thyroid agenesis after laboratorial and radiological workup, in this paper.

**Key Words:** Thyroid dysgenesis; abnormalities

**ÖZET** Bilobar tiroid agenezisi, tiroid dokusunun embriyolojik gelişimi esnasında meydana gelen defekt veya genetik faktörler sonucu ortaya çıkan, oldukça nadir rastlanan konjenital bir anomalidir. Genellikle tesadüfen saptanmalarına karşın çocukluk çağında beslenme zorluk, kuru ve soğuk cilt, kabızlık, uykuya meyil, büyüme gelişme geriliği gibi semptomlarla tanı konulabilir. Tiroid agenezisi tespit edilen hastalarda hipotalamus-hipofiz-tiroid aksının normalden farklı çalıştığı görülmüş, aynı zamanda hipotiroidizm ve diğer tiroid hastalıklarının birlikteliği de daha sık olarak izlenmiştir. Kadınlarda, erkeklere oranla daha fazla (3:1 oranında) görülür ve sıklıkla sol lobun hemiagenezisi şeklinde izlenmektedir. Biz bu yazımızda yaklaşık 2 yaşından itibaren ara ara ellerde titreme, terleme, uykuya meyil şikayetleri olan, tarafımızca yapılan laboratuvar ve radyolojik tetkikler neticesinde bilobar tiroid bezi agenezisi saptanan 27 yaşındaki kadın hastayı sunduk.

**Anahtar Kelimeler:** Tiroid disgenезisi; anormallikler

**Türkiye Klinikleri J Endocrin 2016;11(2):65-8**

In the ontogenetic chronological development, thyroid is the initial gland of endocrine system and abnormalities of development process are named thyroid dysgenesis. Once every 3500 live births is the prevalence of thyroid dysgenesis and consequently the cases become responsible for 85% of congenital hypothyroidism.<sup>1</sup> Thyroid dysgenesis comprise a group of clinicopathologic disorders related with atypical development of thyroid tissue that involves total thyroid agenesis (athyrosis), hypoplasia, hemiagenesis and ectopic thyroid tissue. The cases of congenital thyroid aberrations are usually in the form of unilateral hemiagenesis (including frequently the left lobe) with or without the involvement of isthmus.<sup>2</sup> The embryogenic

doi: 10.5336/endocrin.2016-53629

Copyright © 2017 by Türkiye Klinikleri

expression for bilobar thyroid agenesis with persistent isthmus is stumping. Caudal immigration of the rudimental thyroid stemming from the median thyroid anlage (thyroglossal tract) at the area of foramen caecum at 4<sup>th</sup> week of pregnancy period, in the end takes the form of isthmus and majority of lateral lobes. And the caudal pharyngeal endoderm (4<sup>th</sup> and 5<sup>th</sup> branchial pouches) forms the other parts of the lateral lobes. Ultimately this process is pursued by joining of the median and lateral parts putting the thyroid into the final butterfly form by sophisticated mechanisms.<sup>3</sup>

Bilobar thyroid agenesis is a quite rare pathology that occurs as a consequence of a defect in the development of thyroid tissue which is thought to be related to genetic and environmental causes.<sup>4</sup> It is first reported in 1866 by Handfield-Jones.<sup>5</sup> It generally emerges as hemiagenesis of the left thyroid lobe in the literature.<sup>6</sup> Thyroid agenesis is usually incidentally detected by imaging studies while investigating a patient with hormonal thyroid disorder.<sup>7</sup> It has been reported as 0,05% in the studies performed with thyroid USG.<sup>8</sup> We detected it incidentally too while investigating for the same cause.

## CASE REPORT

27 years old female patient applied to our clinic who had speech impairment, hand tremor and perspiration complaints since age 2 years. Physical examination showed speech impairment and tremor. There was no pathology in the thyroid region on physical examination. Thyroid ultrasound and thyroid function tests were requested. Free T3: 0,7 pg/ml, free T4: 0,4 ng/dl, TSH: 100,3 uIU/ml, anti TG Ab: 11 IU/ml and anti TPO Ab: 10,7 IU/ml, Ca: 8,4 mg/dl. She had a history of low academic success. There was no other family member with speech impairment. Her mother and father were not relatives. She had thyroid hormone replacement in the childhood but was using her drugs irregularly. There was no thyroid tissue on ultrasonography (Figure 1, 2). 20 minutes after Tc-99m pertechnetate injection, thyroid scintigraphy was obtained by a gamma camera equipped with a pinhole collimator. No thyroid tissue could be detected on scintigraphy (Figure 3). She was con-

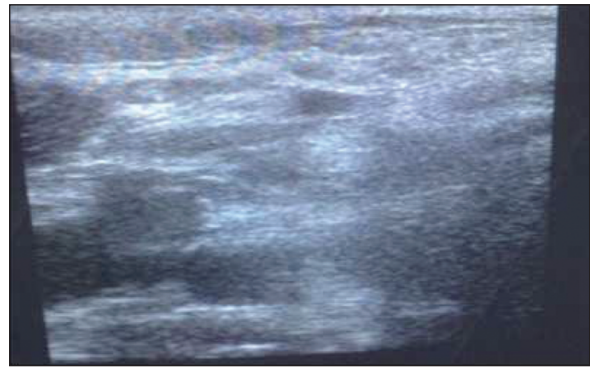


FIGURE 1: The patient's thyroid scintigraphy, bilobar thyroid agenesis (Right neck region).

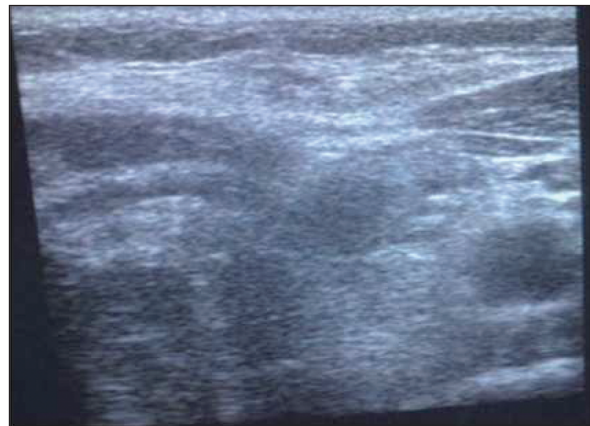


FIGURE 2: The patient's USG, bilobar thyroid agenesis (Left neck region).

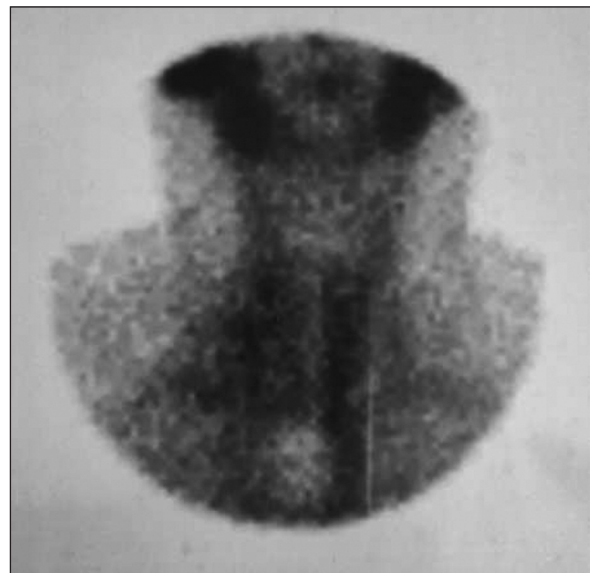


FIGURE 3: The patient's thyroid scintigraphy.

sulted to neurology. EEG, cranial MRI, blood and 24 hour urinary copper levels were requested. EEG, cranial MRI, blood and 24 hour urinary copper levels were normal. 0,15 mg levothyroxyn sodium therapy once a day orally was initiated. One month later thyroid function tests were: Free T3:3,1 pg/ml, free T4: 1,4 ng/dl, TSH= 2,3 IU/ml, anti TG ab: 10IU/ml, anti TPO ab: 10,4 IU/ml, Ca: 8,1 mg/dl. Tremor and speech impairment improved partially on follow up. She was called for a control in 3 months.

The patient's informed consent was obtained.

## DISCUSSION

Thyroid agenesis is a quite rare congenital anomaly characterized by developmental insufficiency of unilateral or bilateral thyroid lobes.<sup>9</sup> It is generally detected incidentally while evaluating for another disease. Its real incidence is not known.<sup>10</sup> In the literature patients are 3:1 predominantly women like our case.<sup>11</sup> In some cases coincidence with pathologies like ectopic parathyroid, ectopic thyroid and/or thyroglossal duct cyst may be seen.<sup>12</sup> Bilobar thyroid agenesis may be detected by nonpalpable thyroid tissue on physical examination. Diagnosis is first made by seeing no thyroid tissue on thyroid ultrasonography as it is inexpensive and it can be performed easily and then on thyroid scintigraphy.<sup>13</sup> In our case thyroid tissue could not be isolated on thyroid ultrasonography or thyroid

scintigraphy. Attipou et al. detected thyroid right lobe agenesis and adenoma on isthmus of a 27 year old female patient by imaging studies. A few years follow up showed enlargement of the adenoma so they made an isthmectomy. In the operation, exploration revealed bilobar thyroid agenesis. In this case, authors emphasized similarity between rarely seen bilobar thyroid agenesis and more frequently seen thyroid hemiagenesis.<sup>14</sup> Zhao et al. detected bilobar thyroid agenesis in a newborn child of a hospital staff who was exposed to I-131 accidentally at 10-12 weeks of pregnancy. Authors think fetal thyroid agenesis may be associated with mother's I-131 exposure during pregnancy.<sup>4</sup> Simsek et al. detected bilobar thyroid agenesis, hypertrophic isthmus, elevations of parathormon and calcium levels in a 49 years old female patient on a routine examination. Parathyroid pathology was detected at the right side on parathyroid scintigraphy and there was no thyroid tissue bilaterally on ultrasonography. Later, patient had undergone lower right parathyroidectomy. This is the first case in which bilobar thyroid agenesis is associated with parathyroid adenoma.<sup>15</sup> We presented a 27 years old patient who was diagnosed late and using her drugs irregularly.

Consequently, bilobar thyroid agenesis (a quite rare anomaly) is a congenital disease especially seen in the childhood that can leave serious sequelae if not treated.

## REFERENCES

1. Klett M. Epidemiology of congenital hypothyroidism. *Exp Clin Endocrinol Diabetes* 1997;105 Suppl 4:19-23.
2. Pintar JE. Normal development of the hypothalamic-pituitary-thyroid axis. In: Braverman LE, Utiger RD, eds. *Werner & Ingmar's The Thyroid: A Fundamental and Clinical Text*. 8th ed. Philadelphia: Lippincott Williams & Wilkins; 2000. p.7-19.
3. Gauger PG. Thyroid gland. In: Greenfield LJ, Mulholland MW, eds. *Greenfield's Surgery: Scientific Principles and Practice Editors*. 4th ed. Philadelphia: Lippincott Williams & Wilkins; 2006. p.1-62.
4. Zhao S, Chen X, Zhu G. Infant's bilobar thyroid agenesis and mother's I-131 accidental administration. *Ann Endocrinol (Paris)* 2013; 74(1):62-4.
5. Balkan F, Usluoğulları CA, Caner S. [Thyroid hemiagenesis: report of two cases and literature review]. *Gaziantep Med J* 2014;20(1):85-7.
6. Pizzini AM, Papi G, Corrado S, Carani C, Roti E. Thyroid hemiagenesis and incidentally discovered papillary thyroid cancer: case report and review of the literature. *J Endocrinol Invest* 2005;28(1):66-71.
7. Unsal G, Makay O, Kırdoğ O, Içöz G, Akyıldız M, Yetkin E. [Hemiagenesis of the thyroid: can diagnostic work-up mislead us?]. *Ege Tıp Dergisi* 2006;45(3):203-6.
8. Mikosch P, Gallowitsch HJ, Kresnik E, Molnar M, Gomez I, Lind P. Thyroid hemiagenesis in an endemic goiter area diagnosed by ultrasonography: report of sixteen patients. *Thyroid* 1999;9(11):1075-84.
9. Yıldız M, Bozkurt MK. Thyroid hemiagenesis. *J Adolesc Health* 2003;33(4):291-2.
10. Hamburger JI, Hamburger SW. Thyroidal hemiagenesis. Report of a case and comments on clinical ramification. *Arch Surg* 1970;100(3):319-20.

11. Melnick JC, Stemkowski PE. Thyroid hemiagenesis (hockey stick sign): a review of the world literature and a report four cases. *J Clin Endocrinol Metab* 1981;52(2):247-51.
12. Duh QY, Ciulla TA, Clark OH. Primary parathyroid hyperplasia associated with thyroid hemiagenesis and agenesis of isthmus. *Surgery* 1994;115(2):257-63.
13. Prakash R, Narayanan RV, Chakravarty SK. Differentiation between suppressed thyroid tissue and thyroid hemiagenesis with Tc-99m pertechnetate radionuclide angiography. *Clin Nucl Med* 1990;15(9):605-9.
14. Attipou K, Cheyrel N, Aubry K, Pech de La-clause B, Durand-Fontanier S, Valleix D, et al. [Bilobar Thyroid Agenesis]. *Ann Endocrinol (Paris)* 2000;61(6):509-11.
15. Şimşek T, Cantürk NZ, Cantürk Z, Gürbüz Y. Bilobar thyroid agenesis with primary hyperparathyroidism: report of a case. *Surg Today* 2015;45(6):787-92.