

Giant Preperitoneal Lipoma: An Unusual Case Report with Literature Review

 Zafer ŞENOL^a,  Nurhilal KIZILTOPRAK^a

^aDepartment of General Surgery, University of Health Sciences Sultan Abdülhamid Han Haydarpaşa Training and Research Hospital, İstanbul, Türkiye

ABSTRACT Lipomas are the most common and benign soft tissue neoplasms that can occur throughout the body. Intraabdominal lipomas, especially those located in the preperitoneal region, are very rarely detected. These lipomas can be manifested with discomfort or bloating, pain or palpable mass in the abdomen, and many of them can be detected incidentally during a radiological examination or surgery for a different reason. Surgical resection is necessary only in cases of pain, cosmetic reasons, rapid growth or uncertainty in the diagnosis. Lipomas such as mesentery, omentum and retroperitoneum are very rare in the abdominal cavity. The number of reported cases of parietal peritoneum is 7 so far. Lipomas can reach large volumes very rarely. In the literature, only one excessively large lipoma case was reported. In this case report, the diagnosis and treatment of a very rare giant preperitoneal lipoma detected in a female patient is presented with literature review.

Keywords: Lipoma; preperitoneal lipoma; giant lipoma; abdominal pain

Lipomas are common and well-known glandular tissue neoplasms of the whole body.¹ Although they can be seen in any part of the body, they are very rarely detected in the abdomen, especially in the preperitoneal region. Most of the lipomas are small-sized and have superficial locations in the body, therefore they infrequently cause symptoms. Surgical resection of lipomas is only necessary in cases of pain, cosmetic reasons, rapid growth, or uncertain diagnosis. Recurrence is not common for an excised lipoma.² Lipomas located in the abdominal cavity such as the mesentery, omentum, retroperitoneum and peritoneum are rarely observed.²⁻⁴ Malignant transformation is rarely detected in shoulder, back or retroperitoneal lipomas.⁵ Large volume of the preperitoneal lipoma is very rare. Primary peritoneal tumors are unusual and stem from the mesothelial or submesothelial layers of the peritoneum. In this case report, a giant lipoma located in preperitoneal area detected in a female patient who ap-

plied to our hospital with complaint of swelling in abdomen is presented with literature review.

CASE REPORT

A 53-year-old female patient applied to our outpatient clinic with complaint of abdominal bloating. The abdominal tomography revealed a smooth-edged, hypodense lesion at the anterior-superior level of the bladder, measuring 180x94x117 mm in size and -115 hu value (fat density) (Figure 1). Written informed consent was obtained from the patient for the presented study. The first vital signs of the patient were blood pressure of 110/60 mmHg, fever of 36.7°C, pulse rate of 80 beats/min, and respiratory rate of 13/min. On palpation, a suprapubic soft mass was detected in the bilateral lower quadrants of the abdomen. The patient had no pain and tenderness. Laboratory tests of the patient, white blood cell: 6,000 and C-reactive protein: 3, showed no specific findings.

Correspondence: Zafer ŞENOL

Department of General Surgery, University of Health Sciences Sultan Abdülhamid Han Haydarpaşa Training and Research Hospital, İstanbul, Türkiye

E-mail: zafersenol@yahoo.com



Peer review under responsibility of Türkiye Klinikleri Journal of Case Reports.

Received: 11 Nov 2021

Received in revised form: 05 Jan 2022

Accepted: 06 Jan 2022

Available online: 11 Jan 2022

2147-9291 / Copyright © 2022 by Türkiye Klinikleri. This is an open access article under the CC BY-NC-ND license (<http://creativecommons.org/licenses/by-nc-nd/4.0/>).

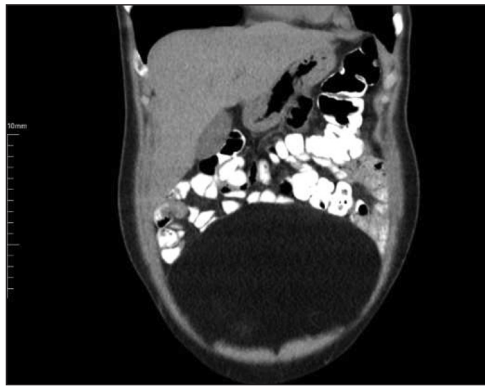


FIGURE 1: The computed tomography image of the excised preperitoneal lipoma.

Surgical treatment was decided for definitive diagnosis and relief of symptoms. In the exploration, a 20 cm diameter lipomatous soft mass was observed in the preperitoneal area just below the abdominal wall, filling the preperitoneal area superiorly from the umbilicus inferior, causing pressure to the bladder from the front, not fixed to any organ. Complete excision of the mass was performed successfully. The resected specimen revealed a fat mass measuring 21x21x7 cm. Its outer surface was in the appearance of a capsule. The pathological diagnosis of the mass was reported as a lipoma. Moreover, 7 white nodular lesions were also detected. The size of the largest of these lesions was 4.5x3.3x2.5 cm, and the size of the smallest was 1x0.5x0.4 cm. In the circular view of the section face which were evaluated as leiomyoma. MDM-2 and CDK-4 genes were investigated by fluorescence in situ hybridization technique. No amplification was detected in the MDM-2 and CDK-4 gene regions (negative). Symptoms dramatically improved after surgery. The patient was discharged on the second

postoperative day. In the follow-up of for over 6 months, the patient had no complaint and no recurrence was observed.

DISCUSSION

Lipomas are well-known and common benign tumors of mature adipose tissue surrounded by thin fibrous capsules. Symptoms of lipomas are clinically seen most frequently between the ages of 40 and 60. These lesions, which rarely cause symptoms, are usually incidentally diagnosed because of their slow growth. Little is known about the formation of the lipoma, however, there have been different possible theories about potential etiologies in the literature. The first theory about the formation of lipomas is that it develops from ectopic localized embryonic adipose tissue. As a second theory, the hyperproliferation of adipose tissue simply causes the formation of lipoma. Another theory is that trauma-induced fat herniation through tissue planes is the cause of subsequent formation of lipoma and trauma-induced cytokine release which triggers pre-adipocyte maturation and differentiation. And according to another theory, chronic stimulation, infection, and obesity may lead to development of the lipomas. Despite consisting of excessive adipose tissue growth, the relationship of the lipomas with triglycerides and cholesterol has been uncertain. The relationship of lipomas with atherosclerosis or diabetes has not also been investigated.^{6,7} Since our patient did not have trauma, infection, obesity, hypercholesterolemia, diabetes, atherosclerosis; the cause was thought to be of embryogenic origin.

TABLE 1: Literature review related to parietal peritoneum located lipomas.

Reference	Year	Patient age	Gender	Presentation	Surgical procedure	Maximum diameter (cm)
Barut et al. ⁹	2006	67	Female	Abdominal pain, nausea, vomiting	Open	6
Bunker et al. ¹⁰	2013	34	Female	Abdominal pain	Laparoscopy	-
Bang et al. ¹¹	2014	75	Male	Abdominal pain, palpable mass	Open	4.5
Shrestha and Karmacharya. ¹²	2014	32	Male	Abdominal pain, loss of appetite	Laparoscopy	3
Sathyakrishna et al. ⁵	2014	21	Female	Abdominal pain	Laparoscopy	-
Salgaonkar et al. ¹³	2016	79	Male	Abdominal pain	Laparoscopy	6.3
Choi et al. ⁸	2018	36	Male	Urinary frequency	Laparoscopy	22
Present case	2021	53	Female	Abdominal pain	Open	21

Although lipomas can be seen in any part of the body, lipomas of the abdominal cavity such as mesentery, omentum and retroperitoneal located are very rare. The number of reported cases of parietal peritoneum in the literature is seven so far (Table 1). There is only one report of excessively large lipomas in which the lipoma size is 22 cm.⁸ The size of the lipoma in our case was 21 cm and open surgical procedure was applied.

The presented case is a giant lipoma detected in the abdomen, in the preperitoneal region which has rarely been reported in the literature. In conclusion, lipomas as a rare cause of distension can be considered in the differential diagnosis.

Source of Finance

During this study, no financial or spiritual support was received neither from any pharmaceutical company that has a direct con-

nection with the research subject, nor from a company that provides or produces medical instruments and materials which may negatively affect the evaluation process of this study.

Conflict of Interest

No conflicts of interest between the authors and / or family members of the scientific and medical committee members or members of the potential conflicts of interest, counseling, expertise, working conditions, share holding and similar situations in any firm.

Authorship Contributions

Idea/Concept: Zafer Şenol; **Design:** Zafer Şenol; **Control/Supervision:** Zafer Şenol; **Data Collection and/or Processing:** Zafer Şenol, Nurhilal Kızıtoprak; **Analysis and/or Interpretation:** Zafer Şenol; **Literature Review:** Zafer Şenol, Nurhilal Kızıtoprak; **Writing the Article:** Zafer Şenol; **Critical Review:** Zafer Şenol; **References and Fundings:** Zafer Şenol; **Materials:** Zafer Şenol.

REFERENCES

1. Thompson WM, Kende AI, Levy AD. Imaging characteristics of gastric lipomas in 16 adult and pediatric patients. *AJR Am J Roentgenol.* 2003;181(4):981-5. [[Crossref](#)] [[PubMed](#)]
2. Tamura S, Yokoyama Y, Morita T, Tadokoro T, Higashidani Y, Onishi S. "Giant" colon lipoma: what kind of findings are necessary for the indication of endoscopic resection? *Am J Gastroenterol.* 2001;96(6):1944-6. [[Crossref](#)] [[PubMed](#)]
3. Singaporewalla RM, Thamboo TP, Rauff A, Cheah WK, Mukherjee JJ. Acute abdominal pain secondary to retroperitoneal bleeding from a giant adrenal lipoma with review of literature. *Asian J Surg.* 2009;32(3):172-6. [[Crossref](#)] [[PubMed](#)]
4. Wolko JD, Rosenfeld DL, Lazar MJ, Underberg-Davis SJ. Torsion of a giant mesenteric lipoma. *Pediatr Radiol.* 2003;33(1):34-6. [[Crossref](#)] [[PubMed](#)]
5. Sathyakrishna BR, Boggaram SG, Jannu NR. Twisting lipoma presenting as appendicitis-a rare presentation. *J Clin Diagn Res.* 2014; 8(8):ND07-8. [[PubMed](#)] [[PMC](#)]
6. Haller JD, Roberts TW. Lipomas of the colon: a clinicopathologic study of 20 cases. *Surgery.* 1964;55:773-81. [[PubMed](#)]
7. Signorini M, Campiglio GL. Posttraumatic lipomas: where do they really come from? *Plast Reconstr Surg.* 1998;101(3):699-705. [[Crossref](#)] [[PubMed](#)]
8. Choi H, Ryu D, Choi JW, Xu Y, Kim Y. A giant lipoma of the parietal peritoneum: Laparoscopic excision with the parietal peritoneum preserving procedure—a case report with literature review. *BMC Surg.* 2018;18(1):49. [[Crossref](#)] [[PubMed](#)] [[PMC](#)]
9. Barut I, Tarhan OR, Cerci C, Ciris M, Tasliyar E. Lipoma of the parietal peritoneum: an unusual cause of abdominal pain. *Ann Saudi Med.* 2006;26(5):388-90. [[Crossref](#)] [[PubMed](#)] [[PMC](#)]
10. Bunker DL, Ilie VG, Halder TK. Torsion of an abdominal-wall pedunculated lipoma: a rare differential diagnosis for right iliac fossa pain. *Case Rep Surg.* 2013;2013:587380. [[Crossref](#)] [[PubMed](#)] [[PMC](#)]
11. Bang CS, Kim YS, Baik GH, Han SH. A case of lipoma of parietal peritoneum causing abdominal pain. *Korean J Gastroenterol.* 2014; 63(6):369-72. [[Crossref](#)] [[PubMed](#)]
12. Shrestha BB, Karmacharya M. Torsion of a lipoma of parietal peritoneum: a rare case mimicking acute appendicitis. *J Surg Case Rep.* 2014;2014(6):rju062. [[Crossref](#)] [[PubMed](#)] [[PMC](#)]
13. Salgaonkar HP, Behera RR, Katara AN, Bhandarkar DS. Laparoscopic excision of a lipoma of parietal peritoneum. *J Minim Access Surg.* 2016;12(2):196-7. [[Crossref](#)] [[PubMed](#)] [[PMC](#)]