

# Endometriosis with Massive Hemorrhagic Ascites: Case Report

## Masif Hemorajik Assit ile Seyreden Endometriyoz

Şencan ACAR,<sup>a</sup>  
Murat AKYILDIZ,<sup>b</sup>  
Zeynep KARAALİ,<sup>c</sup>  
Şule POTUROĞLU,<sup>d</sup>  
Mehmet Burak AKTUĞLU,<sup>c</sup>  
Taner ALIOĞLU,<sup>c</sup>  
Namık YİĞİT<sup>a</sup>

<sup>a</sup>Department of Internal Medicine,  
Giresun University Faculty of Medicine,  
Giresun

<sup>b</sup>Clinic of Gastroenterology,  
Florance Nightingale Hospital,  
İstanbul  
Clinics of

<sup>c</sup>Internal Medicine,

<sup>d</sup>Gastroenterology,  
Haseki Training and Research Hospital,  
İstanbul

Geliş Tarihi/Received: 04.02.2013

Kabul Tarihi/Accepted: 27.05.2013

*This case was presented as a poster at 9.  
National Internal Medicine Congress,  
5-9 September 2007, Antalya*

Yazışma Adresi/Correspondence:  
Zeynep KARAALİ  
Haseki Training and Research Hospital,  
Clinic of Internal Medicine, İstanbul,  
TÜRKİYE/TURKEY  
zeynepkaraali@hotmail.com

**ABSTRACT** Endometriosis associated with massive, bloody ascites is an unusual occurrence. This report draws attention to this condition as a complication of endometriosis. A 50-year old, nulligravida with massive, bloody ascites and a pelvic mass underwent laparotomy, and an intraoperative laparoscopic examination ruled out malignancy. The histologic report was compatible with endometriosis. Endometriosis should be considered in the differential diagnosis of hemorrhagic ascites in premenopausal women. The physician must consider endometriosis in the differential diagnosis whenever both ascites and a pelvic mass are found in the same patient. The diagnosis always requires operative assessment and histologic confirmation.

**Key Words:** Endometriosis; ascites

**ÖZET** Masif hemorajik assit ile seyreden endometriyoz nadirdir. Bu yazıda endometriyozin bir komplikasyonu olarak bu durum anlatılmıştır. 50 yaşında nulligravida kadın hastaya masif, kanlı assit ve pelvik kitle ile uygulanan laparotomide intraoperatif laparoskopik inceleme ile malignite ekarte edilmiş, histolojik tanı endometriyoz ile uyumlu gelmiştir. Endometriozis, premenopozal kadınlarda hemorajik assit ve pelvik kitle mevcudiyetinde ayırıcı tanıda düşünülmelidir. Tanı her zaman operatif değerlendirme ve histolojik kanıt gerektirir.

**Anahtar Kelimeler:** Endometriyoz; assit

**Türkiye Klinikleri J Gastroenterohepatol 2013;20(1):24-6**

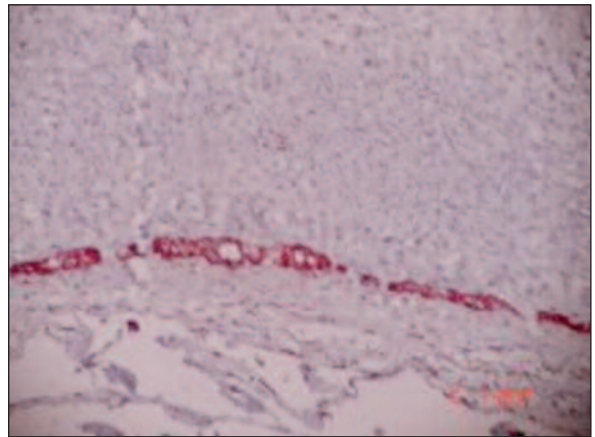
**E**ndometriosis, a major contributor to pelvic pain and subfertility, is characterized by endometrial-like tissue outside the uterus, primarily on the pelvic peritoneum, ovaries, and rectovaginal septum, and in rare cases on the diaphragm, pleura, and pericardium.<sup>1,2</sup> Its characteristic symptoms include dysmenorrhea, pelvic pain, deep dyspareunia and infertility. Moreover the gastrointestinal tract, urinary tract or other extra abdominal sites can be affected. Hence, clinical symptoms such as bloody stools, renal haemorrhage, hemoptysis and pleural effusion during menstruation may be observed in some of the patients.<sup>3</sup> Endometriosis associated with massive, bloody ascites is an unusual occurrence. Here we report 50 year-old woman presented with massive ascites as an unusual presentation of endometriosis.

## CASE REPORT

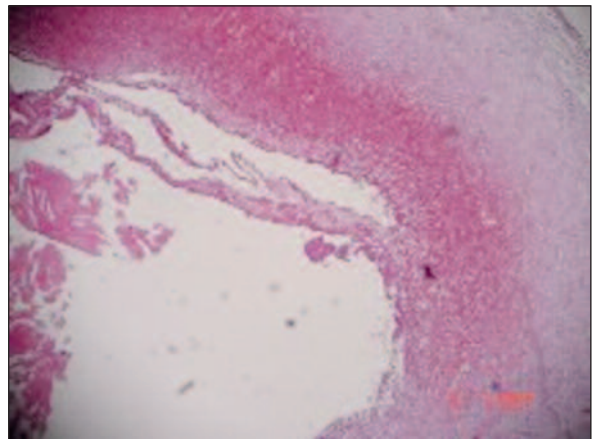
A 50 year-old woman presented with massive ascites of 2 months duration. Her past medical history was unremarkable. Physical examination was normal except tense ascites. A diagnostic paracentesis was performed. Paracentesis and cytological examination was hemorrhagic. There were no malignant cells. Laboratory tests were normal. The serum concentrations of CA 125 were normal. Despite that she did not have gynecological symptoms or significant pelvic disease. We consulted the patients with gynecologists for a probable gynecologic malignancy and/or pathology. During the gynecologic examination 0.5x0.5 cm polypoid mass in cervix was palpated. Transvaginal ultrasonography was inconclusive about the uterus and adnexial structures due to massive ascites. Ultrasound examination revealed that endometrium was thin and regular, uterus 50x25 mm. Abdominal CT showed no free fluid inside the abdomen, but revealed a 29x29x24 cm, thin walled, homogeneous, hypodens cystic lesion on the anterior wall (mesenteric cyst or enteric cyst?). Since laparotomy was planned, she was transferred to the general surgery clinic. When she was operated, it was demonstrated that the cyst included solid component in the inferior. Ten liters of brown, cystic content including echoic debris was aspirated from the cyst. During the exploration the cysts did not have any participation with any abdominal tissue, but was adhesive to the transverse colon mesothelium, left tuba and lateral peritoneum at two different loci. The cystic material was completely removed. Its pathological examination showed cystic endometriosis (Figure 1, 2). After recovery, the patient was transferred to the gynecology clinic for further follow-up.

## DISCUSSION

Endometriosis is a gynecological medical condition in which cells from the lining of the uterus appear and flourish outside the uterine cavity, most commonly on the peritoneum which lines the abdominal cavity. The uterine cavity is lined with endometrial cells, which are under the influence



**FIGURE 1:** A cystic formation with furnished cells pressed down by macrophages loaded with hemosiderin at neighborhood, HE, x40.



**FIGURE 2:** In immunohistochemically staining endometrial glandular elements (cytokeratin positive), HE, x100.

of female hormones. Endometrial-like cells in areas outside the uterus are influenced by hormonal changes and respond in a way that is similar to the cells found inside the uterus.<sup>4</sup>

Risk factors for endometriosis include obstruction of menstrual outflow, exposure to diethylstilbestrol in utero, prolonged exposure to endogenous estrogen, short menstrual cycles, low birth weight, and exposure to endocrine-disrupting chemicals.<sup>5-7</sup> Twin and family studies suggest a genetic component.<sup>8</sup> Consumption of red meat and trans fats is associated with an increased risk of laparoscopically confirmed endometriosis, and eating fruits, green vegetables, and long-chain fatty acids is associated with a decreased risk.<sup>9</sup> Prolonged

lactation and multiple pregnancies are protective.<sup>6</sup> Complications of endometriosis include internal scarring, adhesions, pelvic cysts, chocolate cyst of ovaries, ruptured cysts, and bowel and ureteral obstruction resulting from pelvic adhesions. Infertility can be related to scar formation and anatomical distortions due to the endometriosis. Peritonitis from bowel perforation can occur. Ovarian endometriosis may complicate pregnancy by decidualization, abscess and/or rupture.<sup>10</sup> Endometriosis is associated with increased risks of autoimmune diseases and ovarian endometrioid and clear-cell cancers, as well as other cancers, including non-Hodgkin's lymphoma and melanoma.<sup>1</sup>

Hemorrhagic ascites can be a complication of endometriosis. Ovarian cancer in nulliparous women of childbearing age can be diagnosed with following symptoms and findings; abdominal distention, a pelvic mass, dysmenorrhea, abdominal pain, weight loss and eventual pleural effusion.<sup>11</sup> Abdominal wall endometriosis frequently presents with noncyclical symptoms.<sup>12</sup>

Since the description of first case in 1954, endometriosis-related ascites was reported to occur in

a total of 63 women who were aged between 19 and 51 years. In this review, the CENTRAL (in the Cochrane Library), MEDLINE (Silver Platter, from 1950 to 2010), and EMBASE (from 1950 to 2010) electronic databases were searched. Key terms were identified as "endometriosis", "massive ascites" and "pleural effusion". Of the 50 subjects with known obstetric history, 41 (82.0%) were nulliparous. The serum concentrations of CA 125 were between 20 and 3,504 IU/ml for 19 women whose CA 125 levels were determined. Pleural effusion was also present in 38.1% of the reviewed subjects (24 out of 63). The clinical features of the women with endometriosis-related ascites and pleural effusion were similar to those of the women who had only endometriosis-related ascites.<sup>13</sup>

Peritoneal tuberculosis, carcinomatosis and pancreatic ascites are often considered as differential diagnosis of hemorrhagic ascites. Endometriosis can rarely present as hemorrhagic ascites and closely mimic these conditions. The physician must consider endometriosis in the differential diagnosis whenever both ascites and a pelvic mass are found in the same patient.

## REFERENCES

- Giudice LC, Swiersz LM, Burney RO. Endometriosis. In: Jameson JL, De Groot LJ, eds. *Endocrinology*. 6<sup>th</sup> ed. New York: Elsevier; 2010. p.2356-70.
- Goldstein DP, deCholnoky C, Emans SJ, Leventhal JM. Laparoscopy in the diagnosis and management of pelvic pain in adolescents. *J Reprod Med* 1980;24(6):251-6.
- Ekoukou D, Guilherme R, Desligneres S, Rotten D. [Endometriosis with massive hemorrhagic ascites: a case report and review of the literature]. *J Gynecol Obstet Biol Reprod (Paris)* 2005;34(4):351-9.
- Bulletti C, Coccia ME, Battistoni S, Borini A. Endometriosis and infertility. *J Assist Reprod Genet* 2010;27(8):441-7.
- Missmer SA, Hankinson SE, Spiegelman D, Barbieri RL, Michels KB, Hunter DJ. In utero exposures and the incidence of endometriosis. *Fertil Steril* 2004;82(6):1501-8.
- Missmer SA, Hankinson SE, Spiegelman D, Barbieri RL, Marshall LM, Hunter DJ. Incidence of laparoscopically confirmed endometriosis by demographic, anthropometric, and lifestyle factors. *Am J Epidemiol* 2004;160(8):784-96.
- Diamanti-Kandaraki E, Bourguignon JP, Giudice LC, Hauser R, Prins GS, Soto AM, et al. Endocrine-disrupting chemicals: an Endocrine Society scientific statement. *Endocr Rev* 2009;30(4):293-342.
- Montgomery GW, Nyholt DR, Zhao ZZ, Treloar SA, Painter JN, Missmer SA, et al. The search for genes contributing to endometriosis risk. *Hum Reprod Update* 2008;14(5):447-57.
- Missmer SA, Chavarro JE, Malspeis S, Bertone-Johnson ER, Hornstein MD, Spiegelman D, et al. A prospective study of dietary fat consumption and endometriosis risk. *Hum Reprod* 2010;25(6):1528-35.
- Ueda Y, Enomoto T, Miyatake T, Fujita M, Yamamoto R, Kanagawa T, et al. A retrospective analysis of ovarian endometriosis during pregnancy. *Fertil Steril* 2010;94(1):78-84.
- Hanhan M, Sipahi M, Öner RS, Tan N, Demir E, Uyar İ, et al. [Pleural endometriosis: case report]. *Turkiye Klinikleri J Gynecol Obst* 2011;21(1):58-61.
- Dias CC, Andrade JM, Ferriani RA, Villanova MG, Meirelles RS. Hemorrhagic ascites associated with endometriosis. A case report. *J Reprod Med* 2000;45(8):688-90.
- Gungor T, Kanat-Pektas M, Ozat M, Zayifoglu Karaca M. A systematic review: endometriosis presenting with ascites. *Arch Gynecol Obstet* 2011;283(3):513-8.