

Evaluation of the Relationship Between Haller Cell and Concha Bullosa with Cone Beam Computed Tomography: Cross-Sectional Study

Haller Hücresi ve Konka Bülloza Arasındaki İlişkinin Konik Işınlı Bilgisayarlı Tomografi ile Değerlendirilmesi: Kesitsel Araştırma

 Sema KAYA^a

^aVan Yüzüncü Yıl University Faculty of Dentistry, Department of Oral and Maxillofacial Radiology, Van, Türkiye

ABSTRACT Objective: The objective of this study was to determine the prevalence of concha bullosa and Haller cells in a subpopulation from the Eastern Anatolia Region, and to investigate whether there is a correlation between the presence of concha bullosa and Haller cells. **Material and Methods:** A total of 507 cone beam computed tomography images (290 females, 217 males) were retrospectively evaluated. The presence of Haller cells and concha bullosa was separately assessed for the right and left sides in frontal section images. Chi-square and Spearman correlation tests were used for the statistical analysis, with a significance level set at $p < 0.05$. **Results:** Concha bullosa was detected in 74.1% (n=215) of females and 71.4% (n=155) of males, while Haller cells were detected in 37.2% (n=108) of females and 38.2% (n=83) of males. Haller cells were present in 37% (n=191) of all participants, concha bullosa in 73% (n=370), and both Haller cells and concha bullosa in 29.2% (n=148). A high positive correlation was observed between right concha bullosa and a moderate positive correlation between left concha bullosa and both right and left Haller cells ($r: 0.503, 0.420$). **Conclusion:** There was no statistically significant correlation found between concha bullosa and Haller cells. However, the presence of concha bullosa or Haller cells on one side increased the likelihood of these formations being present on the opposite side. Cone beam computed tomography proves to be a suitable method due to its low radiation exposure and cost-effectiveness.

ÖZET Amaç: Bu çalışmanın amacı, Doğu Anadolu Bölgesi'nin bir alt popülasyonunda konka bülloza ve Haller hücrelerinin prevalansını değerlendirmektir. Ayrıca konka bülloza varlığı ile Haller hücrelerinin varlığı arasında bir korelasyon olup olmadığını bulmaktır. **Gereç ve Yöntemler:** 507 (290 kadın, 217 erkek) konik ışınlı bilgisayarlı tomografi görüntüsü retrospektif olarak değerlendirildi. Haller hücrelerinin varlığı ve konka bülloza ayrı ayrı sağ ve sol taraflar için frontal kesit görüntülerinde değerlendirildi. Verilerin istatistiksel analizi için ki-kare ve Spearman korelasyon testleri kullanıldı. **Bulgular:** Kadınların %74,1'inde (n=215) konka bülloza, %37,2'sinde (n=108) Haller hücresi; erkeklerin %71,4'ünde (n=155) konka bülloza, %38,2'sinde (n=83) Haller hücresi saptandı. Haller hücresi katılımcıların %37'sinde (n=191), konka bülloza %73'ünde (n=370) ve hem Haller hem de konka bülloza %29,2'sinde (n=148) tespit edilmiştir. Sağ konka bülloza ile sağ Haller hücreleri ve sol Haller hücreleri arasında yüksek pozitif korelasyon ve sol konka bülloza ile sağ Haller hücreleri ve sol Haller hücreleri arasında orta pozitif korelasyon gözlenmiştir ($r: 0,503, 0,420$). **Sonuç:** Konka bülloza ile Haller hücreleri arasında istatistiksel olarak anlamlı bir korelasyon bulunmamıştır. Ancak, sağ veya sol tarafta konka bülloza ve Haller hücrelerinin varlığı, karşı tarafta da bu oluşumların görülme olasılığını artırmaktadır. Konik ışınlı bilgisayarlı tomografi düşük radyasyon ve maliyeti nedeniyle çok uygun bir yöntem olarak kullanılabilir.

Keywords: Concha bullosa; cone beam computed tomography; Haller cells; turbinate

Anahtar Kelimeler: Konka bülloza; konik ışınlı bilgisayarlı tomografi; Haller hücresi; konka

TO CITE THIS ARTICLE:

Kaya S. Evaluation of the relationship between Haller cell and concha bullosa with cone beam computed tomography: Cross-sectional study. Türkiye Klinikleri J Dental Sci. 2024;30(3):406-13.

Correspondence: Sema KAYA

Van Yüzüncü Yıl University Faculty of Dentistry, Department of Oral and Maxillofacial Radiology, Van, Türkiye

E-mail: semakaya@yyu.edu.tr



Peer review under responsibility of Türkiye Klinikleri Journal of Dental Sciences.

Received: 20 Feb 2024

Received in revised form: 24 May 2024

Accepted: 15 Jun 2024

Available online: 24 Jun 2024

2146-8966 / Copyright © 2024 by Türkiye Klinikleri. This is an open access article under the CC BY-NC-ND license (<http://creativecommons.org/licenses/by-nc-nd/4.0/>).

Haller air cells, first described by Albrecht Von Haller in 1756, have become a significant area of study due to their implications in sinus pathology and maxillofacial surgery. Due to their anatomical location, Haller cells are best examined using non-invasive imaging techniques, particularly conventional sinus imaging methods and tomographic techniques.¹ Haller cells, despite being normal anatomical variations, are frequently implicated in sinus pathology. The proximity of these air cells to the ostiomeatal complex can obstruct sinus drainage, leading to recurrent sinusitis.² Furthermore, the anatomical variability and close proximity of Haller cells can pose complications during surgical interventions, such as functional endoscopic sinus surgery.³ Concha bullosa refers to a condition where partial or complete air-filled cells are found within the middle nasal turbinate, usually situated in the median concha. It constitutes one of the most frequently encountered anatomical variations within the osteomeatal region. Despite extensive research, the precise etiology of concha bullosa remains elusive. Nevertheless, it is noteworthy that these air cells are frequently co-occurring with pathologies affecting the osteomeatal complex.³ The concurrent utilization of computed tomography (CT) scans in the assessment of sinonasal diseases has contributed to an augmented detection rate of concha bullosa involving the middle turbinate. The expansion of pneumatization within the middle turbinate typically emanates from the frontal recess or the agar nasi cells.⁴

Although Haller cells and concha bullosa are anatomical variations, they hold significant clinical importance due to the potential complications they may cause. Despite their often-asymptomatic nature, they can lead to recurring sinusitis and orbital complications. Therefore, a comprehensive understanding of Haller cells is paramount, particularly in the preoperative planning of sinus and orbital surgeries. The aim of this study is to learn the prevalence of concha bullosa and Haller cells in a subpopulation of the Eastern Anatolia Region. Additionally, this study aims to investigate the potential correlation between the presence of concha bullosa and Haller cells. While many studies have examined the relationship between Haller cells and anatomical variations near

the maxillary sinus, there is a lack of extensive research on the association between the prevalence of Haller cells and concha bullosa. Therefore, we believe that this study will provide a significant addition to the current scientific knowledge on this topic.

MATERIAL AND METHODS

The study received approval from the Van Yüzüncü Yıl University Non-Interventional Clinical Research Ethics Committee (date: September 18, 2023, no: 2023/09-19). Following the principles outlined in the Declaration of Helsinki, this retrospective investigation obtained informed consent from all individuals whose data were included. In this study, a post hoc power analysis was conducted using G*power version 3.1.9.2 (Franz Faul, University of Kiel, Germany). The effect of gender on the presence of concha bullosa and Haller cells was investigated with chi-square analysis. Additionally, the relationship between the presence of Haller cells and concha bullosa was evaluated with chi-square analysis. The analysis showed that, with an alpha coefficient of 0.05, the effect of gender was studied in 507 patients with a power of 99% and a ratio of R1/R2: 0.75. The effect of the presence of Haller cells was studied in 507 patients with a power of 100% and a ratio of R1/R2: 2.3, with an alpha coefficient of 0.05. In the study, cone beam CT (CBCT) images from the archives of the department of oral and maxillofacial radiology at our faculty were utilized. In our department, informed consent forms are routinely obtained from each patient prior to the acquisition of CBCT. 507 CBCT images acquired for diagnostic purposes between January 2018 and December 2022 at the department of oral and maxillofacial radiology of our institution were retrospectively reviewed.

Inclusion criteria encompassed individuals aged between 16 and 71 years, possessing permanent dentition, and devoid of prior orthodontic or orthognathic interventions, as well as craniofacial syndromes or evident pathologies. Exclusion criteria included prior orthodontic or orthognathic procedures, impacted teeth or root displacement due to factors such as cysts or tumors in the maxillary sinuses or nasal cavity, systemic bone disorders, craniofacial abnormalities, syndromes affecting bone structure, history of trauma

or fractures in the maxillary, nasal, or ophthalmic regions, skeletally significant asymmetry, large mucus retention cysts, and CBCT images of subpar quality due to metal or motion artifacts.

EVALUATION AND OBTAINING CBCT DATA

The KaVo 3D eXam tomography device, manufactured in Biberach, Germany, and situated within the department of oral and maxillofacial radiology at our institution, was utilized for conducting CBCT measurements. This equipment undergoes routine annual maintenance and repair. All tomographic procedures were executed at settings of 120 kVp, 5 mAs, with a scan duration of 7 seconds, resulting in a voxel size of 0.4 mm and a field of view of 130 mm. The CBCT images were converted to Digital Imaging and Communications in Medicine format for analysis. The assessment for the presence of Haller cells and concha bullosa on the right and left sides in frontal sections was carried out by an oral and maxillofacial radiologist with five years of experience (Figure 1, Figure 2). The presence of Haller cells and concha bullosa

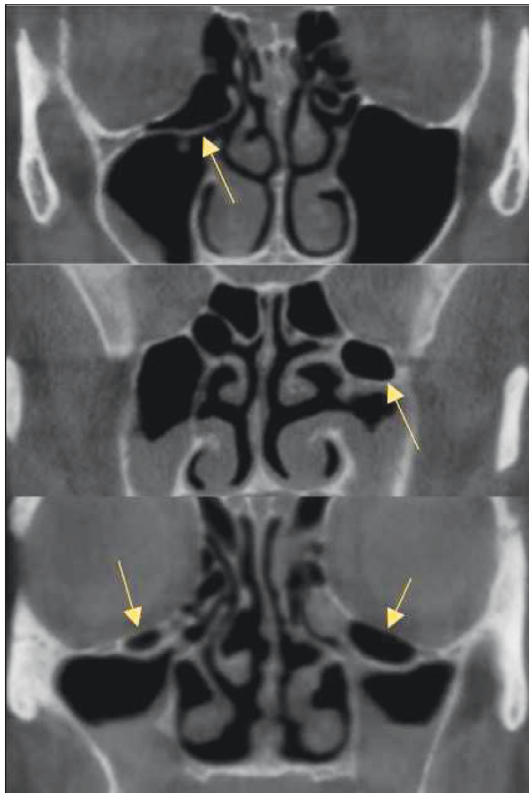


FIGURE 1: Cone beam computed tomography frontal section images of Haller cells with yellow arrow.

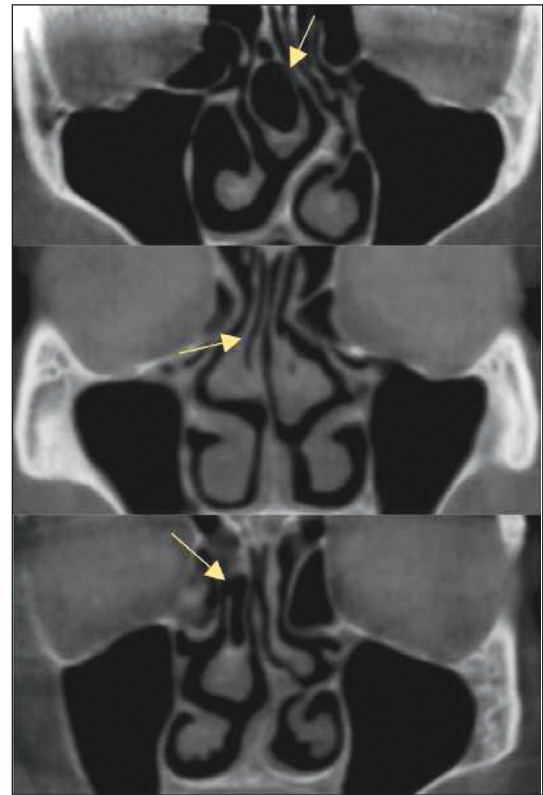


FIGURE 2: Images of concha bullosa observed in cone beam computed tomography frontal sections with yellow arrow.

was recorded separately for the right and left sides as either present or absent. However, the presence of a concha bullosa was determined based on criteria wherein pneumatization exceeding 50% of the vertical height of the middle turbinate, measured from superior to inferior in the coronal plane, was considered indicative.⁵ In this study, the characterization of Haller cells, as delineated by Simeunovic, encompasses ethmoid cells that extend towards the orbital floor or the roof of the maxillary sinus, respectively, up to the vicinity of the maxillary ostium, potentially constituting the lateral wall of the infundibulum. Cells situated within the infundibulum or formations originating from posterior ethmoid cells were not considered in our analysis [Simeunovic G. *Über die Hallersche Zelle (Cellula ethmoidalis infraorbitalis) von der Entdeckung bis zur heutigen klinischen Relevanz (PhD thesis)*. Bern: Universität, Med. Fak; 2008]. Data were analyzed to investigate the correlations according to gender, sides, and the presence of Haller cells and concha bullosa.

STATISTICAL ANALYSIS

The data were subjected to analysis using IBM SPSS Version 23 (IBM Co., Armonk, NY). Since the data did not exhibit a normal distribution according to the Kolmogorov-Smirnov test, the correlation between the data was assessed using the Spearman correlation test. The chi-square test was used for the evaluation of categorical data. A significance level of $p < 0.05$ was adopted for all analyses.

RESULTS

The mean age of the participants was calculated as 34.16 ± 12.76 years. Among the participants, 57.2% ($n=290$) were female and 42.8% ($n=217$) were male. Concha bullosa was detected in 74.1% ($n=215$) of females and 71.4% ($n=155$) of males, while Haller cell was detected in 37.2% ($n=108$) of females and 38.2% ($n=83$) of males. Both Haller cell and concha bullosa were observed in 29.2% ($n=148$) of participants (Table 1).

The presence of Haller cells and concha bullosa did not exhibit a statistically significant difference according to gender ($p=0.121$, $p=0.119$, respectively). However, a statistically significant difference was ob-

served between the presence of Haller cells and concha bullosa ($p=0.016$), a statistically significant but low correlation was observed between them ($p=0.02$, $r=0.069$). There were no statistically significant differences observed in the presence of Haller cells and concha bullosa based on directions ($p > 0.05$). Additionally, a statistically significant but moderate positive correlation was observed between the presence of Haller cells on the right and left sides simultaneously ($p < 0.001$, $r=0.420$). A statistically significant and high positive correlation was also observed between the simultaneous presence of concha bullosa on the right and left sides ($p < 0.001$, $r=0.503$). While a statistically significant difference was noted between the coexistence of Haller cells and concha bullosa on the right side ($p=0.046$), a very low correlation was observed ($r=0.079$). Conversely, no statistically significant difference was observed between the coexistence of Haller cells on the right side and concha bullosa on the left side ($p=0.158$), with a very low correlation observed ($r=0.049$). Similarly, no statistically significant difference was found between the coexistence of Haller cells on the left side and concha bullosa on the right side ($p=0.280$), and a very low correlation was observed ($r=0.031$). Finally, no statistically significant difference was found between the coexistence of Haller cells on the left side and concha bullosa on the left side ($p=0.124$), with a very low correlation observed ($r=0.056$) (Table 2).

DISCUSSION

In 88% of instances involving Haller cells, these structures were found to originate from the anterior portion of the ethmoid cells, while the remaining 12% had their origin in the posterior region.⁵ Valenzuela-Fuenzalida et al. conducted a comprehensive meta-analysis, amalgamating findings from multiple sources and reported the prevalence of Haller cells to be 30% (with a range of 18%-41%). In present study, the prevalence of Haller cells was determined to be consistent with the broader body of literature and notably exceeded the average reported prevalence.^{2,6-11} For instance, Selcuk et al. calculated a prevalence rate of 28.5% based on CT images of 330 patients from the Central Anatolia Region.¹² Tercanli Alkis et al. investigated the effect of different temperature and

TABLE 1: Table showing the distribution of concha bullosa and Haller cells according to sex.

		Gender		Total
		Female	Male	
Concha bullosa	Yes	414	294	708
	No	166	140	306
	Total	580	434	1,014
Haller cells	Yes	200	166	366
	No	380	268	648
	Total	580	434	1,014
Concha bullosa-right	Yes	215	155	370
	No	75	62	137
	Total	290	217	507
Concha bullosa-left	Yes	199	139	338
	No	91	78	169
	Total	290	217	507
Haller cells-right	Yes	108	83	191
	No	182	134	316
	Total	290	217	507
Haller cells-left	Yes	92	83	175
	No	198	134	332
	Total	290	217	507

TABLE 2: Distribution, statistics and correlation table of concha bullosa and Haller cells according to directions.

		Concha bullosa					
		Yes	No	Total	p*	r**	
Haller cell	Yes	271	95	366	0.016	0.069	
	No	437	211	648			
	Total	708	306	1014			
		Concha bullosa-right			Total	p	r
Concha Bullosa-left	Yes	300	70	370	<0.001	0.503	
	No	38	99	137			
	Total	338	169	507			
		Haller cell-left			Total	p	r
Haller cell-right	Yes	115	76	191	<0.001	0.420	
	No	60	256	316			
	Total	175	332	507			
		Concha bullosa-right			Total	p	r
Haller cell-right	Yes	148	43	191	0.046	0.079	
	No	222	94	316			
	Total	370	137	507			
		Concha bullosa-left			Total	p	r
Haller cell-left	Yes	123	52	175	0.124	0.056	
	No	215	117	332			
	Total	338	169	507			
		Concha bullosa-right			Total	p	r
Haller cell-left	Yes	131	44	175	0.280	0.031	
	No	239	93	332			
	Total	370	137	507			
		Concha bullosa-left			Total	p	r
Haller cell-right	Yes	133	58	191	0.158	0.049	
	No	205	111	316			
	Total	338	169	507			

*Chi-square analyses; **Spearman correlation test. p: 0.05

humidity levels on the occurrence of maxillary mucus retention cysts in individuals residing in two provinces of Türkiye with varying altitudes.¹³ The study did not observe a statistically significant difference. However, a low-level correlation was found between the likelihood of maxillary mucus retention cysts and air temperature and humidity levels. It was demonstrated that air temperature, different altitudes, atmospheric pressure, pollution, and humidity levels do not have a statistically significant effect on mucus retention cysts, which are pathologies of the sinonasal region. Nevertheless, the observed low correlation suggests a potential influence on anatomical variations in this region. Marcal et al. demonstrated a significant correlation between air temperature and the likelihood of mucus retention cyst occurrence.¹⁴ The

effect of air temperature and humidity levels on mucus retention cysts, which are pathologies of the sinonasal region, varies in the literature. In addition, some researchers who argue that any obstruction occurring in the nasal region can lead to changes in sinus pressure, resulting in pneumatization.¹ In light of these data, factors such as air temperature, different altitudes, atmospheric pressure, pollution, and humidity levels suggest a potential influence on anatomical variations in the sinonasal region. It is noteworthy that Haller cell prevalence rate appeared slightly elevated among individuals residing in the eastern part of Türkiye. Given that Eastern Anatolia is characterized by higher altitudes compared to Central Anatolia, a thorough investigation into whether altitude plays a role in the etiology of Haller cells

may offer valuable insights into this phenomenon. However, more comprehensive studies are needed for this purpose.

Furthermore, in a separate investigation, conducted in 2020, researchers analyzed CBCT images of 99 patients. Their study revealed a statistically significant association, wherein individuals with maxillary sinus hypoplasia exhibited a lower prevalence of Haller cells in comparison to those without hypoplasia.¹⁵

In a recent study by Moshfeghi et al., an examination of 120 CBCT images indicated a statistically significant increase in the presence of Haller cells in cases associated with orbital floor dehiscence.¹⁶ This finding lends support to the notion that a majority of Haller cells originate from the anterior region of the ethmoid cells. Collectively, the available literature underscores the significance of considering maxillofacial air cell variations, particularly within the maxillary sinus, as they play a pivotal role in the etiology of Haller cells.

Furthermore, Kaygusuz et al. conducted a CT study involving 99 patients, wherein they did not discern any statistically significant differences among the observed anatomical formations within the nasal region.⁹ Correspondingly, our study aligns with Kaygusuz et al.'s findings, revealing no statistically significant disparities between concha bullosa and Haller cells.⁹ De Cock et al. investigated the efficacy of CBCT and CT imaging methods in evaluating sinonasal anatomy and pathology. Their study demonstrated that CT imaging provides better results for pathologies involving soft tissue, such as sinonasal polyposis. Additionally, they found that CBCT imaging is more effective in evaluating normal anatomical structures and variations due to a 42% lower radiation dose compared to CT.¹⁷ Therefore, in this study, which evaluates anatomical structures such as Haller's cells and concha bullosa, both the image efficacy and the sample size support the reliability of the results.

Shams et al. and Yazdi et al. evaluated CBCT data and reported that concha bullosa does not differ by gender.^{18,19} In contrast, Budu et al. evaluated CT data from 256 individuals and reported that concha

bullosa is more frequently observed in women compared to men.²⁰ Vasegh et al. evaluated CBCT data from 385 individuals and reported that concha bullosa is more frequently observed in women compared to men.²¹ Based on the current literature, the distribution of concha bullosa varies by gender. Ahmad et al. evaluated panoramic radiographs of 233 individuals and reported that Haller's cells are more frequently observed in women compared to men.²² Shahab et al. evaluated CBCT data from 381 individuals and reported that Haller cell is more frequently observed in women compared to men.²³ These differences are suggested to stem from variations between races, ages and the diversity of evaluation criteria. However, this study also concluded that the presence of Haller's cells and concha bullosa does not show a predisposition based on gender.

Mahapatra et al. evaluated CBCT images of 200 individuals and reported that Haller's cells are more frequently observed on the right side compared to the left side.²⁴ El-Din et al. evaluated CT images of 879 individuals and reported that concha bullosa is more frequently observed on the right side compared to the left side.²⁵ In this study, consistent with the literature, both the presence of Haller's cells and concha bullosa were statistically significantly more frequently observed on the right side.

In a study conducted by Lee et al., the examination of anatomical variations and their correlations with postoperative complications was undertaken through the analysis of CT images from a cohort comprising 81 patients. In conclusion, patients with Haller cells have been observed to experience more postoperative complications compared to those with other anatomical variations in the nasal region.¹⁰ The presence of Haller cells, particularly in midface surgeries, increases the likelihood of postoperative complications compared to other anatomical variations. CBCT imaging techniques offer the ability to assess this region's anatomy with a lower radiation dose.¹⁷ Thus, identifying the presence of Haller cells can aid in preventing preoperative complications.

Likewise, in a study by Khojastepour et al. that involved the analysis of CBCT images from 120 patients, a statistically significant association was found

between the presence of Haller cells and the incidence of maxillary sinusitis.²⁶ In contrast, Capelli and Gatti, in their evaluation of CBCT images from a sample of 140 patients, did not identify any statistically significant disparities between chronic rhinosinusitis and the presence of Haller cells and concha bullosa.²⁷

Shin et al. conducted an investigation wherein they assessed the prevalence of concha bullosa and Haller cells through the examination of CT images in 31 cases of maxillary sinus fungal ball (MSFB).¹¹ Their study revealed that the prevalence of Haller cells was elevated in MSFB cases in comparison to the control group, although this increase did not attain statistical significance. However, statistically significant higher prevalence of concha bullosa has been observed in individuals with MSFB. This may suggest the potential influence of nasal region anatomical variations on the etiology of MSFB.

Gocmen et al. evaluated the effect of concha bullosa and Haller's cells on maxillary sinus inferior pneumatization. In their study, which assessed CBCT images of 300 individuals, they did not observe a statistically significant difference between maxillary sinus inferior pneumatization and concha bullosa and Haller's cells, which are variations of pneumatization.²⁸

The limitation of this study is that the correlation between concha bullosa and Haller's cells was investigated only in individuals of similar race. Conducting similar studies in different races will enable us to understand the relationship between anatomical variations observed in the sinonasal region. Furthermore, investigating the prevalence of Haller's cells in patients with maxillary deficiency, especially those

excluded from our study due to orthodontic reasons, will allow us to understand the etiological factors of these variations.

CONCLUSION

Although concha bullosa and Haller cells observed as a result of intraosseous pneumatization originate from similar etiological events, there is no statistically significant correlation in terms of their simultaneous occurrence. However, the presence of concha bullosa and Haller cells on the right or left side increases the likelihood of these formations on the opposite side. Furthermore, it was observed that the probability of encountering Haller cells and concha bullosa did not exhibit gender-based differences. Therefore, this should be taken into consideration in surgical procedures and before diagnosis. CBCT can be used as a very comfortable method due to its low radiation and cost.

Source of Finance

During this study, no financial or spiritual support was received neither from any pharmaceutical company that has a direct connection with the research subject, nor from a company that provides or produces medical instruments and materials which may negatively affect the evaluation process of this study.

Conflict of Interest

No conflicts of interest between the authors and / or family members of the scientific and medical committee members or members of the potential conflicts of interest, counseling, expertise, working conditions, share holding and similar situations in any firm.

Authorship Contributions

This study is entirely author's own work and no other author contribution.

REFERENCES

- Kantarci M, Karasen RM, Alper F, Onbas O, Okur A, Karaman A. Remarkable anatomic variations in paranasal sinus region and their clinical importance. *Eur J Radiol.* 2004;50(3):296-302. [[Crossref](#)] [[PubMed](#)]
- Smith KD, Edwards PC, Saini TS, Norton NS. The prevalence of concha bullosa and nasal septal deviation and their relationship to maxillary sinusitis by volumetric tomography. *Int J Dent.* 2010;2010:404982. [[Crossref](#)] [[PubMed](#)] [[PMC](#)]
- Unlü HH, Akyar S, Caylan R, Nalça Y. Concha bullosa. *J Otolaryngol.* 1994;23(1):23-7. [[PubMed](#)]
- Nouraei SA, Elisay AR, Dimarco A, Abdi R, Majidi H, Madani SA, et al. Variations in paranasal sinus anatomy: implications for the pathophysiology of chronic rhinosinusitis and safety of endoscopic sinus surgery. *J Otolaryngol Head Neck Surg.* 2009;38(1):32-7. [[PubMed](#)]
- Stallman JS, Lobo JN, Som PM. The incidence of concha bullosa and its relationship to nasal septal deviation and paranasal sinus disease. *AJNR Am J Neuroradiol.* 2004;25(9):1613-8. [[PubMed](#)] [[PMC](#)]
- Valenzuela-Fuenzalida JJ, Baez-Flores B, Sepúlveda RÁ, Medina CM, Pérez R, López E, et al. Anatomical variations and abnormalities of the maxillary region and clinical implications: a systematic review and metaanalysis. *Medicine (Baltimore).* 2023;102(38):e34510. [[Crossref](#)] [[PubMed](#)] [[PMC](#)]
- Avsever H, Gunduz K, Karakoç O, Akyol M, Orhan K. Incidental findings on cone-beam computed tomographic images: paranasal sinus findings and nasal septum variations. *Oral Radiol.* 2018;34(1):40-8. [[Crossref](#)] [[PubMed](#)]
- Başer E, Sarioğlu O, Arslan IB, Çukurova İ. The effect of anatomic variations and maxillary sinus volume in antrochoanal polyp formation. *Eur Arch Otorhinolaryngol.* 2020;277(4):1067-72. [[Crossref](#)] [[PubMed](#)]
- Kaygusuz A, Haksever M, Akduman D, Aslan S, Sayar Z. Sinonasal anatomical variations: their relationship with chronic rhinosinusitis and effect on the severity of disease-a computerized tomography assisted anatomical and clinical study. *Indian J Otolaryngol Head Neck Surg.* 2014;66(3):260-6. [[Crossref](#)] [[PubMed](#)] [[PMC](#)]
- Lee JW, Yoo JY, Paek SJ, Park WJ, Choi EJ, Choi MG, Kwon KH. Correlations between anatomic variations of maxillary sinus ostium and postoperative complication after sinus lifting. *J Korean Assoc Oral Maxillofac Surg.* 2016;42(5):278-83. [[Crossref](#)] [[PubMed](#)] [[PMC](#)]
- Shin JM, Baek BJ, Byun JY, Jun YJ, Lee JY. Analysis of sinonasal anatomical variations associated with maxillary sinus fungal balls. *Auris Nasus Larynx.* 2016;43(5):524-8. [[Crossref](#)] [[PubMed](#)]
- Selcuk A, Ozcan KM, Akdogan O, Bilal N, Dere H. Variations of maxillary sinus and accompanying anatomical and pathological structures. *J Craniofac Surg.* 2008;19(1):159-64. [[Crossref](#)] [[PubMed](#)]
- Tercanlı Alkis H, Kurtuldu E, Bilge NH, Yılmaz S, Bilge OM. Environmental temperature and air humidity and prevalence of maxillary sinus retention cysts: possible relationships (preliminary study). *Oral Radiol.* 2019;35(3):296-300. [[Crossref](#)] [[PubMed](#)]
- Marcal Vieira EM, de Moraes S, de Muisis CR, Borges AH, Palma VC, da Silva Basilio L, et al. Frequency of maxillary sinus mucous retention cysts in a central brazilian population. *J Dent (Shiraz).* 2015;16(3):169-74. [[PubMed](#)] [[PMC](#)]
- Dedeoğlu N, Duman SB. Clinical significance of maxillary sinus hypoplasia in dentistry: a CBCT study. *Dent Med Probl.* 2020;57(2):149-56. [[Crossref](#)] [[PubMed](#)]
- Moshfeghi M, Dehini H, Ghazizadeh Ahsaie M. Cone beam CT analysis of haller cells: prevalence and relationship with orbital floor dehiscence. *Int J Dent.* 2023;2023:5200152. [[Crossref](#)] [[PubMed](#)] [[PMC](#)]
- De Cock J, Zanca F, Canning J, Pauwels R, Hermans R. A comparative study for image quality and radiation dose of a cone beam computed tomography scanner and a multislice computed tomography scanner for paranasal sinus imaging. *Eur Radiol.* 2015;25(7):1891-900. [[Crossref](#)] [[PubMed](#)]
- Shams N, Shams B, Sajadi Z. Evaluation of the prevalence of concha bullosa in cone-beam computed tomography images. *Avicenna J Dent Res.* 2020;12(3):93-6. [[Crossref](#)]
- Yazdi AA, Moravvej Z, Mortazavi S. Concha bullosa and associated osteomeatal anatomical variations on CBCT images: The Study of Concha Bullosa and Anatomical Osteomeatal Variations. *J Dent Sch Shahid Beheshti Univ Med Sci.* 2018;39(4):115-8. [[Link](#)]
- Budu V, Schnider A, Tache MS, Bulescu I. Evaluation of ostiomeatal complex pathology related to endoscopic sinus surgery-a retrospective analysis. *Romanian J Rhinol.* 2015;5(18):95-100. [[Crossref](#)]
- Vasegh Z, Moshfeghi M, Jalali N, Amiri MJ. Prevalence and correlation of concha bullosa and nasal septal deviation with maxillary sinus mucosal thickening using cone-beam computed tomography. *J Iran Med Council.* 2023;7(1):89-98. [[Link](#)]
- Ahmad M, Khurana N, Jaber J, Sampair C, Kuba RK. Prevalence of infra-orbital ethmoid (Haller's) cells on panoramic radiographs. *Oral Surg Oral Med Oral Pathol Oral Radiol Endod.* 2006;101(5):658-61. [[Crossref](#)] [[PubMed](#)]
- Shahab S, Sarikhani S, Eslami Manouchehri M, Yazdanpanah P. Assessment of frequency and anatomical characteristics of Haller cells in cone-beam computed tomography scans of patients referring to a private oral and maxillofacial radiology clinic during 2015-2017. *J Iran Dent Assoc.* 2018;30(3):100-5. [[Crossref](#)]
- Mahapatra S, Hebbale M, Tepan M, Halli R, Singh S, Modak R. Prevalence of Haller cell and accessory maxillary ostium: a cone-beam computed tomographic study. *J Indian Acad Oral Med Radiol.* 2022;34(4):466-9. [[Crossref](#)]
- El-Din WAN, Madani GA, Fattah IOA, Mahmoud E, Essawy AS. Prevalence of the anatomical variations of concha bullosa and its relation with sinusitis among Saudi population: a computed tomography scan study. *Anat Cell Biol.* 2021;54(2):193-201. [[Crossref](#)] [[PubMed](#)] [[PMC](#)]
- Khajastepour L, Haghnegahdar A, Khosravifard N. Role of sinonasal anatomic variations in the development of maxillary sinusitis: a cone beam CT analysis. *Open Dent J.* 2017;11:367-74. [[Crossref](#)] [[PubMed](#)] [[PMC](#)]
- Capelli M, Gatti P. Radiological study of maxillary sinus using cbct: relationship between mucosal thickening and common anatomic variants in chronic rhinosinusitis. *J Clin Diagn Res.* 2016;10(11):MC07-MC10. [[Crossref](#)] [[PubMed](#)] [[PMC](#)]
- Gocmen G, Borahan MO, Aktop S, Dumlu A, Pekiner FN, Göker K. Effect of septal deviation, concha bullosa and Haller's cell on maxillary sinus's inferior pneumatization; a retrospective study. *Open Dent J.* 2015;9:282-6. [[Crossref](#)] [[PubMed](#)] [[PMC](#)]