

Re-expansion Pulmonary Edema Caused by Pleural Effusion Drainage in Late Period After Coronary Artery Bypass Surgery: Case Report

Koroner Baypas Sonrası Geç Dönemde Plevral Efüzyon Drenajından Kaynaklanan Reekspansiyon Akciğer Ödemi

Kadir Kaan ÖZSİN,^a
Faruk TOKTAŞ,^a
Umut Serhat SANRI,^a
Nail KAHRAMAN,^a
Şenol YAVUZ^a

^aClinic of Cardiovascular Surgery,
Bursa Higher Specialization
Training and Research Hospital,
Bursa

Geliş Tarihi/Received: 08.10.2016
Kabul Tarihi/Accepted: 18.01.2017

Yazışma Adresi/Correspondence:
Kadir Kaan ÖZSİN
Bursa Higher Specialization
Training and Research Hospital,
Clinic of Cardiovascular Surgery, Bursa,
TURKEY, TÜRKİYE
kaanozsın@yahoo.com

ABSTRACT Reexpansion pulmonary edema usually follows rapid reinflation of lung parenchyma which collapsed more than three days and can be fatal in up to 21% of cases. A 48-year-old man who had undergone CABG (Coronary Artery Bypass Graft) three weeks ago, admitted to our hospital with a diagnosis of left pleural effusion. He had the clinical findings of pulmonary edema, respiratory insufficiency and shock after tube thoracostomy. He was mechanically ventilated in intensive care unit. During this period, fluid restriction, inotropic agent, diuretic and oxygen support therapy were applied. The patient discharged on 7th day with a full clinical and radiological recovery. The aim of this case report was present to attention the development of re-expansion pulmonary edema which may be fatal, after tube thoracostomy in a patient with pleural effusion following coronary artery bypass surgery.

Key Words: Pulmonary edema; pleural effusion; thoracostomy; cardiopulmonary bypass

ÖZET Reekspansiyon akciğer ödemi, genellikle üç günden fazla kollabe olan akciğer parankiminin hızlı reekspansiyonu sonucu görülür ve %21'e kadar fatal seyredebilir. Üç hafta önce KABG (Koroner Arter Baypas Greft) geçiren 48 yaşındaki erkek hasta, sol plevral efüzyon tanısıyla hastanemize kabul edildi. Tüp torakostomi sonrası pulmoner ödem, solunum yetmezliği ve şok tablosu gelişti. Yoğun bakımda mekanik ventilasyona alındı. Bu süreçte sıvı kısıtlaması, inotropik ajan, diüretik ve oksijen destek tedavisi uygulandı. Hasta yedinci gün tam klinik ve radyolojik iyileşme ile taburcu edildi. Bu vakamızda KABG takiben gelişen plevral efüzyonlu hastalarda tüp torakostomi sonrasında ölümcül olabilen reekspansiyon akciğer ödeminin gelişebileceğine dikkat çekmek istedik.

Anahtar Kelimeler: Pulmoner ödem; plevral efüzyon; torakostomi; kardiyopulmoner baypas

Türkiye Klinikleri Arch Lung 2017;18(1):25-8

Reexpansion pulmonary edema (RPE) is a pulmonary edema present after rapid re-expansion of the lung collapsed for more than 3 days.¹ It is seen with a rate of 1% after pleural effusion or pneumothorax treatment and show a fatal course up to 21%.² For this reason, early diagnosis of symptoms and findings is import; otherwise insufficient or delayed treatment may result in mortality.

Our aim with the presentation of this case is to highlight that RPE should be taken into consideration during the treatment of pleural effusion which is frequently seen after coronary by-pass surgery, and to address the subject together with the literature.

CASE PRESENTATION

A 48-year-old man who had undergone triple CABG (the left internal thoracic artery to the left anterior descending coronary artery; aorto to left circumflex coronary artery and aorto to right coronary artery anastomosis with saphenous vein graft) three weeks ago in our hospital. Postoperative recovery was no problem, and the patient was discharged from the hospital on the postoperative day 6. The patient admitted to our polyclinic department with a complaint of shortness of breath on the 21st postoperative day. Physical examination showed decreased breathing sounds in the left lung. He was hospitalized upon detection of massive left pleural effusion in chest x-ray (Figure 1A). Arterial blood pressure was detected as 110/70 mmHg, pulse at 110/min, and sinus tachycardia and finger oxygen saturation at 94%. The patient was receiving beta blocker, acetylsalicylic acid, angiotensin receptor blocker and statin treatment. There were no abnormality in laboratory results.

Tube thoracostomy was performed to the monitored patient under local anesthesia through left mid-axillary zone and approximately 2000 cc sero-hemorrhagic fluid was drained. In the meanwhile, the patient was hemodynamically stable and FiO₂: 30% oxygen was administered with mask. About 1 hour after the operation, dyspnea of the patient increased and intermittent cough and tachycardia were observed. Upon 86% of finger oxygen saturation, continuous positive airway pressure (CPAP) was administered with mask. Dyspnea didn't improve and cough with secretions started. In chest x-ray (Figure 1B), consolidated zones were detected in left middle and bottom zones. The patient was diagnosed with acute pulmonary edema. Fluid restriction and diuretic treatment were initiated. Meanwhile, arterial blood gas was pH:7.20, pCO₂: 61 mmHg, pO₂: 62 mmHg and sO₂: 88%. Upon decrease in the urinary output and drop in the blood pressure of the patient within 8 hours after tube thoracostomy, the patient was intubated and inotropic support was initiated. Vast amount of pink frothy fluid was aspirated through the intubation tube. The patient was

sedated and the treatment was regulated by providing positively pressurized mechanical ventilator support, inotropic agent and bronchodilator, diuretic and colloid. As a result of these progressive clinical findings, RPE was diagnosed.

Lateral decubitus position was performed on the patient while the affected left hemithorax is on the top in order to decrease pulmonary arteriovenous shunt of the patient. Upon mechanical ventilator and pharmacological treatment, hemodynamics and blood gases of the patient were improved and no inotrope was required. Radiographic improvement was observed and thus the patient was extubated within 36 hours after the intubation. As the clinical and radiological findings became normal (Figure 1C). The patient was discharged from the hospital on the 7th day of the postoperative period.

DISCUSSION

In 1853, Pinault reported that pulmonary edema occurred in a reexpanded lung after the removal of pleural effusion.¹ RPE is a pulmonary edema occurring after rapid re-expansion of the lung collapsed for more than 3 days.¹ It is seen with a rate of 1% after pleural effusion or pneumothorax treatment and show a fatal course up to 21%.²

Risk factors may include 20-40 year-old patients, lung collapsed for 72 hours, administration of negative pressure more than 20 cmH₂O drainage and rapid lung expansion together with drainage of more than 1.5 liquid.³

RPE is highly variable and shows an unpredictable course from spontaneous remission to respiratory failure.² RPE symptoms may vary from minimal symptoms to life-threatening hypoxia, hemodynamic instability and to death. As in the case presented, in 64% of the patients clinical findings generally start within 1-2 hours after thorax drainage and assist control (AC) expansion.³ Dyspnea, chest pain, cough with or without pink bubbly phlegm, cyanosis, fever as well as rales at auscultation, nausea, vomiting, tachycardia and hypotension may be detected in the patients. Hypotension and shock developed are due to rapid ponding of

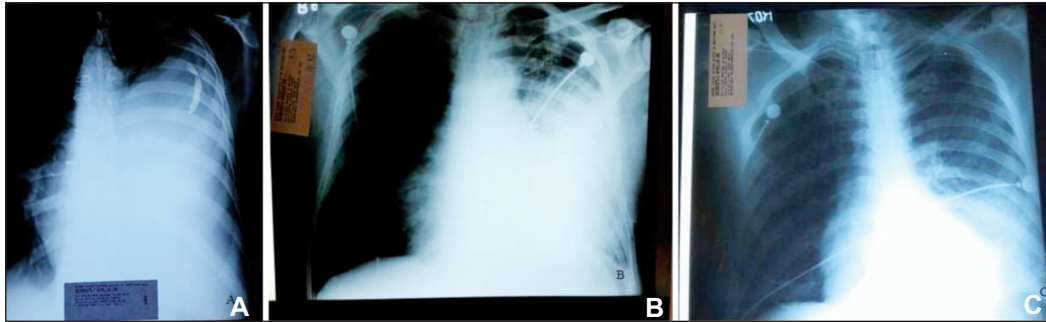


FIGURE 1: A; Massive left pleural effusion, B; Pulmonary edema after tube thoracostomy, C; Chest x-ray on day of discharge.

the fluid in thorax upon pulmonary reexpansion, pre-existing volume loss and myocardial depression developed due to drainage of pneumothorax. Radiographically, it may be unilateral, bilateral or contralateral. Radiological findings comprise of interstitial opacity, pulmonary consolidation, air bronchograms, pulmonary clefts and Kerley B line, and they are generally unilateral.² Due to clinical and radiological diversity of RPE, cardiogenic pulmonary edema, pulmonary infections and pneumonitis should be taken into consideration during differential diagnosis.²

In pathogenesis of RPE, microvascular histological changes during pulmonary collapse period and mechanical stress factors in pulmonary microvascular site during reexpansion period are held responsible.¹

Following the extended pulmonary collapse, rapid reexpansion contributes to pulmonary vascular permeability increase, decrease in surfactant and formation of free oxygen radicals. Sudden expansion leads to rapid blood flow towards this site and sudden distention in alveoli. This causes increase in pulmonary capillary pressure and hydrostatic pressure and mechanically alveolar-capillary catabolism occurs. Thus fluid and protein transport into the lung and this forms a clinical picture up to hypoxia, pulmonary edema and cardiac dysfunction.² Sudden expansion of collapsed lung initiates an inflammatory response with activation of free oxygen radicals. Together with capillary permeability increase, many factors are activated namely inflammatory mediators such as interleukin-8, leukotriene B₄ and monocyte chemotactic active

factor.³ Although RPE generally occurs in collapsed lung, it may be rarely seen in contralateral lung also.

RPE treatment is a supportive treatment. The patient must be definitely monitored and closely followed. The most important part of the oxygen support is positively-pressurized mechanical ventilation. Non-intubated patients should be provided with oxygen support using CPAP or bilevel positive airway pressure (BIPAP) and intubated patients with positive end expiratory pressure (PEEP).⁴ Lateral decubitus position is performed in a way that affected side is on the top and thus intrapulmonary shunt can be decreased and oxygen may be increased.⁴ Yücel et al. emphasized that lateral decubitus position is useful.⁵ Restriction of fluid intake, careful diuresis and addition of inotropic agents to the treatment when necessary are important. In addition, anti-inflammatory medications such as indomethacin and ibuprofen, prostaglandin analogs (misoprostol) and interleukin-8 have been detected to slow down the disease.⁴

Preventive strategies include the use of low negative pressure (< -20 cm H₂O) for suction during tube thoracostomy and limiting drainage to about 1 to 1.5 L of pleural fluid.³ Abunasser and Brown defined a thoracentesis procedure with higher volume.⁶ If the patient starts to cough during drainage, it is advised to stop the procedure. Because cough may be the first symptom of the edema formation.

While higher in coronary bypass surgery, post-operative pleural effusion is seen with a non-rare frequency in heart surgery. In many of the pa-

tients pleural effusion is generally detected after 72 hours. For this reason, RPE should be considered for patients for whom thoracentesis or tube thoracostomy are planned. As RPE may lead to a clinical picture up to cardiac dysfunction, it may show a more fatal course in patients who previously had operation due to cardiac pathology. Operation planned should be performed under intense care conditions and with monitorization. Nasal oxygen support should be provided during drainage. No more than 1500 ml liquid should be drained at once; procedure should be stopped if thoracentesis is performed and we should clamp the drainage tube during tube thoracostomy. In case of cough and dyspnea, the procedure should also

be stopped. In case of RPE development, rapid diagnosis and aggressive treatment will be life saving.

Conflict of Interest

Authors declared no conflict of interest or financial support.

Authorship Contributions

Opinion/Concept: Kadir Kaan Özsin, Şenol Yavuz; **Design:** Kadir Kaan Özsin, Faruk Toktaş, Umut Serhat Sanrı; **Supervision/Consultancy:** Şenol Yavuz, Faruk Toktaş; **Data Collecting:** Nail Kahraman, Umut Serhat Sanrı, Kadir Kaan Özsin; **Analysis, Comment:** Kadir Kaan Özsin, Şenol Yavuz, Faruk Toktaş, Nail Kahraman, Umut Serhat Sanrı; **Resource Investigator:** Kadir Kaan Özsin, Nail Kahraman, Umut Serhat Sanrı; **Writing:** Kadir Kaan Özsin, Umut Serhat Sanrı, Şenol Yavuz.

REFERENCES

1. Sohara Y. Reexpansion pulmonary edema. *Ann Thorac Cardiovasc Surg* 2008;14(4):205-9.
2. Stawicki SP, Sarani B, Braslow BM. Reexpansion pulmonary edema. *OPUS 12 Scientist* 2008;2:29-31.
3. Kasmani R, Irani F, Okoli K, Mahajan V. Reexpansion pulmonary edema following thoracentesis. *CMAJ* 2010;182(18):2000-2.
4. Alqadi R, Fonseca-Valencia C, Viscusi M, Latif SR. Reexpansion pulmonary edema following thoracentesis. *RI Med J* (2013) 2013;96(9):38-40.
5. Yücel O, Erdoğan V, Kavaklı K, Genç O, Turhan K. [Reexpansion pulmonary edema: a case report]. *Turkish J Thorac Cardiovasc Surg* 2009;17(3):218-20.
6. Abunasser J, Brown R. Safety of large-volume thoracentesis. *Conn Med* 2010;74(1):23-6.