

Autogenous cancellous bone and bone marrow transplantation in the repair of bone defects

Birol GÜLMAN, Nevzat DABAK, Nedim KARAIŞMAİLOĞLU

Ondokuz Mayıs Üniversitesi Tıp Fakültesi Ortopedi ve Travmatoloji ABD, SAMSUN

This experimental study was made in 234 rats, in order to compare the effectiveness of autogenous cancellous bone grafts and bone marrow transplants in the repair of bony defects.

Three millimeter bone defects were produced in right radii of rats. In group I; bone marrow taken from upper tibial metaphys was injected into the defects. In group II; cancellous bone grafts, taken from crista iliaca were placed in the fracture region. In the control group; no grafts were used.

At the 2nd, 4th and 8th weeks after the experiment, calli from all groups were examined radiologically and histologically, densitometric values were obtained and calcium-phosphorus contents as well as alkaline phosphatase activities were determined.

In all the control weeks, radiologic, densitometric measures and the breaking load values of the grafted radii (group I and II) were found to be significantly higher than the control group ($p < 0.001$). Radiologic and histologic examinations at the eighth week showed a better fracture healing in group II compared to group I.

These results revealed that autogenous bone marrow grafting may have potential for the treatment of bony defects, but that is not more successful than cancellous bone grafting. [Turk J Med Res 1992; 10(6):293-297]

Key Words: Bone transplantation, Bone marrow transplantation

The use of bone tissue in filling the bone defects in the skeletal system is currently being extensively studied. The good osteogenic properties of autogenous cancellous bone are well appreciated and autogenous cancellous bone has been widely used to treat nonunions.

Cancellous grafts inevitably contain a large volume of hematopoietic cells, vascular elements, and fatty marrow (1). Burwell (2), demonstrated that bone grafts containing bone marrow were more osteogenic than grafts which lack bone marrow tissue. Slush grafts which consist mainly of bone marrow are very osteogenic when used in closed intramedullary nailing (3).

The presence of osteogenic precursor cells in marrow has been extensively evaluated (4,5). Bone marrow has the ability to form bone in a number of experimental situations, eg, in subcutaneous, intra mus-

cular, and enteroperitoneal areas as well as in the anterior chamber of the eye (5-8). Using diffusion chambers, Friedenstein et al. (8), have shown that, in suspensions of total marrow cells, the hematopoietic cells die following transplantation while the fibroblasts proliferate resulting in bone formation. Recently, bone marrow alone as well as bone marrow in conjunction with a preserved xenograft have been used successfully for the treatment of nonunions and bony defects (9-14).

The purpose of this study was to compare the osteogenic properties of autogenous bone marrow grafts with autogenous cancellous bone grafts in the repair of the large bone defects and to determine whether bone marrow alone could be used for the treatment of nonunions and bone defects.

MATERIALS AND METHODS

Experiments were performed on 234 Wistar rats of both sex aged 4-5 months and with a mean weight of 252.5 ± 6.7 grams. Animals were formed in three groups, each consisting 78 rats. The rats were kept in standard cages and fed with a standard laboratory diet.

Geliş Tarihi: 12.2.1992

Kabul Tarihi: 22.9.1992

Yazışma Adresi: Birol GÜLMAN

Ondokuz Mayıs Üniversitesi Tıp Fakültesi
Ortopedi ve Travmatoloji ABD, SAMSUN

Surgical Procedure

Rats were anesthetized with IP pentobarbital sodium (50 mg/Kg) and allowed to breathe spontaneously. Then the rat positioned supine, prepped and draped. Under sterile conditions, lateral incision was made over the right radius and at the junction of the middle and distal third of radius a three millimeter bone defect was produced. All bone dust was washed and wiped away.

All of the 78 rats in group I, a small puncture was made over the right upper tibial metaphysis and 0.2 ml of bone marrow was aspirated with a 18-gauge needle. A cytological smear of the marrow aspirate was also prepared and the smear stained with hematoxyline and eosin was evaluated cytologically by light microscopy. Aspirated bone marrow was injected into the bone defect. The subcutaneous tissue and skin were then closed and surgical procedure was terminated.

In group II, following the same surgical procedure, radial bone defects were filled with cancellous bone grafts taken from the right iliac crests. In the remaining 78 rats, used as the control group, the radial bone defects were left without graft.

The rats were killed with ether inhalation at either two, four or eight weeks after the initial operations. Their right forelimbs were disarticulated from shoulder joints. The soft tissues were dissected, avoiding loss of any callus.

Lateral radiographs of the disarticulated forelimbs were taken by using a hospital portable X-ray apparatus (SIEMENS). All roentgenograms were processed at the same time and conditions, and were evaluated and scored as described by Heiple, et al. (1).

Ten radii in each group were examined for the mechanical strength of the transplanted area. To estimate the beaking load; radii, free of any soft tissue, were fixed from their proximal points and different weights were applied to the distal parts, the weight in grams which caused the radius to break was taken as the breaking load value.

Calcium, phosphorus and alkaline phosphatase contents of the grafted areas were determined in an autoanalyzer (RA-XT, Technicon USA) according to Lai et al. (15).

Formalin fixed and paraffin imbedded tissue sections were stained with H and E, and evaluated by light microscopy. Newly formed tissues in the bone defects were scored according to the histologic scoring system (1).

RESULTS

Figure 1. shows the densitometric measurements of the fracture regions at the end of two, four and eight weeks.

Optical density differences between the control group and groups I&II was statistically significant at all

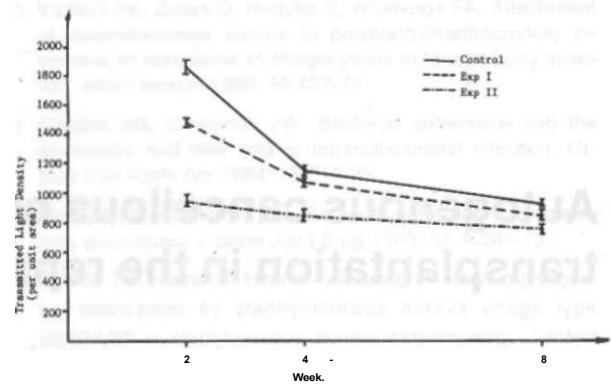


Figure 1. Changes in the transmitted light density of the operated radii.

the control weeks ($p < 0.001$). The difference in the optical density of the bone marrow grafted and cancellous bone grafted groups was also statistically significant, being higher at the second and fourth weeks ($p < 0.001$) and lower at the eighth week ($p < 0.05$).

The results of the radiological observations were in accordance with the densitometric values. Radiographically bone union was seen as early as four weeks after grating in group II (Fig 2).

At the eight week; in ten of the sixteen bone marrow grafted radii and fourteen of the sixteen cancellous bone grafted radii, the defect was radiographically bridged with bone.

Figure 3. shows breaking load values. Statistical difference of the mean breaking load for group I and group II was highly significant at the fourth week ($p < 0.001$). But this difference was not significant at the eighth week ($p > 0.05$).

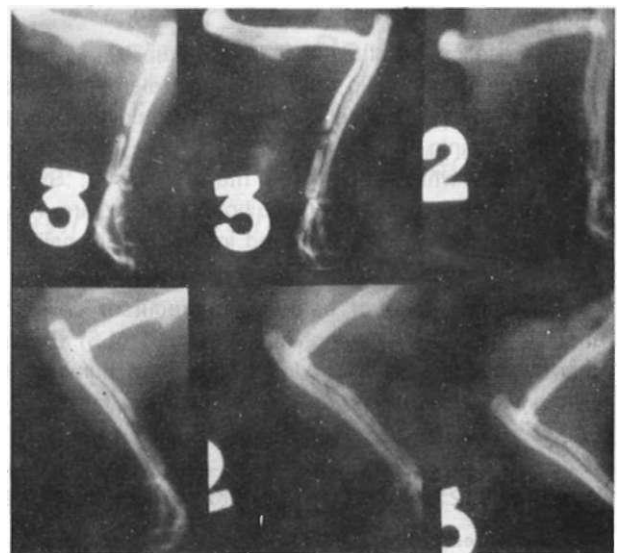


Figure 2. Radiologic view of experiment groups.

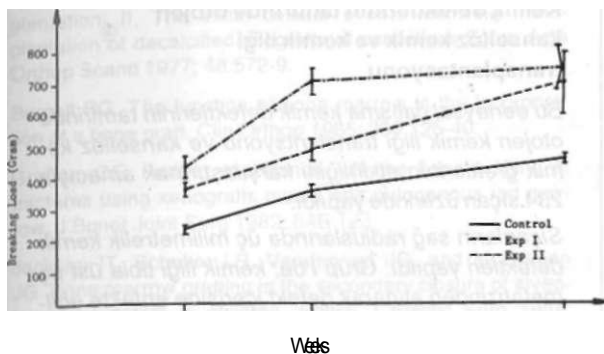


Figure 3. Changes in the breaking load of the operated radii.

Table 1. The mean calcium content in fracture areas (mg %)

Groups	Second week	Fourth week	Eighth week
Control*	2.64±0.05	2.90±0.07	2.95±0.07
Exp**	2.51 ±0.1	3.07±0.1	3.25±0.18
Exp II.***	2.70±0.1	2.90±0.3	3.51±0.13

* : 2-4 weeks, p<0.05, 4-8 weeks, p>0.05
 ** : 2-4 weeks, p<0.001, 4-8 weeks, p>0.05
 *** : 2-4 weeks, p>0.05, 4-8 weeks, p>0.05

Table 2. The mean inorganic phosphours content in fracture area (mg %)

Groups	Second week	Fourth week	Eighth week
Control*	2.53±0.28	1.80±0.07	1.17±0.07
Exp I**	2.50±0.28	1.65±0.11	1.30±0.1
Exp II.**	1.66±0.14	1.27±0.1	1.03±0.08

* : 2-4 weeks, p<0.001, 4-8 weeks, p<0.001
 ** : 2-4 weeks, p<0.001, 4-8 weeks, p<0.001
 *** : 2-4 weeks, p>0.05, 4-8 weeks, p>0.05

Table 3. Distribution of the mean alkaline phosphatase activity in fracture areas (Unit/lit)

Groups	Second week	Fourth week	Eighth week
Control*:	289.8±24.26	178.9±16.15	164.1 ±29.51
Exp I**	131.8±6.79	156.3±13.79	245.0±24.74
Exp II***	161.1 ± 16.9	144.6±10.7	137.7±18.5

2-4 weeks, p<0.001, 4-8 weeks, p>0.05
 2-4 weeks, p>0.05, 4-8 weeks, p<0.001
 2-4 weeks, p>0.005, 4-8 weeks, p>0.05

In all groups, calcium concentrations (per tissue weight) increased steadily with time. Inorganic phosphorus contents of the grafted and control radii, slightly but continuously decreased at all the control weeks.

In cancellous bone grafted and control radii, alkaline phosphatase concentrations in the newly formed bone tissue, steadily decreased at all the control weeks. On the contrary, in bone marrow grafted radii, alkaline phosphatase activities were found to be increasing with time, notably at the eight week (p<0.001).

Histologic examinations revealed that the defected radii had been filled with osteochondral callus, in two of the six (34%) bone marrow grafted and in three of the six (50%) cancellous bone grafted radii, two weeks after grafting. At the eighth week mature bony callus were seen in 16% of the group I radii, and in 34% of the group II radii (Fig 4 a, b).

DISCUSSION

Bone marrow is known to be osteogenic during the initial phase of the fracture healing (12,16,17). Densitometric values breaking loads and histologic examinations of the newly formed bone tissues in our study also confirm that osteogenic activity of the bone marrow is highest immediately after grafting. On the other hand, osteogenic properties of the cancellous bone grafts were found to be similar to the bone marrow grafts.

In the blinded qualitative analysis of the radiographs, new bone formations and bone unions were

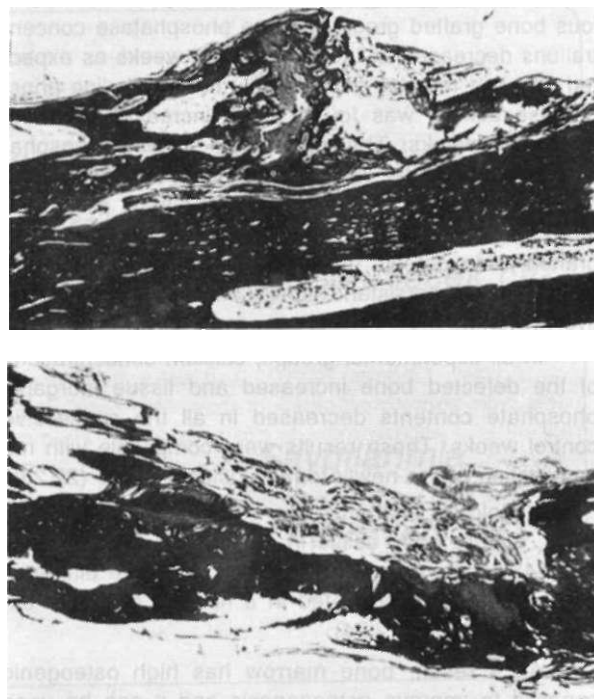


Figure 4. a. Section of bone defect in bone marrow grafted radius eight weeks after grafting. Note the complete mature osteosus bridging (HE X 25).
 b. Histologic view of cancellous bone grafted radius eight weeks after grafting, (HE X 25).

found to be significantly better in cancellous bone grafted radii than the bone marrow grafted radii at all the control weeks. This radiologic difference can be explained by the trabecular bony architecture inherent in the cancellous bone. Furthermore, densitometric evaluations of the defected radii, showed that the difference between group I and group II not to be very significant at the eighth week. These findings are in accordance with earlier studies (17-19).

Cancellous transplants tend first to be mechanically strengthened by the addition of new bone, and than, as the necrotic cores of bone are removed, the mechanical strength of transplanted areas tends to return to normal (4). In this study, at the fourth week; while breaking loads of cancellous bone grafted were higher than the bone marrow injected radii, at the eighth week, the difference between breaking loads of the two groups were no longer statistically significant. These results also show correlation with the earlier study.

Active osteoblasts and cartilage cells elaborate the enzyme alkaline phosphatase. Enzymatic activity increases from a basal level in the resting state with the initiation of osteogenic activity. As the osteoblast become engulfed by bone matrix, during its conversion to an osteocyte, its alkaline phosphatase activity decreases, ultimately reaching zero (21).

Alkaline phosphatase contents of defected radii were found to be high at the second week in cancellous bone grafted group, alkaline phosphatase concentrations decreased at the later control weeks as expected. In bone marrow grafted radii; tissue alkaline phosphatase activity was found to be increased following all control weeks. The increase in alkaline phosphatase concentrations was thought to have arisen from the osteogenicity of the bone marrow. A prolonged study to follow the enzyme activity in bone marrow grafted bone defects may be realized to illustrate and to explain the persistent high alkaline phosphatase activity.

In all experimental groups, calcium concentrations of the defected bone increased and tissue inorganic phosphate contents decreased in all the successive control weeks. These results were compatible with mineralization of the newly formed osteoid tissue (22,23).

Histologic examinations showed, at the eighth week, mature bony callus in 16% of the group I radii, and 34% of the group II radii. This objective difference had been also demonstrated in a number of earlier experimental studies (2,24).

As a result, bone marrow has high osteogenic capacity to improve osteogenesis and it can be used for the treatment of defected bones. But cancellous bone grafts, which also contain bone marrow, are more osteogenic than bone marrow alone, and therefore are a better alternative in the treatment of bone defects.

Kemik defektlerinin tamirinde otojen kansellöz kemik ve kemik iliği transplantasyonu

Bu deneysel çalışma kemik defektlerinin tamirinde otojen kemik iliği transplantasyonu ve kansellöz kemik greftlerinin etkinliğini karşılaştırmak amacıyla 234 sıçan üzerinde yapıldı.

Sıçanların sağ radiuslarında üç milimetrelik kemik defektleri yapıldı. Grup I'de; kemik iliği tibia üst uç metafizinden alınarak defekt içerisine enjekte edildi. Grup II'de; kansellöz kemik greftleri krista ilia-kadan alınarak kırık bölgesine kondu. Kontrol grubunda ise greft kullanılmadı.

Deneylerin 2., 4. ve 8. haftalarından sonra tüm gruplarda kallusun radyolojik, histolojik, densitometrik değerleri elde edildi ve alkalen fosfataz aktiviteleri olduğu gibi kalsiyum-fosfor miktarları da saptandı.

Tüm kontrol haftalarında radyolojik, densitometrik ölçümler ve kopma öncesi dayanma gücü değerleri grup I ve II'de kontrol grubundan anlamlı olarak daha yüksek bulundu ($p < 0.001$). Radyolojik ve histolojik incelemeler sekizinci haftada kırık iyileşmesinin grup II'de grup I'den daha iyi olduğunu gösterdi.

Bu sonuçlar otojen kemik iliği greftinin kemik defektlerinin tedavisinde kullanılabileceğini, ancak kansellöz kemik greftleri kadar yararlı olmayacağını göstermiştir.

[Türk Tıp Araştırma 1992; 10(6):293-297]

Anahtar Kelimeler: Kemik transplantasyonu, Kemik iliği transplantasyonu

REFERENCES

1. Heiple KG, Goldberg VM, Powell AE, Bos GD and Zika JM. Biology of cancellous bone grafts. Orthop Clin North Am 1987;2:179-96.
2. Burwell RG. Studies in the transplantation of bone. J Bone Joint Surg 1964; 46 B:110-40.
3. Chapman MW. Closed intramedullary bone grafting and nailing of segmental defects of the femur. J Bone Joint Surg 1980; 62A: 1004-8.
4. Ashton BA, Allen TD, Howlett CR, Eaglesom CC, Hattori A, Owen M. Formation of bone and cartilage by marrow stromal cells in diffusion chambers invivo. Clin Orthop 1980; 151:294-307.
5. Pfeiffer CA. Development of bone from transplanted bone marrow in mice. Anat Rec 1948; 102:225-40.
6. Budenz RW, Bernard GW. Osteogenesis and leukopoiesis with in diffusion chamber implants of isolated bone marrow subpopulations. Am J Anat 1980; 159:455-74.
7. Friedenstien AJ, Chailakhjan RK, Latsinik NV, et al. Stromal cells responsible for transferring the microenvironment of the hemopoietic tissues. Transplantation 1974; 17:331-40.

- Nade S. Osteogenesis after bone and bone marrow transplantation: II. The initial cellular events following transplantation of decalcified allografts of cancellous bone. *Acta Orthop Scand* 1977; 48:572-9.
- g Burgell RG. The function of bone marrow in the incorporation of a bone graft. *Clin Orthop* 1985; 200:125-40.
10. Graham CE. Further experience with the bone grafting of fractures using xenografts mixed with autogenous red marrow. *J Bone Joint Surg* 1982; 64B:123.
11. Jackson IT, Scheker LR, Vandervord JG, and McLennan JG. Bone marrow grafting in the secondary closure of alveolar platal defect in children. *British J Plastic Surg* 1981; 34:422-5.
12. Paley D, Young MC, Wiley AM, Fornasier VL, and Jackson RW. Percutaneous bone marrow grafting fractures and bony defects. *Clin Orthop* 1986; 208:300-12.
13. Salama R, Burwell RG, and Dickson IR. Recombined grafts of bone and marrow. *J Bone Joint Surg* 1973; 55A:402-17.
14. Salama R, Weissman SL. The clinical use of combined xenografts of bone and autologous red marrow. *J Bone Joint Surg* 1978; 60B:111-5.
15. Lai CC, Singer L, and Armstrong WD. Bone composition and phosphatase activity in magnesium deficiency in rats. *J Bone Joint Surg* 1975; 57A:516-22.
16. Urist MR. Bone morphogenetic protein induced bone formation and the bone-bone marrow consortium. In: Aebi M, Regazzoni P, ed. *Bone transplantation*. Berlin Heidelberg: Springer-Verlag, 1989:185-97.
17. Wittbjer J, Palmer B, Rahlin M, and Thorngren KG. Osteogenic activity in composite grafts of demineralized compact bone and marrow. *Clin Orthop* 1983; 173:229-38.
18. Nade S, Armstrong L, McCartney E, and Baggaley B. Osteogenesis after bone and bone marrow transplantation. *Clin Orthop* 1983; 181:255-63.
19. Thorogood PV, and Gray JG. The cellular changes during osteogenesis in bone and bone marrow composite autografts. *J Anat* 1975; 120:27-47.
20. Burchardt H. Biology of bone transplantation. *Orthop Clin North Am* 1987;2:187-9.
21. Lente FV. Alkaline and acid phosphatase determinations in bone disease. *Orthop Clin North Am* 1979; 2:437-50.
22. Kuhlman RE, Bakowski BA. The biochemical activity of fracture callus in relation to bone production. *Clin Orthop* 1975; 107:258-65.
23. Penttinen R. Biochemical studies of fracture healing in rat. *Acta Chir Scand Suppl* 1972:432.
24. Boyne PJ. Autogenous cancellous bone and marrow transplants. *Clin Orthop* 1970; 73:199-209.