

## A Rare Cause of Intestinal Obstruction: Jejunal Cavernous Hemangioma

Mustafa DÖNMEZ,<sup>a</sup>  
Murat ÖZKIRLI,<sup>a</sup>  
Murat ULUDAĞ,<sup>a</sup>  
Sadık Ahmet UYANIK<sup>b</sup>

<sup>a</sup>Clinic of General Surgery,  
29 Mayıs State Hospital,  
Ankara

<sup>b</sup>Department of Radiology,  
Okan University Faculty of Medicine,  
İstanbul

Received: 22.07.2017

Received in revised form: 25.11.2017

Accepted: 27.11.2017

Available online: 04.06.2018

Correspondence:

Mustafa DÖNMEZ  
29 Mayıs State Hospital,  
Clinic of General Surgery,  
Ankara, TURKEY  
op.dr.mustafadonmez@gmail.com

**ABSTRACT** In this report we present a 21 years old female patient who had submitted to emergency department with the complaints of abdominal pain, nausea-vomiting and constipation for last three days. After the examinations and analysis, the patient was diagnosed as ileus and the operation was decided. During the operation the presence of a mass filling nearly all of jejunal lumen was detected, than resection and anastomosis were performed. The pathology was reported as cavernous hemangioma. Postoperative seventh day the patient was discharged. It has been reported in the sources that hemangiomas are hereditary, benign, vascular pathologies that can be found in all organs and systems and are not considered as a real neoplasm. In this report we present a rare case of cavernous hemangioma of the jejunum and it is considered important due to its great dimension, rare localization and a rare clinical presentation of intestinal obstruction.

**Keywords:** Hemangioma; cavernous hemangioma; intestinal obstruction

Hemangiomas are often benign and usually present at birth. Hemangiomas are microscopically classified as capillary, cavernous and mixed type, the most commonly encountered as the cavernous type. Intestinal cavernous hemangiomas are mostly located in the upper and lower gastrointestinal levels, whereas small intestinal location is rare. The main clinical presentation of intestinal hemangiomas is gastrointestinal bleeding and another rare clinical presentations may be in the form of obstruction, intussusception, intramural hematoma, perforation and platelet sequestration. The size of cavernous hemangiomas is often less than 5 mm, the diameter rarely exceeds 1 cm, and most lesions are limited to the submucosa.<sup>1-5</sup> By means of this case, we would like to mention that cavernous hemangioma should be kept in mind for the rare reason of intestinal obstruction.

### CASE REPORT

A 21-years-old female patient was submitted into the emergency department with complaints of abdominal pain, nausea, vomiting and constipation for the last three days. The first examination of the patient revealed the presence of widespread distension and tenderness on all quadrants in the abdomen, the intestinal sounds were hypoactive, and rectum found empty on the rectal digital examination. Hemogram, biochemistry, full urinalysis, abdominal X-Ray and ultrasonography (USG) were obtained. No pathological findings were detected except for slight neutrophil dominance in the laboratory results. Air fluid levels were present in abdominal X-Ray, in USG examination enlarged intestinal segments filled with secretion were

detected and ileus was under suspicion. The patient was kept under emergency surveillance, nasogastric catheter was inserted, oral intake was stopped and iv hydration started. It was learned from the patient's background that there was no other chronic illness, no ongoing medication, and no previous surgery in the abdominal region. Although patient's complaints were found to be partially diminished and some relief in the symptoms after re-examination in surveillance room, she was admitted to general surgery service for further evaluation and treatment.

In the control examination performed later in general surgery service, it was determined that the nausea and vomiting decreased, the distension was regressed also approximately 200 cc of bilious content has come through nasogastric catheter. Along with control blood count and biochemistry assays, an abdominal computed tomography (CT) were requested. While no significant change in the laboratory results was observed, tomography revealed a long segment dilatation of 7 cm in the widest part of the jejunum and that the dilated small intestine segment was filled with fluid. Then, the patient's operation was decided with diagnosis of a small intestinal mass and associated ileus. After taking informed consent, the patient was prepared for surgery and operated on the first day of her admission. During the operation, the presence of a smooth surfaced mass with a length of about 20 cm, starting at about 160 cm from the Triethz and filling nearly all of the small intestine lumen, was detected (Figure 1). The mass was resected from the proximal and distal sides together with a solid border of approximately 10 cm and open intestinal segments were anastomosed end to end (Figure 2). The patient who did not develop any complications after the operation was allowed oral feeding on the third postoperative day and was discharged from the hospital on seventh postoperative day. The pathology of the resulting lesion was reported to be consistent with cavernous hemangioma (Figure 3).

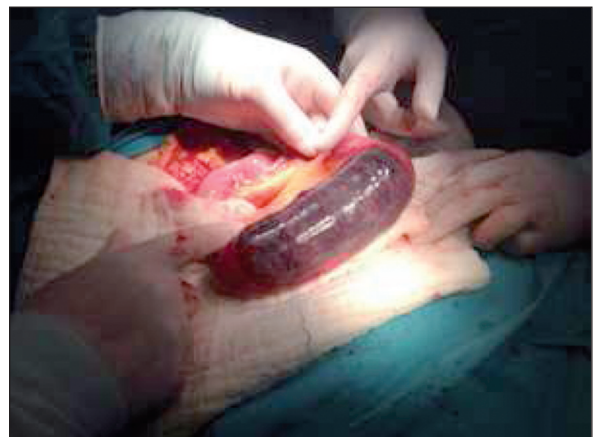## DISCUSSION

Hemangiomas are often benign, hereditary, vascular pathologies that are not real neoplasm and they

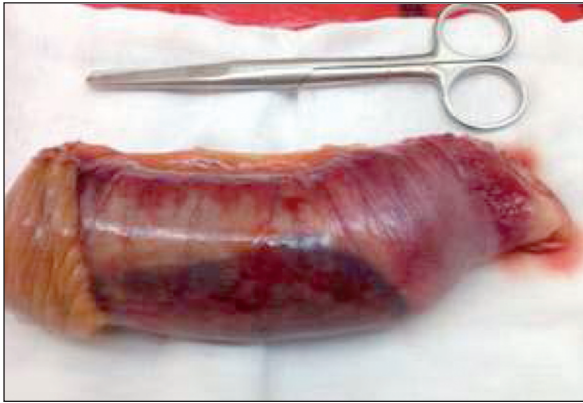are considered as hamartomatous lesions. Although they are mostly encountered in the skin, liver and spine, they may be seen in all organs and systems. They are usually present at birth.<sup>1</sup>

Hemangiomas of the gastrointestinal tract are rare, commonly located in the small intestine and most frequently in the jejunum; they constitute 0.05% of intestinal neoplasms and 7-10% of small intestine benign tumors. Intestinal hemangiomas may be solitary or multiple and they could also be a part of different syndromes such as Blue-rubber-bleb syndrome, Maffucci syndrome, Klipeltrenaunay-weber syndrome, and Peutz jegher syndrome.<sup>2</sup>

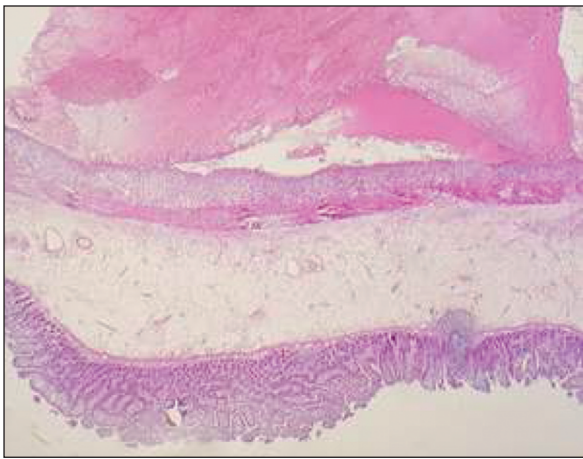
Hemangiomas are microscopically classified as capillary, cavernous and mixed type, the most commonly encountered being the cavernous type.<sup>3</sup> Cavernous hemangiomas are seen as areas surrounded by endothelial tissue filled with blood.<sup>2,4</sup> Intestinal cavernous hemangiomas are mostly located in the upper and lower gastrointestinal levels, whereas small intestinal location is rare. The main clinical presentation of intestinal hemangiomas is gastrointestinal bleeding, with cavernous hemangiomas causing more severe and acute hemorrhages, whereas capillary hemangiomas cause occult blood loss.<sup>1,2,5</sup> Other clinical presentations may be in the form of obstruction, intussusception, intramural hematoma, perforation, and platelet sequestration.<sup>3,5</sup> The size of cavernous hemangiomas is often less than



**FIGURE 1:** A smooth surfaced mass with a length of about 20 cm filling nearly all of the small intestine lumen.



**FIGURE 2:** The mass was resected from the proximal and distal sides together with a solid border of 10 cm.



**FIGURE 3:** Histologic image of the surgically resected tumor specimen.

5 mm, the diameter rarely exceeds 1 cm, and most lesions are limited to the submucosa.<sup>4</sup>

In barium studies of small and large intestines, they are detected as intraluminal masses and they

can be confused with other intestinal tumors due to their irregular boundaries and causing filling defect.<sup>4</sup> Contrast-enhanced CT, capsule endoscopy, balloon enteroscopy can also be used for diagnosis.<sup>1,5-7</sup> Treatment options include angiographic embolization, endoscopic ablation, argon plasma coagulation, and surgical resection.<sup>1,4</sup>

As a conclusion we want to emphasize that intestinal hemangiomas can be a rare cause of intestinal obstruction and accurate diagnosis is crucial to determine the best treatment approach.

#### **Source of Finance**

*During this study, no financial or spiritual support was received neither from any pharmaceutical company that has a direct connection with the research subject, nor from a company that provides or produces medical instruments and materials which may negatively affect the evaluation process of this study.*

#### **Conflict of Interest**

*No conflicts of interest between the authors and / or family members of the scientific and medical committee members or members of the potential conflicts of interest, counseling, expertise, working conditions, share holding and similar situations in any firm.*

#### **Authorship Contributions**

**Idea/Concept:** Mustafa Dönmez; **Sadık Ahmet Uyanık; Design:** Mustafa Dönmez; **Checking/Counseling:** Mustafa Dönmez, Murat Özkırlı; **Data Collection and/or Processing:** Mustafa Dönmez, Murat Özkırlı, Sadık Ahmet Uyanık; **Analysis and/or Interpretation:** Mustafa Dönmez, Murat Uludağ; **Literature Review:** Mustafa Dönmez; **Writing the Article:** Mustafa Dönmez, Sadık Ahmet Uyanık; **Critical Review:** Mustafa Dönmez, Murat Özkırlı, Murat Uludağ.

## REFERENCES

1. Huber A, Abdel Samie A, Kychenko D, Theilmann L. A rare cause of recurrent iron-deficiency anemia: cavernous hemangioma of the small intestine. *J Gastrointest Liver Dis* 2012;21(4):343.
2. Abdul Aziz DA, Khandasamy Y, Tamba RP, Zaki FM. Bleeding small bowel cavernous haemangioma following blunt trauma to the abdomen presenting as subacute intestinal obstruction in a child. *BMJ Case Reports* 2011;4:2011. Doi: 10.1136/bcr.08.2011.4672.
3. Shukri N, Amara R, Malik S, Taher H, Kilany M. Neonatal intestinal perforation-a rare complication of small bowel hemangioma. *Eur J Pediatr Surg Rep* 2013;1(1):30-1.
4. Abaylı C, Doran F, Abaylı B, İskit S. [A rare case in the terminal ileum: cavernous hemangioma]. *Cukurova Med J* 2014;39(3):594-7.
5. Fernandes D, Dionisio I, Neves S, Duarte P. Cavernous hemangioma of small bowel: a rare cause of digestive hemorrhage. *Rev Esp Enferm Dig* 2014;106(3):214-5.
6. Akazawa Y, Hiramatsu K, Nosaka T, Saito Y, Ozaki Y, Takahashi K, et al. Preoperative diagnosis of cavernous hemangioma presenting with melena using wireless capsule endoscopy of the small intestine. *Endosc Int Open* 2016;4(3):E249-51.
7. Bae SJ, Hwang G, Kang HS, Song HJ, Chang WY, Maeng YH, et al. Single cavernous hemangioma of the small bowel diagnosed by using capsule endoscopy in a child with chronic iron-deficiency anemia. *Clin Endosc* 2015;48(4):340-4.