

Autofluorescence Imaging in Eyes with Various Types of Retinal Artery Occlusion: Case Report

Farklı Tiplerde Retinal Arter Tıkanıklığı Olan Gözlerde Otofloresan Görüntüleme

Mahmut KAYA, MD,^a
Aylin YAMAN, MD,^a
Ferit Hakan ÖNER, MD,^a
Ali Osman SAATÇI, MD^a

^aDepartment of Ophthalmology,
Dokuz Eylül University,
Faculty of Medicine, Izmir

Geliş Tarihi/Received: 06.07.2009
Kabul Tarihi/Accepted: 04.08.2010

Yazışma Adresi/Correspondence:
A. Osman SAATÇI, MD
Dokuz Eylül University
Faculty of Medicine,
Department of Ophthalmology, Izmir,
TÜRKİYE/TURKEY
osman.saatci@yahoo.com

ABSTRACT We retrospectively reviewed the imaging characteristics of five patients with various types of retinal artery occlusions to elucidate the autofluorescent imaging features. In eyes with central retinal arterial occlusion (CRAO) autofluorescent imaging is not as informative as autofluorescent images obtained in eyes with branch retinal arterial occlusion (BRAO) and CRAO with foveal sparing. The border with ischemic and nonischemic portions of the posterior pole can be visualized with autofluorescent imaging techniques as good as color fundus images in eyes with BRAO and CRAO with foveal sparing. We believe that autofluorescent images might be helpful in eyes with retinal arterial occlusions.

Key Words: Retinal artery occlusion; diagnostic imaging

ÖZET Otofloresan görüntüleme özelliklerini aydınlatmak amacıyla farklı tiplerde retinal arter tıkanıklığı olan beş hastanın görüntüleme özelliklerini retrospektif olarak inceledik. Santral retinal arter tıkanıklığı (SRAT) olan gözlerde otofloresan görüntüleme retinal arter yan dalı tıkanıklığı (RAYT) olan ve foveanın korunduğu SRAT olan gözlerden elde edilen otofloresan görüntüler kadar bilgilendirici değildir. Arka kutupta iskemik ve noniskemik kısımlar arasındaki sınır, otofloresan görüntüleme teknikleri ile RAYT ve foveanın korunduğu SRAT olan gözlerdeki renkli fundus görüntülemeleri kadar iyi şekilde görülebilmektedir. Otofloresan görüntülemenin retinal arter tıkanıklığı olan gözlerde yardımcı olabileceğine inanmaktayız.

Anahtar Kelimeler: Retinal arter tıkanıklığı; tanısal görüntüleme

Türkiye Klinikleri J Med Sci 2011;31(5):1283-7

Fundus autofluorescence imaging is becoming popular as it is a noninvasive method for evaluation of intrinsic fluorescence of tissues within the eye.¹⁻⁴ Fundus autofluorescence emanates from the lipofuscin (LF) within retinal pigment epithelium (RPE).^{1,2} Intracellular lipofuscin accumulates with increasing age and excessive lipofuscin accumulation in the RPE has been considered as a marker of RPE disease and subsequent photoreceptor degeneration. LF is a complex mixture produced by the oxidative breakdown and rearrangement of different molecules including polyunsaturated fatty acids, retinoids and proteins.^{3,4}

Obstruction of the central retinal artery or its branches is a serious clinical problem and their combined incidence ranges between 0.5 and 1.5 per 1000 ophthalmic outpatient visits.^{5,6} We report the autofluorescence

findings of five patients with various types of retinal artery occlusion and discuss the characteristics of autofluorescence imaging.

SUBJECTS AND METHODS

We retrospectively reviewed the charts of five patients with various types of retinal artery occlusion who were examined in the Retina Unit of Dokuz Eylul University. Color fundus images, optical coherence tomographic (OCT) findings and autofluorescent images were carefully evaluated. Fundus autofluorescence (FAF) images were obtained with a confocal laser scanning ophthalmoscope (HRA 2, Heidelberg Engineering, Germany). A 30-degree field view mode was used; the image resolution was 512 X 512 pixels. After focusing on the macula with the red-free mode, four to six single autofluorescence images were recorded and averaged depending on the patient's fixation. Color fundus images were obtained with Visucam (Zeiss Germany) and OCT images were obtained with Heidelberg Spectralis. We do not routinely perform fluorescein angiographic examination in eyes with retinal artery occlusions as the diagnosis can easily be reached out clinically in most of the cases and color fundus pictures usually depict the affected area pretty well.

CASE REPORTS

CASE 1

A 31-year-old woman presented with a sudden painless loss of vision in her left eye for two days duration. Her personal and family history was not

contributory. On examination, visual acuity was 10/10 in both eyes. Intraocular pressure was 14mmHg OU. Examination of the right fundus was normal and there was a white, arc-shaped lesion located in the inferotemporal macula corresponding to a branch retinal artery in OS. Color fundus image, autofluorescent image and OCT image were obtained (Figure 1).

CASE 2

A 54-year-old woman with established hypertension and hyperlipidemia experienced painless visual loss in her left eye for two days' duration. Best-corrected visual acuity was hand movement OS and 9/10 OD. Ocular motility and anterior segment examinations were unremarkable and there was a left relative afferent pupillary defect. Intraocular pressures were within the normal range. The right fundus was normal and there was a retinal whitening at the left posterior pole consistent with a central retinal artery occlusion (CRAO) (Figure 2).

CASE 3

A 72-year-old woman with a long history of hypertension presented with a painless abrupt loss of vision in her left eye. Visual acuity was light perception OS and 7/10 OD. Ophthalmoscopic examination of the left eye revealed diffuse retinal whitening, arteriolar constriction and a cherry-red spot appearance. Right fundus was normal. Clinical evaluation pointed out a CRAO with partial foveal

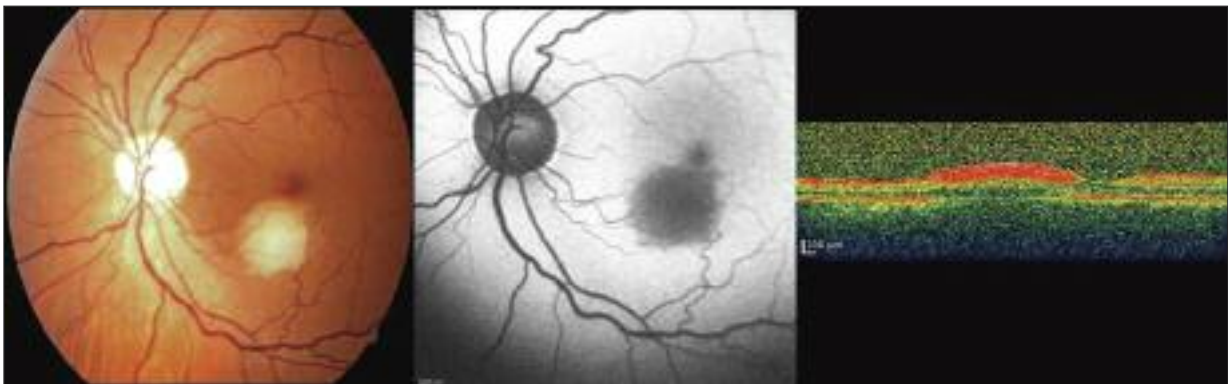

FIGURE 1. Case 1, Left eye. (Left) Color fundus image showing a tributary branch arterial obstruction. (Middle) Autofluorescent image exhibiting hypoautofluorescence corresponding to the ischemic area. (Right) OCT demonstrating increased reflectivity in the inner and decreased reflectivity in the outer retinal layer.

sparing due to a perfused minute cilioretinal artery in OS (Figure 3).

CASE 4

An otherwise healthy 50-year-old man presented with acute, painless visual loss in the left eye. Two days after the visual loss, his visual acuity was 10/10 OD and hand movement OS. The right fundus was normal and the left eye had a CRAO with partial foveal sparing due to a perfused cilioretinal artery (Figure 4).

CASE 5

A 77-year-old man presented with a sudden and painless loss of vision in his right eye. Six days after the episode, his visual acuity was 10/10 OD and 2/10 OS. There was a corneal scar due to a presumed herpetic scar in OS. Examination of the left fundus was normal and there was a whitish, arc-

shaped lesion superonasal to macula corresponding to a branch retinal artery in OD (Figure 5).

DISCUSSION

Retinal arterial obstructive diseases include ophthalmic artery obstruction, central retinal artery occlusion, branch retinal artery occlusion and cilioretinal artery occlusion.⁷

When an obstruction in the retinal artery system occurs, the area nurtured by that vessel looks opacified. The opacity results from retinal ganglion cell opacification due to severe acute ischemia. Opacification is markedly seen where there is more than one layer of ganglion cells.^{8,9} Histopathologic changes are limited to the nerve fiber and ganglion cell layer.¹⁰ There is profound loss of ganglion cells and diffuse edema inside the inner retinal layers while little change is seen in the deeper

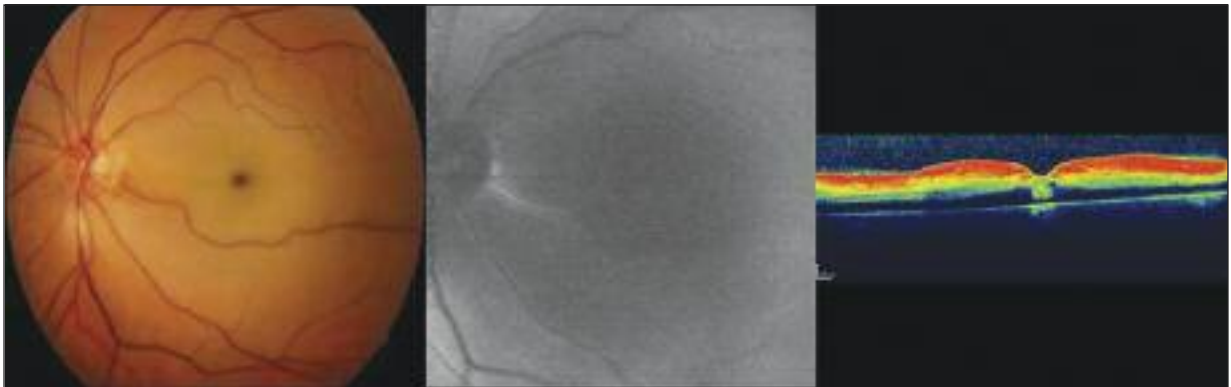


FIGURE 2: Case 2, Left eye. (Left) Color fundus image showing central retinal artery occlusion. (Middle) Autofluorescent image is not informative. (Right) OCT demonstrating increased reflectivity in the inner retina with decreased reflectivity of the outer retinal layer

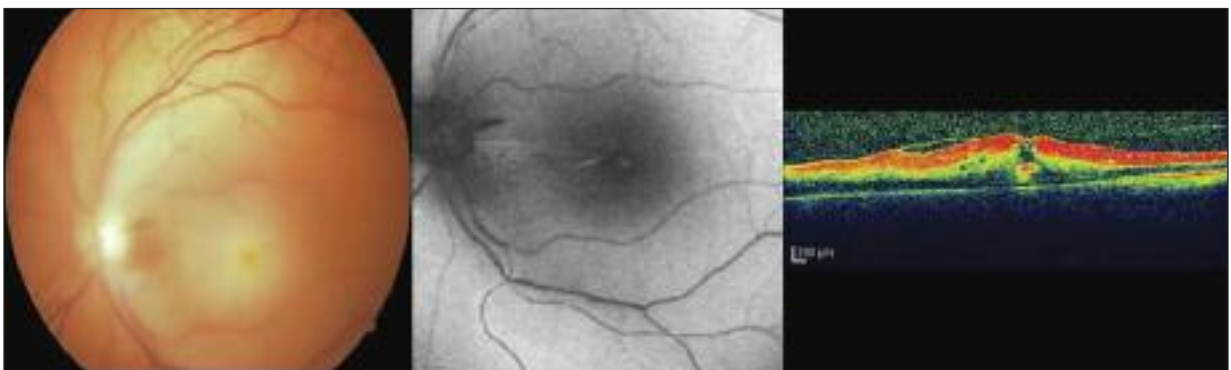


FIGURE 3: Case 3, Left eye. (Left) Color fundus image exhibits the central retinal artery occlusion. (Middle) Relatively normal looking autofluorescent image. (Right) OCT demonstrating increased reflectivity in the inner retina and decreased reflectivity of the outer retinal layer

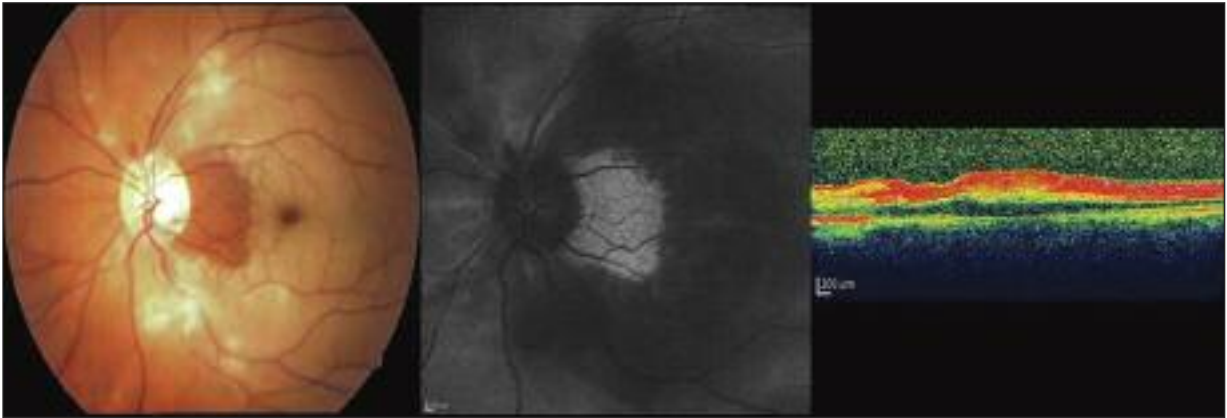


FIGURE 4: Case 4, Left eye. (Left) Color fundus image showing central retinal artery occlusion with partial sparing of the foveopapillary bundle. (Middle) Autofluorescent image markedly delineating the demarcation between ischemic and nonischemic portions of the macula. (Right) OCT demonstrating increased reflectivity in the inner retina and decreased reflectivity of the outer retinal layer.

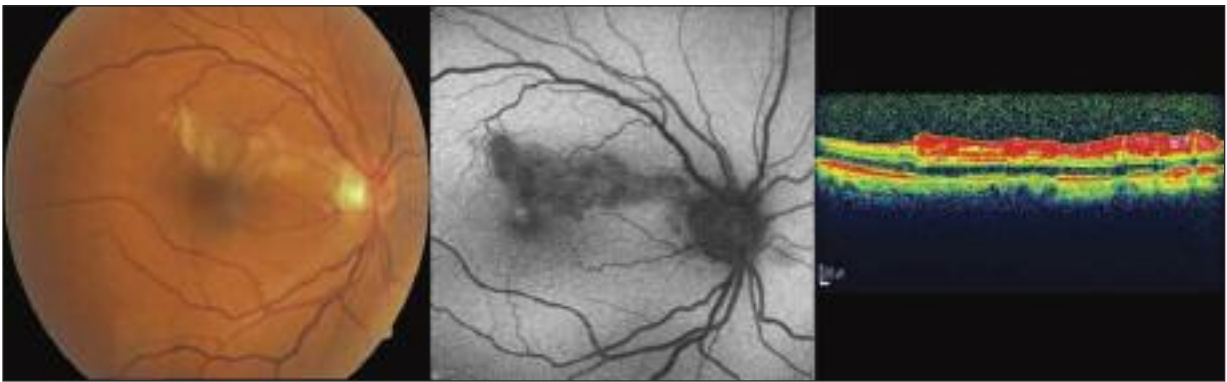


FIGURE 5: Case 5, Right eye. (Left) Color fundus image showing branch retinal artery occlusion. (Middle) Autofluorescent image demonstrating the border between ischemic and nonischemic macula. (Right) OCT findings demonstrating the ischemic retina.

retinal layers supplied by the choroidal vessels. Supportingly, OCT demonstrates increased reflectivity in the inner retina with decreased reflectivity of the outer retinal layers.^{11,12}

We have obtained autofluorescent images of patients with various types of retinal artery occlusion to see whether autofluorescent imaging techniques are useful in these cases. Our cases demonstrated that in eyes with acute CRAO, the autofluorescent images were not informative as the whole posterior pole is affected. However, in sectorial occlusions such as branch retinal artery

occlusion or CRAO with cilioretinal artery occlusion, the demarcation between the ischemic and nonischemic areas can be delineated as good as a color fundus image. The cause of hypoautofluorescence noted in areas corresponding to infarcted retinal regions is most likely due to blocking effect of edematous retina.

In light of this study, we believe that obtaining autofluorescent images with color fundus images may provide additional information to demarcate the ischemic and nonischemic areas clearly in cases with retinal arterial occlusions.

REFERENCES

1. Shields CL, Pirondini C, Bianciotto C, Materin MA, Harmon SA, Shields JA. Autofluorescence of choroidal nevus in 64 cases. *Retina* 2008;28(8):1035-43.
2. Bessho K, Gomi F, Harino S, Sawa M, Sayanagi K, Tsujikawa M, et al. Macular autofluorescence in eyes with cystoid macula edema, detected with 488 nm-excitation but not with 580 nm-excitation. *Graefes Arch Clin Exp Ophthalmol* 2009;247(6):729-34.
3. Kellner S, Kellner U, Weber BH, Fiebig B, Weinitz S, Ruether K. Lipofuscin- and melanin-related fundus autofluorescence in patients with ABCA4-associated retinal dystrophies. *Am J Ophthalmol* 2009;147(5):895-902, 902.e1.
4. Schmitz-Valckenberg S, Holz FG, Bird AC, Spaide RF. Fundus autofluorescence imaging: review and perspectives. *Retina* 2008;28(3):385-409.
5. Beatty S, Au Eong KG. Acute occlusion of the retinal arteries: current concepts and recent advances in diagnosis and management. *J Accid Emerg Med* 2000;17(5):324-9.
6. Vortmann M, Schneider JI. Acute monocular visual loss. *Emerg Med Clin North Am* 2008;26(1):73-96, vi.
7. Hayreh SS. The ophthalmic artery: III. branches. *Br J Ophthalmol* 1962;46(4):212-47.
8. Hayreh SS, Zimmerman MB. Fundus changes in central retinal artery occlusion. *Retina* 2007;27(3):276-89.
9. Hayreh SS, Zimmerman MB, Kimura A, Sannon A. Central retinal artery occlusion. *Retinal survival time. Exp Eye Res* 2004;78(3):723-36.
10. Goldenberg-Cohen N, Dadon S, Avraham BC, Kramer M, Hasanreisoglu M, Eldar I, et al. Molecular and histological changes following central retinal artery occlusion in a mouse model. *Exp Eye Res* 2008;87(4):327-33.
11. Falkenberry SM, Ip MS, Blodi BA, Gunther JB. Optical coherence tomography findings in central retinal artery occlusion. *Ophthalmic Surg Lasers Imaging* 2006;37(6):502-5.
12. Asefzadeh B, Ninyo K. Longitudinal analysis of retinal changes after branch retinal artery occlusion using optical coherence tomography. *Optometry* 2008;79(2):85-9.