

# Hyperimmunoglobulin E Syndrome: A Case Report<sup>1</sup>

## HİPERİMMUNGLOBULİN E SENDROMU: BİR OLGU SUNUMU

Mukaddes KAVALA\*, Arzu YAKUT BÜYÜK\*\*, Sibel SÜDOĞAN\*\*,  
Zafer TÜRKOĞLU\*\*\*, Buket ESKİÇIRAK\*\*\*

\* Doç.Dr., SSK Göztepe Eğitim Hastanesi Dermatoloji Kliniği,

\*\* Uz.Dr., SSK Göztepe Eğitim Hastanesi Dermatoloji Kliniği,

\*\*\* Dr.,SSK Göztepe Eğitim Hastanesi Dermatoloji Kliniği,İSTANBUL

### Summary

**Introduction:** The hyperimmunoglobulin E (HIE) syndrome is a rare genetic disease. The clinical picture is dominated by coarse facies and recurring cutaneous and visceral bacterial infections due to staphylococci and severe generalized eczema, which may be associated with osteoporosis. Biochemistry includes a high level of total and specific IgE and blood eosinophilia. Although the etiology of HIE syndrome is unknown, there is evidence that patients with this syndrome have abnormalities in cellular and humoral immune responses.

**Case Report:** A 14-year-old girl with the clinical features of HIE syndrome and recurrent pyogenic infections since infancy is presented.

**Conclusion:** She had a cellular defect in neutrophil chemotaxis, elevated serum levels of IgE, marked eosinophilia associated with generalized osteoporosis and was successfully treated with antibiotic therapy.

**Key Words:** Hyperimmunoglobulin E syndrome, Job's syndrome, Immunodeficiency, Neutrophil deficiency

T Klin J Dermatol 2003, 13:116-119

### Özet

**Giriş:** Hiperimmunglobulin E (HIE) sendromu nadir görülen genetik bir hastalıktır. Klinik tabloda kaba yüz görünümü, özellikle stafilokoklara bağlı tekrarlayan kutane ve viseral bakteriyel enfeksiyonlar ve şiddetli jeneralize ekzema hakimdir. Bazen osteoporozis ile birlikte görülebilir. Laboratuvar tetkiklerinde total ve spesifik IgE' de yükseklik ve eozinofili görülür. HIE sendromunun etyolojisi tam bilinmemekle birlikte hücrel ve humoral yanıtlarda bozukluk olduğu düşünülmektedir.

**Olgu Sunumu:** Küçüklüğünden beri HIE sendromunun klinik belirtilerini gösteren ve tekrarlayan piyojenik enfeksiyonları olan 14 yaşında bir kız hasta sunulmuştur.

**Sonuç:** Nötrofil kemotaksisinde defekt, serum IgE düzeylerinde yükseklik, belirgin eozinofili ve jeneralize osteoporozisi olan hasta antibiyotikle başarıyla tedavi edildi.

**Anahtar Kelimeler:** Hiperimmunglobulin E sendromu, Job sendromu, İmmun yetmezlik, Nötrofil yetmezliği

T Klin Dermatoloji 2003, 13:116-119

The hyperimmunoglobulin E syndrome (HIE) or Job's syndrome, is a rare, complex disorder characterized by high levels of serum IgE, coarse facies, chronic eczematoid dermatitis with recurrent sinopulmonary and skin infections (1-3). The reason for the patients' susceptibility to certain infections, particularly *Staphylococcus aureus* (*S aureus*) has not been understood (3). Abnormalities in neutrophil chemotaxis have been described in some patients but they are not consistent (1,3). The patients with HIE syndrome are reported to have defective production of interferon gamma (IFN- $\gamma$ ) which could lead to elevated concentrations of IgE (4,5). However, the pathogenesis of HIE syndrome remains unknown (1,3).

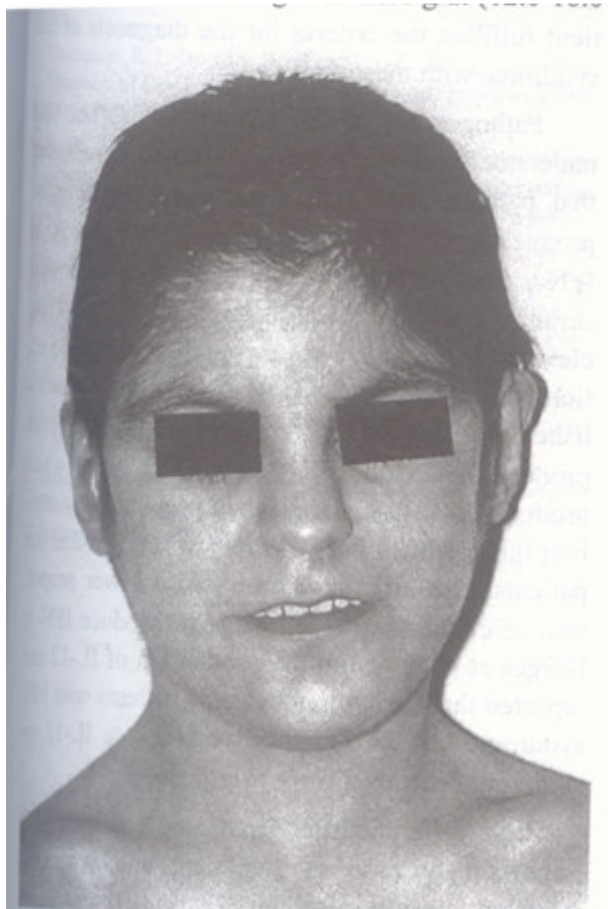Here we report a case of HIE syndrome and emphasize to remind the presence of this syndrome if IgE is found to be elevated in patients with chronic recurrent bacterial infections of the skin of undetermined origin because of treatment and prognosis.

### Case Report

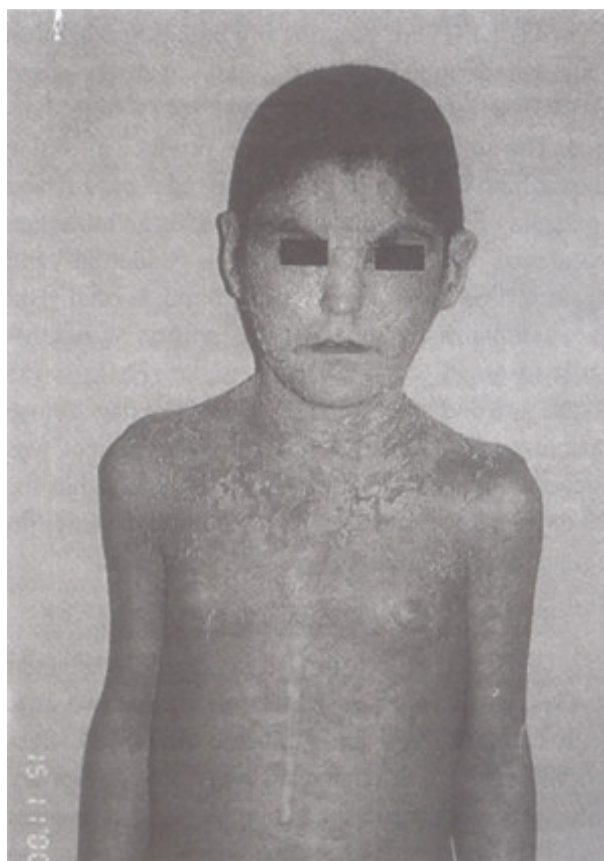
A 14-year-old girl presented with persistent generalized eczematoid dermatitis, conjunctivitis, purulent discharge from her left ear. She had a history of recurrent skin infections, otitis media and pneumonia from her early infancy. She was the first child of her parents who had first degree consanguinity. Her 2 sisters and 1 brother were

normal. She was short for her age and was noted to have a coarse facial appearance with a prominent brow, a broad nasal bridge, deep seated eyes, irregularly proportioned cheeks and jaws and lowered hair line (Figure 1). She had a pruritic eczematoid eruption on her face, scalp and ears, chest and shoulders with some excoriation, scales and weeping. It was initially thought to be seborrhoeic dermatitis because of the greasy yellow thick scales especially localized on the scalp. In addition there was a widespread erythematous rash of macules and papules affecting both upper extremities and anterior surface of the trunk (Figure 2). Her examination revealed chronic otitis media in left ear, squamous blepharitis in both eyes, gingivitis and a palpable tender left supraclavicular lymph node.

Laboratory studies showed an elevated erythrocyte sedimentation rate 95mm/hr (0-10mm/hr), a slightly decreased hemoglobin 10.1 g/dl (12.0-16.0



**Figure 1.** Patient with hyperimmunoglobulin E syndrome showing characteristic appearance with a broad nasal bridge and coarse facies.



**Figure 2.** Persistent pruritic and weeping eczematoid lesions about the ears, face, neck and upper part of the body with scales and widespread erythematous rashes.

g/dl), a normal white blood cell count 5230 cells/mm<sup>3</sup> (4500-13500 cells/mm<sup>3</sup>) with 54% neutrophils (50%-62%), 32% lymphocytes (25%-33%), 1% monocytes (1%-7%) and elevated eosinophils 12% (1%-3%). Serum biochemistry was within normal limits except alkaline phosphatase 590 U/L (20-150 U/L). Serum levels of IgG, IgM, IgA and complement fractions were normal while IgE was highly elevated to 5001 IU/ml (0-200 IU/ml).

*S aureus* was isolated from cultures of scalp and *Pseudomonas aeruginosa* was isolated from discharge of ear. Radiographic examination of bones revealed generalized osteoporosis. Bone age was consistent with 10 years old. Chromosomal analysis revealed 46 XX.

Radioallergosorbent tests (RAST) were positive to house dust mite (*Dermatophagoides pteroi-*

nyssinus 17.50 KU/L; Dermatophagoides farinae 7.26 KU/L). There was not any pathologic band in immunoelectrophoresis. T cell subsets and CD4/CD8 ratio 31%:19% (65%:25%) were normal. The ability of neutrophils to produce nitroblue tetrazolium (NBT), to kill opsonized *S aureus* and to display directed movement towards an attractant substance were studied. NBT reduction and opsonization of *S aureus* was found normal. But flowcytometric analysis of the ability of neutrophils to move towards fmet-leu-phe (FMLP) was found late and slow and the ability to phagocytose opsonized *E coli* was found low. Our patient was successfully treated with cefepime 1 gr i.m bid for 20 days and followed by phenoxymethyl penicillin p.o tid. depending on the results of cultures.

### Discussion

The initial report on HIE syndrome was made in 1966 by Davis et al. (6) who described two girls with fair skin, red hair, chronic dermatitis, dystrophic finger nail changes, severe sinopulmonary infections and recurrent staphylococcal abscesses and they suggested the term Job's Syndrome to describe these patients. In 1972 Buckley et al. (7) reported 2 boys with similiar symptoms and coarse facies who were exactly like the original patients with Job's syndrome, other than being male. These patients were also found to have extremely elevated levels of IgE and immediate skin hypersensitivity reactions to *S aureus* and *Candida albicans* antigens.

Since then similiar cases with hyperimmunoglobulinemia E and recurrent infections have been described. Investigations demonstrated in vitro or in vivo defects in polymorphonuclear leukocyte (PMN) or monocyte chemotaxis, although results diverged between assays or the response varied in the same patients (1,3). Because patients with atopic eczema which may frequently become superinfected with staphylococci and may even have neutrophil chemotactic defects can easily be misdiagnosed as HIE syndrome, a strict definition of this syndrome has been found necessary (1,8,9). In 1983 Donabedian et al. (1) summarized the criteria for diagnosis of HIE syndrome. Constant

features are recurrent bacterial infections of the skin and sinopulmonary track and the presence of serum IgE levels which are at least 10 times normal (>2000 IU/ml). Variable features include the typical coarse facies (10), eczematous rashes, cold cutaneous abscesses, mild eosinophilia, and a defect in neutrophil chemotaxis.

Our patient with typical coarse face of HIE syndrome, had elevated serum levels of IgE (5001 IU/ml), recurrent skin and sinopulmonary infections, chronic eczematous dermatitis, marked eosinophilia (12%) and defects in neutrophil chemotaxis. She did not have dystrophic finger nail changes or candida infections which might be encountered in HIE syndrome (1,2). She had generalized osteoporosis. It is well known that patients with HIE syndrome have had unexplained osteoporosis, predisposing to frequent fractures (10,11). She had also growth failure which might be prominent in some of the affected children (3). Our patient fulfilled the criteria for the diagnosis of HIE syndrome with these findings.

Pathogenesis of this syndrome has not been understood yet (1,3). Recent studies have shown that patients with HIE syndrome have defective production of interferon gamma (IFN- $\gamma$ ) (4,5). As IFN- $\gamma$  is a major activator of PMNs, this could result in defective PMN chemotaxis and markedly elevated IgE levels because of the unopposed action of interleukin-4 (IL-4) (4). It is well established that the balance between Th1 cells, which produce IL-2 and IFN- $\gamma$ , and Th2 cells, which produce IL-4, IL-6, IL-10 is important for controlling IgE productions. Del Prete et al. (5) found that patients with HIE syndrome had a lower proportion of circulating T cells able to produce IFN- $\gamma$ . Borges et al. assessed the production of IL-12 and reported that the lymphocytes of patients with HIE syndrome had an impaired response to IL-12 resulting in decreased IFN- $\gamma$  production.

The differentiation from atopic dermatitis is important because of treatment and prognosis. Affected patients also have a pruritic dermatitis that differs in character and distribution from lesions of atopic dermatitis with lack of other signs

of atopic disease (8).

There have been various approaches to the treatment of this disorder, such as H2 reseptor blockers (1,12), levamisole (1), intravenous immunoglobulin with or without plasmapheresis (13), isotretinoin (14), cyclosporin A (15), disodium cromoglycate (16) but none of them has been consistently successful. Lifelong, continuous antistaphylococcal antibiotic therapy is accepted to be the most successful treatment (8,17). Our patient was treated with antibiotic therapy depending on the results of cultures and her skin lesions improved. We suggested that an accurate diagnosis and treatment of spesific infections in these children is mandatory.

### REFERENCES

1. Donabedian H, Gallin J. The Hyperimmunoglobulin E Recurrent-Infection (Job's) Syndrome. *Medicine* 1983; 62:195-208.
2. Hill HR. The Syndrome of Hyperimmunoglobulinemia E and Recurrent Infections. *Am J Dis Child* 1982;136:767-71.
3. Champion RH, Burton JL, Burns DA, Breathnach SM. *Textbook of Dermatology*, 6th ed. Oxford: Blackwell Science, 1998; 2: 506-8.
4. Borges WG, Augustine NH, Hill HR. Defective interleukin-12/interferon- $\gamma$  pathway in patients with hyperimmunoglobulinemia E syndrome. *J Pediatr* 2000; 136:176-80.
5. Del Prete G, Tiri A, Maggi E, De Carli M, Macchia D, Parronchi P, et al. Defective in vitro production of  $\gamma$ -interferon and tumor necrosis faktor- $\alpha$  by circulating T cells from patients with the hyper-immunoglobulin E syndrome. *J Clin Invest* 1989; 84:1830-5.
6. Davis SD, Schaller J, Wedgwood RJ. Job's syndrome: Recurrent, 'cold', staphylococcal abscesses. *Lancet* 1966; 1:1013-5.
7. Buckley RH, Wray BB, Belmaker EZ. Extreme hyperimmunoglobulinemia E and undue susceptibility to infection. *Pediatrics* 1972; 49:59-70.
8. Hochreutener H, Wuthrich B, Huwyler T, Schopfer K, Seger R, Baerlocher K. Variant of hyper-IgE syndrome: the differentiation from atopic dermatitis is important because of treatment and prognosis. *Dermatologica* 1991; 182(1):7-11.
9. Aydın O, Akay A, Karaman A. Hyperimmunoglobulin E syndrome. *Türkderm* 1999; 33: 258-60.
10. Borges WG, Hensley T, Carey JC, Petrak BA, Hill HR. The face of Job. *J Pediatr* 1998; 133:303-5.
11. Kirchner SG, Sivitt CJ, Wright PF. Hyperimmunoglobulinemia E syndrome: Association with osteoporosis and recurrent fractures. *Radiology* 1985; 156(2):362.
12. Simon GL, Miller HG, Scott SJ. Cimetidine in the Treatment of Hyperimmunoglobulinemia E with Impaired Chemotaxis. *J Infect Dis* 1983; 147(6):1121-2.
13. Wakim M, Alazard M, Yajima A, Speights D, Saxon A, Stiehm ER. High dose intravenous immunoglobulin in atopic dermatitis and hyper-IgE syndrome. *Ann Allergy Asthma Immunol* 1998; 81:153-8.
14. Shuttleworth D, Holt PJA, Mathews N. Hyperimmunoglobulin E syndrome: Treatment with isotretinoin. *Br J Dermatol* 1988; 119:93-9.
15. Etzoni A, Shehadeh N, Brecher A, Yorman S, Pollack S. Cyclosporin A in hyperimmunoglobulin E syndrome. *Ann Allergy Asthma Immunol* 1997; 78(4):413-4.
16. Kojima K, Inoue Y, Katayama Y, Kataoka M, Sunami K, et al. Improvement with disodium cromoglycate of neutrophil phagocytosis and respiratory burst activity in a patient with hyperimmunoglobulin E syndrome. *Allergy* 1998; 53:1101-3.
17. Buckley RH. Disorders of the IgE system. In: Stiehm RE, ed. *Immunologic disorders in infants and children*. 4<sup>th</sup> ed. Philadelphia: WB Saunders, 1996: 409-23.

**Geliş Tarihi:** 11.03.2002

**Yazışma Adresi:** Dr.Mukaddes KAVALA  
SSK Göztepe Eğitim Hastanesi  
Dermatoloji Kliniği, İSTANBUL

*¶Bu olgu 10-14 Ekim 2001 tarihleri arasında Almanya'nın Münih kentinde yapılan X. Avrupa Dermatoloji ve Venereoloji Akademisi Kongresi'nde yazılı bildiri olarak sunulmuştur.*