

# Antenatally Detected Giant Fetal Vein of Galen Aneurysm Complicated with Heart Failure and Hydrocephaly: Case Report

## Antenatal Saptanan Kalp Yetmezliği ve Hidrosefali ile Komplike Olmuş Dev Fetal Galen Ven Anevrizması

Mehmet Serdar KÜTÜK,<sup>a</sup>  
Süreyya Burcu GÖRKEM,<sup>b</sup>  
Osman BAŞTUĞ,<sup>c</sup>  
Mehmet DOLANBAY,<sup>a</sup>  
Annan ÖZTÜRK<sup>c</sup>

Departments of  
<sup>a</sup>Obstetrics and Gynecology,  
<sup>b</sup>Radiology,  
<sup>c</sup>Pediatrics,  
Erciyes University Faculty of Medicine,  
Kayseri

Geliş Tarihi/Received: 11.09.2013  
Kabul Tarihi/Accepted: 25.01.2014

*This study was presented as a poster at the Congress of Maternal Fetal Medicine and Perinatology Association, 8-10 November 2013, Istanbul, Turkey.*

Yazışma Adresi/Correspondence:  
Mehmet DOLANBAY  
Erciyes University Faculty of Medicine,  
Department of Obstetrics and  
Gynecology, Kayseri,  
TÜRKİYE/TURKEY  
mdolanbay@erciyes.edu.tr

**ABSTRACT** Vein of Galen aneurysmal malformation (VGAM) is a rare developmental intracranial arteriovenous shunt. It can be diagnosed antenatally by means of Doppler ultrasonography by showing cystic structure with a marked vascularity and turbulent flow. It may be complicated with heart failure, and hydrocephaly. In this report, we present a case of VGAM complicated with heart failure and hydrocephaly. A 24 year-old, gravid 2, parity 1 woman referred to our unit at 32 weeks gestation with hydrocephaly, and cystic structure of the posterior fossa. Colour Doppler showed turbulent arterial and venous blood flow within the cystic structure. The fetus was delivered at 34 weeks due to worsening heart failure. Despite, intense support, the fetus died at 12 hours after birth due to heart failure. The prenatal diagnosis and postnatal treatment of VGAM is possible with current imaging technologies. However, the prognosis is still poor for fetuses with heart failure.

**Key Words:** Vein of galen aneurysm; heart failure; hydrocephalus; prenatal diagnosis

**ÖZET** Galen ven anevrizma malformasyonu (VGAM) nadir görülen gelişimsel intrakraniyal arteriovenöz şant anomalisidir. Antenatal olarak Doppler ultrasonografi ile kistik yapı içerisinde belirgin damarlanma ve türbülant akımın gösterilmesi ile tanı konulabilir. Bu malformasyonun kalp yetmezliği ve hidrosefali ile komplike olduğu bilinmektedir. Bu yazıda kalp yetmezliği ve hidrosefali ile komplike olmuş bir vaka sunulmaktadır. 24 yaşında Gravida 2 Parite 1 olan hasta 32 haftalık gebelik, hidrosefali ve posterior fossada kistik yapı tanılarıyla ünitemize refere edildi. Renkli Doppler ultrasonografide kistik yapı içerisinde venöz akım ve arteryel türbülant akım izlendi. Fetüs 34. haftada ağırlaşan kalp yetmezliği tanısıyla doğurtuldu. Yoğun desteğe rağmen doğum sonrası 12. saatte yenidoğan kalp yetmezliğine bağlı kaybedildi. Sonuç olarak günümüz görüntüleme teknolojileri ile VGAM'ın prenatal tanısı ve postnatal tedavisi mümkündür. Ancak kalp yetmezliği olan fetüslerde prognoz hala kötü seyretmektedir.

**Anahtar Kelimeler:** Galen veni anevrizması; kalp yetersizliği; hidrosefali; prenatal tanı

**Turkiye Klinikleri J Case Rep 2014;22(4):307-10**

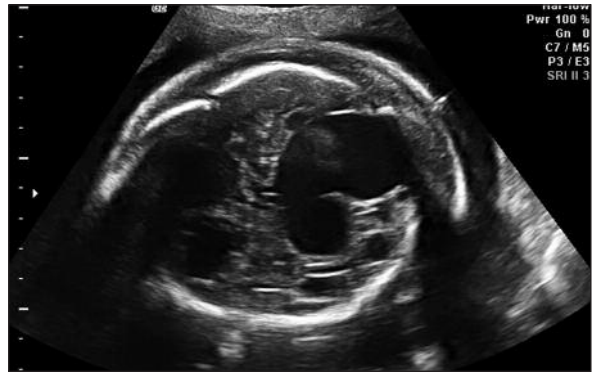
**V**ein of Galen aneurysmal malformation (VGAM) is a rare developmental intracranial arteriovenous shunt that is almost always seen in infants and pediatric population.<sup>1</sup> Although it is thought that VGAM arises from the persistence of median pencephalic vein, the exact pathogenesis is unknown.<sup>2</sup> The antenatal diagnosis of VGAM was first reported by Hirsch et al. (1983), and is becoming more common.<sup>3</sup> With the increasing detection of VGAM antenatally, the prenatal counselling regarding the outcome and the treatment options have come into question. In order to provide realistic antenatal counselling, the ultrasonographic findings that

have prognostic implications should be searched and presented to the families and caring neonatologist/ pediatric neurologist.

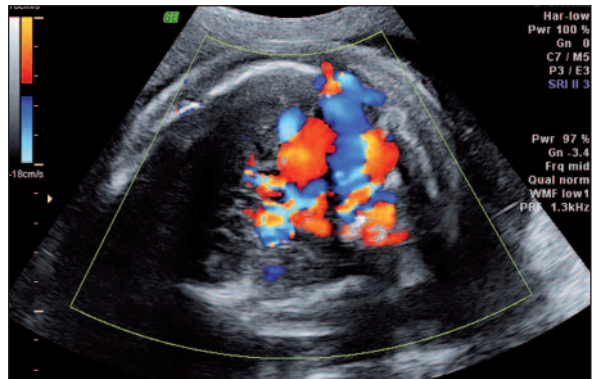
We present here a case of giant VGAM that is complicated with hydrocephaly and heart failure, and a review of the current literature with regard to the relationship between antenatal findings and postnatal outcome.

## CASE REPORT

A 24 year-old, Gravida 2, Parity 1 woman was referred to our unit, at 32 weeks gestation for fetal evaluation because of fetal ventriculomegaly, hydrocephaly and cystic mass of the posterior fossa. The pregnancy was uneventful, and antenatal screening tests were normal. Ultrasonographic (US) examination at referral revealed 32 weeks, singleton fetus at cephalic presentation. The placenta was at the posterior uterine wall, and amniotic volume was elevated (Amniotic Fluid Index: 23). Neurosonogram revealed hydrocephaly with lateral ventricular measurement of 18 mm. Posterior part of the third ventricle was replaced by a supratentorial complex/cystic structure measuring 5.5x 6.2x 7cm, and cerebellum was displaced inferiorly (Figure 1). In the mass, the cystic structures were separated from each other by the solid component. Colour Doppler US confirmed the suspicion of VGAM by demonstrating turbulent arterial and venous blood flow within the cystic structure (Figure 2). Fetal magnetic resonance imaging (MRI) demonstrated cystic structure posterior to the third ventricle as a signal void lobular mass (Figure 3 A,B). The peak systolic blood flow in the cystic lesion was 47 cm/sn. The maximum blood flow velocities in the ascending aorta was 222 cm/sn, and in the pulmonary artery, it was 187 cm/sn, and both were elevated. Cardiac axis was 67°, and elevated. Fetal echocardiography revealed cardiomegaly, ventricular and atrial dilation, and atrio-ventricular valve regurgitation. In addition, the carotid arteries were markedly distended. Digoxin was started to the mother at a dose of 0.25 g, twice daily for fetal inotropic support. At 34<sup>th</sup> gestational weeks, male fetus weighing 2795 g, was delivered with caesarean section, due to the

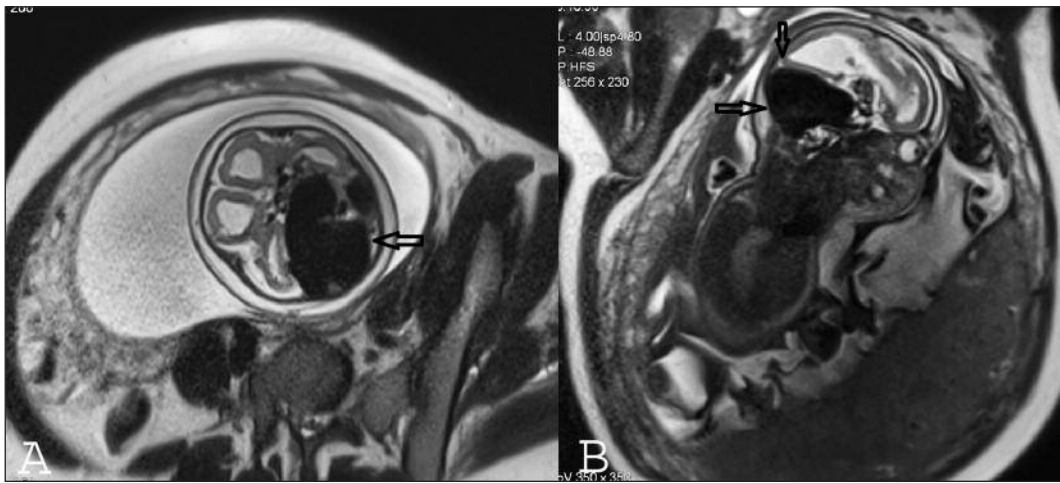


**FIGURE 1:** Ultrasound image of the 32 weeks fetus at axial plane showing the large anechoic structure located posterior to the third ventricle that compressing adjacent structure.



**FIGURE 2:** Color Doppler imaging showing vascular nature of the cystic lesion. Note the mixed arterial and venous flow and the marked turbulence within the lesion.

worsening heart failure, and transverse lying. The APGAR scores were 6 at 1 min, 7 at 10 min. After the delivery, the infant showed no respiratory effort, and intubated. Clinical examination showed signs of heart failure with severely distended neck vessels. Echocardiography revealed a marked cardiomegaly, and pulmonary ground-glass pattern was prominent at chest film. Neonatal US, and cranial computed tomography confirmed the prenatal diagnosis by showing giant cystic vascular structure accompanied by hydrocephaly, and distorted posterior cerebral anatomy. At postoperative 12<sup>th</sup> hours, the infants condition deteriorated, and signs of cardiovascular failure ensued. The infant became unresponsive to positive inotropic drugs (dopamine infusion), and died at postnatal 16<sup>th</sup> hour.



**FIGURE 3:** Fetal MRI: A giant aneurysmatic galen vein malformation was demonstrated as signal void lobular mass with feeding dilated vascular structures on T2 HASTE axial (A) and sagittal (B) images (black arrows).

## DISCUSSION

Prenatal diagnosis of VGAM is usually established at the third trimester of pregnancy. Since VGAM is the only lesion showing turbulent mixed vascular flow within a cystic lesion, Doppler examination enables the differential diagnosis to be made of this malformation from other cystic structures (arachnoid cyst, porencephalic cyst, Dandy-Walker malformation, pineal tumours, haemorrhage, and choroid papilloma). Additionally, pulsed Doppler is essential in evaluating fetal cardiovascular hemodynamic status, which has an important prognostic value. Today, whether MRI is of additional benefit in adjunct to sonography remains to be established. However, it may be important to rule out associated brain malformation, given the fact that VGAM may be associated with porencephaly, and schizencephaly.<sup>4</sup>

The most challenging issue in the antenatal counselling of VGAM is to predict postnatal prognosis. In general, antenatally diagnosed VGAM has a largely poor outcome, with only about 30% of patients are alive without mental impairment.<sup>4</sup> Very recently, Deloison et al. reviewed the diagnostic criteria, and concluded that pre and postnatal prognosis is poor in the presence of intrauterine signs of cardiac decompensation.<sup>4</sup> Yuval et al. suggested that the presence of the signs of heart failure reflects the high flow lesions that may not

respond to therapy.<sup>5</sup> Despite the fact that the evaluation of hemodynamic parameters by Doppler US was suggested to have a predictive value, no criteria were established for these parameters. In the present case, the peak systolic flow velocities for aorta, and pulmonary artery were high in response to the high output heart failure. In our case, all criteria for the poor prognosis of VGAM were present antenatally, that were being heart failure, and hydrocephaly. Moreover, the dimensions of the lesion and its mass effect, which compressed cerebellum and brain stem, and caused abnormal cerebrospinal fluid circulation, might probably contributed to the recalcitrant respiratory failure and poor outcome.

Transarterial embolization has been thought to improve the prognosis of VGAM. However, embolization is difficult and carries a high risk of complications in neonates with severe heart failure. Therefore the hemodynamic stabilization of these neonates is critical. The potential role of antenatal digoxin therapy is unknown, and in our case, it did not provide any benefit. The success rate of postnatal treatment with endovascular techniques varies according to the time of diagnosis, clinical presentation, and patient selection. In their series of 21 cases Deloison et al. reported that only three of 21 cases were alive, and without neurological sequelae.<sup>4</sup> In a study of Rodesch et al., 12 of 18 children with a prenatal diagnosis of isolated VGAM

underwent embolization, and 8 of the 12 had normal neurological outcomes.<sup>6</sup> Heuer et al. reported that three of seven cases presented with heart failure in the early neonatal period were died. In the same series, another two cases had moderate or severe neurological deficits.<sup>1</sup> The common feature of these series and others is that the presence of heart failure in the fetal and early neonatal period is associated with a poor outcome.<sup>1,4,6,7</sup>

Optimal time and mode of delivery of the infants with prenatal diagnosis of VGAM have yet to be determined. Practically, fetuses with VGAM should be followed for heart failure, and hydrops fetalis. The optimal time for delivery is that at which the fetus reaches pulmonary maturity without afflicted by severe heart failure and hydrops fe-

talıs. Unfortunately no US criteria and Doppler value were reported to have a predictive value for hydrops fetalis, and severe heart failure, in these fetuses. Therefore, every decision should be taken by multidisciplinary team, and the technical capabilities of the interventional radiology unite and the neonatal intensive care facilities should be taken into account.

In conclusion, the prenatal diagnosis and postnatal treatment of VGAM is possible with current imaging technologies. However, the prognosis is still poor for fetuses with heart failure. The future research agendas should include fetal interventions that reduce the shunting and, thus the degree of heart failure, bring the affected fetus to condition eligible for postnatal embolization.

## REFERENCES

1. Heuer GG, Gabel B, Beslow LA, Stiefel MF, Schwartz ES, Storm PB, et al. Diagnosis and treatment of vein of Galen aneurysmal malformations. *Childs Nerv Syst* 2010;26(7):879-87.
2. Zerah M, Garcia-Monaco R, Rodesch G, Terbrugge K, Tardieu M, de Victor D, et al. Hydrodynamics in vein of Galen malformations. *Childs Nerv Syst* 1992;8(3):111-7; discussion 117.
3. Hirsch JH, Cyr D, Eberhardt H, Zunkel D. Ultrasonographic diagnosis of an aneurysm of the vein of Galen in utero by duplex scanning. *J Ultrasound Med* 1983;2(5):231-3.
4. Deloison B, Chalouhi GE, Sonigo P, Zerah M, Millischer AE, Dumez Y, et al. Hidden mortality of prenatally diagnosed vein of Galen aneurysmal malformation: retrospective study and review of the literature. *Ultrasound Obstet Gynecol* 2012;40(6):652-8.
5. Yuval Y, Lerner A, Lipitz S, Rotstein Z, Hegesh J, Achiron R. Prenatal diagnosis of vein of Galen aneurysmal malformation: report of two cases with proposal for prognostic indices. *Prenat Diagn* 1997;17(10):972-7.
6. Rodesch G, Hui F, Alvarez H, Tanaka A, Lasjaunias P. Prognosis of antenatally diagnosed vein of Galen aneurysmal malformations. *Childs Nerv Syst* 1994;10(2):79-83.
7. Has R, Günay S, Ibrahimoglu L. Prenatal diagnosis of a vein of Galen aneurysm. *Fetal Diagn Ther* 2003;18(1):36-40.