

# Femoral Artery Pseudoaneurysm Which Caused Skin Necrosis: Case Report

## Cilt Nekrozu Yapmış Femoral Arter Psödoanevrizması

Eyüpserhat ÇALIK,<sup>a</sup>  
Ziya YILDIZ,<sup>a</sup>  
Mehmet TORT,<sup>a</sup>  
Ümit ARSLAN,<sup>a</sup>  
Bilgehan ERKUT<sup>a</sup>

<sup>a</sup>Clinic of Cardiovascular Surgery,  
Erzurum Training and Research Hospital,  
Erzurum

Geliş Tarihi/Received: 10.10.2014  
Kabul Tarihi/Accepted: 07.11.2014

*This case report was presented as a poster at  
13<sup>th</sup> Turkish Cardiovascular Surgery Congress,  
30 October- 02 November 2014, Antalya,  
Turkey.*

Yazışma Adresi/Correspondence:  
Eyüpserhat ÇALIK  
Erzurum Training and Research Hospital,  
Department of Cardiovascular Surgery,  
Erzurum,  
TÜRKİYE/TURKEY  
eyupserhatcalik@hotmail.com

**ABSTRACT** One of the important vascular complications that can occur after cardiac interventions which are being performed an increasing number nowadays is pseudoaneurysm. The treatment of pseudoaneurysms; is to stop the blood flow into the sac by creating thrombosis with methods such as apply direct pressure, micro-coil embolization, thrombin injection or open surgical procedures. In addition, it has been reported that, small pseudoaneurysm could close spontaneously. We aimed to present a case with skin necrosis and opening caused because of femoral pseudoaneurysm occurring after cardiac interventions in a period of two weeks, due to it is a rare complication.

**Key Words:** Angioplasty; complications; aneurysm, false; necrosis

**ÖZET** Günümüzde giderek artan sayıda yapılmakta olan kardiyak girişimler sonrası ortaya çıkabilen önemli vasküler komplikasyonlardan birisi psödoanevrizmalardır. Psödoanevrizmaların tedavisi; direkt bası uygulamak, mikro koil embolizasyon, trombin enjeksiyonu gibi yöntemlerle tromboz oluşturup, kese içine kan akımını durdurarak ya da açık cerrahi yöntemlerle yapılmaktadır. Ayrıca, küçük çaptaki psödoanevrizmaların spontan kapanabildiği bildirilmiştir. Kardiyak girişim sonrası oluşan femoral psödoanevrizma nedeniyle, iki hafta gibi bir sürede, ciltte nekroz ve açılma gelişen bir olguyu, nadir görülen bir komplikasyon olması nedeniyle sunmayı amaçladık.

**Anahtar Kelimeler:** Anjiyoplasti; komplikasyonlar; anevrizma, yalancı; nekroz

**Türkiye Klinikleri J Cardiovasc Sci 2014;26(3):137-40**

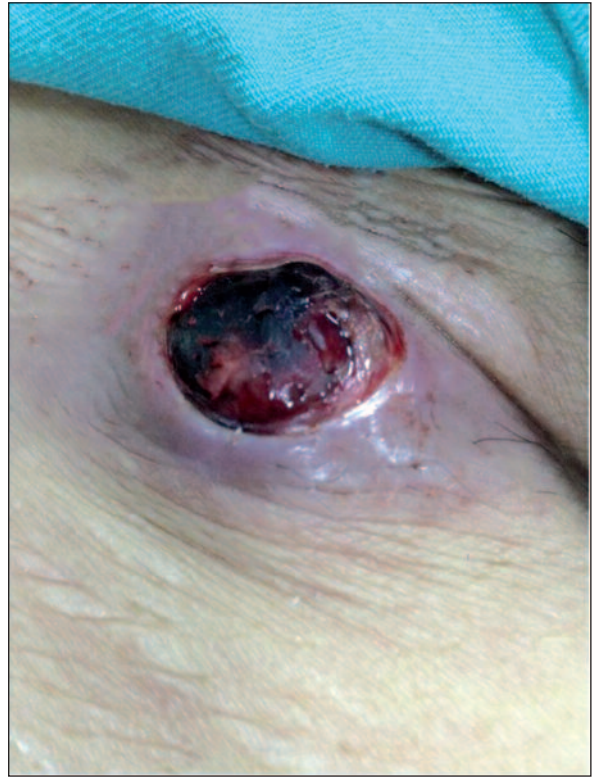Today, cardiac catheterization procedures are being performed an increasing number and centers with diagnostic and therapeutic purposes. Accordingly, risk of developing of vascular complications is increasing. One of the complications, which is most common, is pseudoaneurysm. The main event in the development of pseudoaneurysm is lost in the continuity of arterial wall. During the natural course, pseudoaneurysms can cause complications by causing rupture, infection, distal arterial embolism, compression to adjacent artery, vein, nerve, bone and muscle structures.<sup>1</sup> In this article, a case with right femoral artery pseudoaneurysm caused after coronary angiography and resulting in skin necrosis and opening in a short period such as two weeks has been discussed with the literature.

## CASE REPORT

Seventy-three-year-old female patient was referred to our clinic from the emergency department with complaints of swelling and bleeding in the right femoral region. It has been learned from the patient's history that, she underwent cardiac procedures from the right femoral artery due to acute myocardial infarction two weeks ago, then the swelling occurred in the same area which became bigger and the skin caused bleeding by opening over time. On physical examination, 2x3 cm in size, soft encapsulated pulsatile mass causing necrosis of the skin was present in the right antero-medial femoral region (Figure 1). Systolic-diastolic murmur with auscultation, soft with palpation were detected. Right lower extremity pulses were palpable. On the Doppler ultrasound performed, two hypoechoic heterogeneous lesion areas with 35x17 mm and 18x14 mm size, in conjunction with each other were detected. Lesions were connected with the right femoral artery with 1 cm neck and ying yang flow was present inside. The lesions were consistent with pseudoaneurysm. The patient underwent emergency operation due to pseudoaneurysm caused skin necrosis and bleeding. Under local anesthesia, incision was expanded by debriding the necrotic areas in the skin and femoral artery was explored, the aneurysm sac was removed and femoral artery was repaired with primary suture (Figure 2, 3). Debridement was expanded and subcutaneous necrotic tissues were cleaned. The subcutaneous tissue and skin were closed with primary suturation without requiring the skin flap. In the postoperative period, complications were not observed during follow-up in patient whose distal pulses were palpable, the patient was discharged from hospital on postoperative day 3.

## DISCUSSION

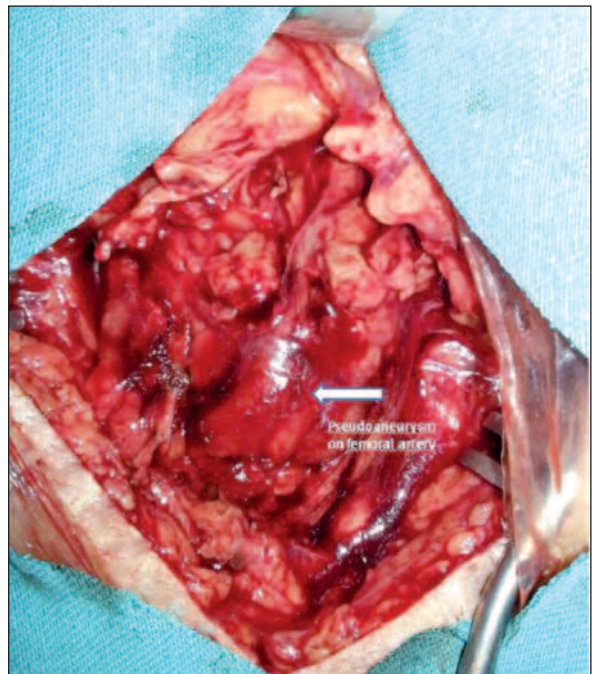
If it is defined, pseudoaneurysm is a limited haematoma occurred around blood vessels due to arterial injury which is formed as a result of an penetrating or non-penetrating trauma or following a vascular surgery initiative.<sup>2</sup> A fibrous capsule which is ever expanding under the influence of ar-



**FIGURE 1:** Pseudoaneurysm with skin necrosis in the right femoral region.

(See color figure at

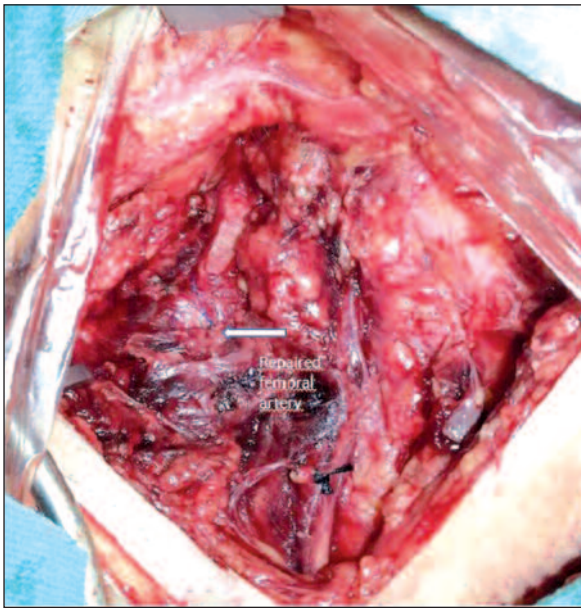
<http://www.turkiyeklinikleri.com/journal/cardiovascular-sciences/1306-7656/>)



**FIGURE 2:** The appearance of pseudoaneurysm in the operation.

(See color figure at

<http://www.turkiyeklinikleri.com/journal/cardiovascular-sciences/1306-7656/>)



**FIGURE 3:** The appearance of repaired femoral artery in the operation.

(See color figure at

<http://www.turkiyeklinikleri.com/journal/cardiovascular-sciences/1306-7656/>)

terial pressure forms the outer wall. Arterial wall trauma, infection, vasculitis, and iatrogenic reasons, which cause disruption of continuity of the arterial walls, may result in pseudoaneurysm. Pseudoaneurysm can occur and grow within hours or days. When the case was viewed from this angle, the interesting part was that, aneurysm sac has grown steadily within two weeks after cardiac catheterization and caused skin necrosis. On physical examination, tenderness, the signs of pressure on venous vessels or arterial occlusion, thrill with palpation, murmur with auscultation can be detected. Pseudoaneurysm should be kept in mind in patient with a pulsatile mass.<sup>3</sup> In our case, skin necrosis was present. In the literature, togetherness of skin necrosis and false aneurysm is extremely rare.<sup>4</sup> While ultrasound imaging is often enough in diagnosis, the examinations such as magnetic resonance imaging, computed tomography, angiography, which demonstrate better vascular bed and surrounding tissue, provide reliable information for the patients undergoing surgery.

Filling of the aneurysm can be prevented by applying direct press on the pseudoaneurysm in the early stages (ultrasound probe by seeing) and thrombosis can be achieved.<sup>5</sup> In appropriate cases, especially in those with iatrogenic reasons, the transition in the vessel wall can be prevented with the micro-coil embolization by entering related artery with catheter or ultrasound-guided thrombin injection into the pseudoaneurysm sac.<sup>5,6</sup> In a prospective study; it has been reported that, 72 of 82 uncomplicated and selected pseudoaneurysms which were smaller than 3 cm in diameter closed spontaneously at an average of 23 days.<sup>7</sup> Emergency surgical approach was chosen in our case due to skin necrosis and hemorrhage.

As in this case, surgery should be considered first for the cases especially that led to skin necrosis and have grown rapidly, it should be considered that the complications that may occur can be serious and surgical treatment should not be delayed. Postoperative period without complications is often the support this approach.<sup>8</sup> The most important considerations in surgical interventions is removal of pseudoaneurysm, repairing the lesion in the artery and reestablishing the blood flow. If resection does not cause more tissue loss and the entry point of pseudoaneurysm is evident, primary repair can be implemented. If end to end anastomosis or primary repair are not possible, autologous or synthetic grafts can be interposed. Autogenous grafts are the first choice by most centers due to they are resistant to infection with long patency rates.<sup>9</sup>

As a result, the patients with pseudoaneurysm are the patient group that early diagnosis and treatment are absolutely necessary when serious complications, which can occur, are considered. However, as presented in our case, we believe that, surgical approach, which will be performed without delay, will give the best results in cases developed rapidly in the early stages with skin necrosis and aneurysm mass.

## REFERENCES

1. Güler A, Şahin MA, Jahollari A, Günay C, Demirkılıç U, Tatar H. [Giant superficial femoral artery aneurysm causing massive muscular necrosis: a case report]. *Gulhane Med J* 2009;51(4):259-61.
2. Clark ET, Gewertz BL. Pseudoaneurysms. In: Rutherford RB, ed. *Vascular Surgery*. 4<sup>th</sup> ed. Philadelphia: WB Saunders Company; 1995. p.1153-61.
3. Mattox KL. Vascular trauma. In: Haimovici H, ed. *Vascular Surgery*. 3<sup>rd</sup> ed. Norwalk/Connecticut: Appleton and Lange; 1989. p.370-85.
4. Canbaz S. [Peripheral arterial aneurysms]. In: Duran E, ed. *Kalp ve Damar Cerrahisi*. 1. Baskı. İstanbul: Çapa Tıp Kitabevi; 2004. p.783-98.
5. Ragg JC, Biamino G. [Post-interventional pseudoaneurysm: technique, status and indications of color Doppler-controlled compression treatment]. *Zentralbl Chir* 1997;122(9):782-90.
6. La Perna L, Olin JW, Goines D, Childs MB, Ouriel K. Ultrasound-guided thrombin injection for the treatment of postcatheterization pseudoaneurysms. *Circulation* 2000;102(19):2391-5.
7. Toursarkissian B, Allen BT, Petrinc D, Thompson RW, Rubin BG, Reilly JM, et al. Spontaneous closure of selected iatrogenic pseudoaneurysms and arteriovenous fistulae. *J Vasc Surg* 1997;25(5):803-8; discussion 808-9.
8. Davidovic L, Lotina S, Vojnovic B, Kostic D, Cinara I, Cvetkovic S, et al. Post-traumatic AV fistulas and pseudoaneurysms. *J Cardiovasc Surg (Torino)* 1997;38(6):645-51.
9. Morrison WG. Pseudoaneurysm and penetrating trauma. *Injury* 1992;23(2):127-8.