

# Evaluation of Radiographic Features of Third Molars with Digital Panoramic Radiographic Images: A Retrospective Cross-Sectional Study

## Üçüncü Büyük Azı Dişlerinin Radyografik Özelliklerinin Dijital Panoramik Radyografik Görüntülerle Değerlendirilmesi: Bir Retrospektif Kesitsel Çalışma

<sup>1</sup>Hümeyra TERCANLI ALKIŞ<sup>a</sup>, <sup>2</sup>Esra YAVUZ<sup>a</sup>, <sup>3</sup>Sevcihan GÜNEN YILMAZ<sup>a</sup>

<sup>a</sup>Department of Oral and Maxillofacial Radiology, Akdeniz University Faculty of Dentistry, Antalya, Türkiye

**ABSTRACT Objective:** This study aims to evaluate the prevalence of impacted 3<sup>rd</sup> molar, angulation status, the level of eruption, relationship with the occlusal plane of the 3<sup>rd</sup> molar teeth, and the rate of pathology in their own and the adjacent tooth of Turkish adult individuals who applied to Akdeniz University Faculty of Dentistry via panoramic radiographic images. **Material and Methods:** 700 patients were examined for this retrospective study. In addition to the localization, eruption, angulation, and occlusal level of the 3<sup>rd</sup> molars, the accompanying pathologies and the pathologies in the adjacent 2<sup>nd</sup> molars were recorded and retromolar spaces were measured. p-value of <0.05 was considered statistically significant. **Results:** The rate of impaction in a total of 2800 3<sup>rd</sup> molars was 29%. Impacted 3<sup>rd</sup> molars were found at a higher rate (54.4%) in the mandible. It was determined that the 3<sup>rd</sup> molar teeth were mostly in the vertical position (77.8%) and 63.1% of them were at level A. 49.9% of mandibular third molar teeth were in class I. **Conclusion:** Impacted 3<sup>rd</sup> molar teeth prevalence was 29%. The most common angulation status was vertical. According to the level of impaction, it was determined that the occlusal planes of the 3<sup>rd</sup> molars and the 2<sup>nd</sup> molars were at the same level most frequently. The location of the 3<sup>rd</sup> molar completely in front of the anterior ramus was the most common position. The most common pathology in the 3<sup>rd</sup> molars was caries, and no pathology was found in the 2<sup>nd</sup> molars except caries.

**ÖZET Amaç:** Bu çalışmada, Akdeniz Üniversitesi Diş Hekimliği Fakültesine başvuran Türk erişkin bireylerin gömülü 3. büyük azı dişlerinin prevalansı, açılanma durumu, sürme düzeyi, 3. büyük azı dişlerinin okluzal düzlemi ile ilişkisi ve kendi ve komşu dişteki patoloji oranlarının panoramik radyografik görüntüler ile değerlendirilmesi amaçlanmıştır. **Gereç ve Yöntemler:** Bu retrospektif çalışma için 700 hasta incelendi. Üçüncü büyük azı dişlerinin lokalizasyonu, sürme durumu, açılanma durumu ve okluzal düzeyine ek olarak eşlik eden patolojiler, komşuluğundaki 2. büyük azı dişlerinde görülen patolojiler kaydedilerek retromolar boşluklar ölçüldü. İstatistiksel anlamlılığın p<0,05 olduğu varsayıldı. **Bulgular:** Toplam 2800 3. molar dişte gömülü olma oranı %29 idi. Gömülü 3. molar dişler mandibulada daha yüksek oranda (%54,4) bulundu. Üçüncü molar dişlerinin en çok dikey pozisyonda olduğu (%77,8) ve %63,1'inin A düzeyinde olduğu tespit edildi. Mandibular 3. molar dişlerin %49,9'u sınıf I'deydi. **Sonuç:** Gömülü 3. molar diş prevalansı %29 idi. Üçüncü molarlarda en yaygın görülen açılanma durumu dikey açılanma idi. İmpaksiyon seviyesine göre en sık 3. molarların ve 2. molarların okluzal düzlemlerinin aynı seviyede olduğu tespit edildi. Mandibular 3. molar dişlerin anterior ramusun tamamen önünde yer alması en sık görülen pozisyondu. Üçüncü molarlarda en sık görülen patoloji çürüktü ve 2. molarlarda çürük dışında patolojiye rastlanılmadı.

**Keywords:** Impacted teeth; panoramic radiography; third molars

**Anahtar Kelimeler:** Gömülü dişler; panoramik radyografi; üçüncü molar dişler

Tooth impaction is an eruption failure that can be pathological and impacted teeth cannot become to their normal functional location.<sup>1</sup> The most frequently impacted teeth are the 3<sup>rd</sup> molar teeth, and this rate

constitutes 98% of all impacted teeth.<sup>2</sup> Because the 3<sup>rd</sup> molars are the last to take their place in the dental arch, they remain impacted for many reasons, such as racial variations, early physical maturation, de-

**Correspondence:** Esra YAVUZ

Department of Oral and Maxillofacial Radiology, Akdeniz University Faculty of Dentistry, Antalya, Türkiye

**E-mail:** esr89@gmail.com



Peer review under responsibility of Türkiye Klinikleri Journal of Dental Sciences.

**Received:** 05 May 2022

**Received in revised form:** 21 Nov 2022

**Accepted:** 13 Dec 2022

**Available online:** 19 Dec 2022

2146-8966 / Copyright © 2023 by Türkiye Klinikleri. This is an open access article under the CC BY-NC-ND license (<http://creativecommons.org/licenses/by-nc-nd/4.0/>).

layed facial growth, insufficient arch size, increased crown size, late mineralization of the 3<sup>rd</sup> molars, absence of the deciduous tooth preceding it and eruption of other teeth in the distal direction.<sup>3-6</sup> A range of between 10.27% and 68.6% prevalence of impacted 3<sup>rd</sup> molar has been reported in the literature.<sup>4,7-10</sup>

While impacted 3<sup>rd</sup> molars may remain asymptomatic, they can cause pericoronitis, cyst, neoplasm, periodontitis, root resorption, pathological changes in the adjacent tooth, orofacial pain, temporomandibular joint disorders.<sup>6,7,11,12</sup> The presence of pathology in the impacted 3<sup>rd</sup> molar is multifactorial and the level of eruption and angulation status affect the development of pathology.<sup>12</sup>

The panoramic radiographic imaging technique is simple and the radiation dose is lower than cone beam computed tomography. With panoramic radiographs, it is possible to evaluate the teeth and surrounding structures in the lower and upper jaws on the same film. Although it has some limitations such as superpositions and lack of cross-sectional information, it is preferred by many researchers in the evaluation of 3<sup>rd</sup> molar teeth.<sup>13,14</sup>

This retrospective study aims to evaluate the prevalence of impacted 3<sup>rd</sup> molar, angulation status, the level of eruption, relationship with the occlusal plane of the 3<sup>rd</sup> molar teeth, and the rate of pathology in their own and the adjacent tooth of Turkish adult individuals who applied to Akdeniz University Faculty of Dentistry via panoramic radiographic images.

## MATERIAL AND METHODS

This study was confirmed by the Akdeniz University Faculty of Medicine Ethics Committee (Ethics approval number: 70904504/223) and was conducted in accordance with the principles of the Declaration of Helsinki.

The records of 3924 patients who presented to the Akdeniz University Faculty of Dentistry, Oral and Maxillofacial Radiology Department, for any reason between August 2018-October 2018 were assessed. The following criteria were used for the study. The inclusion criteria were: (1) age range between 18- 50 years, (2) presence of all third molars, (3) presence

of all 2<sup>nd</sup> molars and first molars, (4) absence of trauma, and (5) systemic diseases affecting the bone structure. Panoramic radiographic images of patients with the craniofacial anomaly, hereditary disease affecting the bone structure, pathology in the den-toalveolar region, and history of any 3<sup>rd</sup> molar tooth extraction were excluded from the study, PRIs with poor image quality and vertical or horizontal distortion were not evaluated. According to these criteria, 700 panoramic radiographic images were included in the study. In addition to demographic data, the localization, eruption status, angulation status, and occlusal level of 3<sup>rd</sup> molar teeth, radiographic pathology of 3<sup>rd</sup> molar teeth, presence of pathological changes seen in the 2<sup>nd</sup> molar due to 3<sup>rd</sup> molars were recorded and retromolar space was measured in maxilla and mandible.

All panoramic radiographic images were obtained using the Planmeca ProMax device (Planmeca Oy, 00880 Helsinki, Finland), following the manufacturer's instructions (66 kVp, 7 mA, and 16 seconds). All panoramic radiographic images were evaluated by the same investigator, who had seven years of experience in dental radiology. Retromolar space measurements were automatically calibrated with the software program (Planmeca Romexis 4.0, Helsinki, Finland).

While eruption status is classified as totally impacted and erupted, the level of the 3<sup>rd</sup> molar about the occlusal plane is classified according to Pell and Gregory (Figure 1a, Figure 1b):<sup>5-7,15</sup>

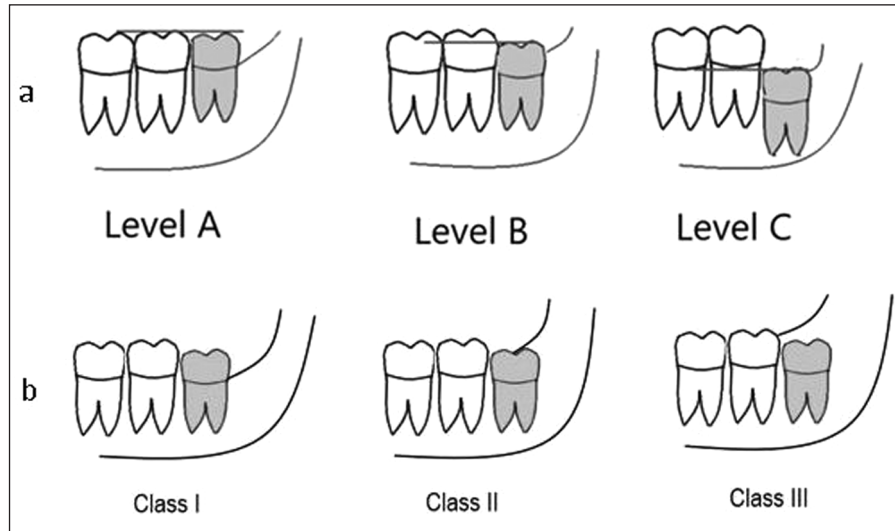
Level A: The occlusal plane of the 3<sup>rd</sup> molar is at the same level as the 2<sup>nd</sup> molar.

Level B: The occlusal plane of the 3<sup>rd</sup> molar is between the occlusal plane and the cervical line of the 2<sup>nd</sup> molar.

Level C: The occlusal plane of the 3<sup>rd</sup> molar is below the cervical line of the 2<sup>nd</sup> molar.

In addition, mandibular 3<sup>rd</sup> molars were classified according to along with the distance between the anterior border of the mandibular ramus and the distal surface of the 2<sup>nd</sup> molar:<sup>16</sup>

Class I: The 3<sup>rd</sup> molar located completely on the anterior border of the ramus.



**FIGURE 1:** Illustrative diagram of Pell and Gregory classifications; **a:** Level of the 3<sup>rd</sup> molar about occlusal plane (level A, level B, level C); **b:** Mandibular 3<sup>rd</sup> molar classification according to along with the distance or width between mandibular ramus and the distal surface of the 2<sup>nd</sup> molar (Class I, Class II, Class III).

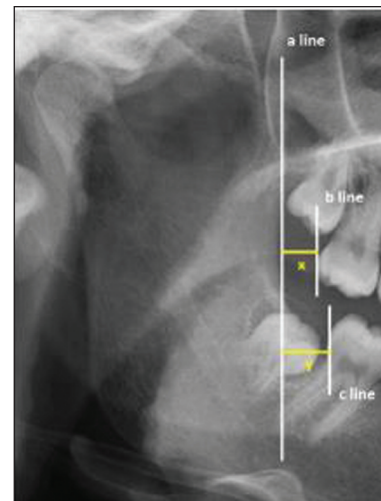
Class II: Part of the 3<sup>rd</sup> molar covered by the anterior border of the ramus.

Class III: The 3<sup>rd</sup> molar is completely in the ramus.

Retromolar space measurements on panoramic radiographic images was shown in Figure 2.<sup>6</sup>

The angulation status of teeth was determined according to Winter classification.<sup>5-7,15</sup> In the Winter classification, the angle between the long axis of the 2<sup>nd</sup> molars and the 3<sup>rd</sup> molars is taken into account; vertical impaction: the angle is between +10 and -10 degrees; mesioangular impaction: the angle is between +11 and -79 degrees; horizontal impaction: the angle is between +80 and +100 degrees; distoangular impaction the angle is between -11 and -79 degrees; others: the angle is between +101 and -80 degrees and buccolingual impaction (Figure 3). The angle between the long axis of the 2<sup>nd</sup> molars and 3<sup>rd</sup> molars was determined with the Planmeca Romexis 4.0 software program, which was developed for the Planmeca ProMax machine (Planmeca Oy, 00880 Helsinki, Finland) automatically.

Radiographic pathologies of the 3<sup>rd</sup> molars were classified as “caries”, “restored”, “radiolucency of the distal aspect of the 3<sup>rd</sup> molar”, “cysts/tumor”, and “others.” When pathologically widened pericoronal



**FIGURE 2:** Retromolar space measurements on the panoramic radiographic image; **a line:** Anterior border of the mandibular ramus; **b line:** Posterior border of maxillary 2<sup>nd</sup> molar; **c line:** Posterior border of mandibular 2<sup>nd</sup> molar; **x:** Retromolar space for maxilla and **y:** Retromolar space for mandibula.

space was 2.5 mm, the 3<sup>rd</sup> molar was accepted as “radiolucency of the distal aspect of the 3<sup>rd</sup> molar.”<sup>17,18</sup>

After 4 weeks, all evaluations of randomly selected 150 patients were repeated and intra-observer variability was evaluated.

#### STATISTICAL ANALYSIS

Datas were statistically analyzed using SPSS (version 23.0, SPSS Chicago, USA). Normality was assessed

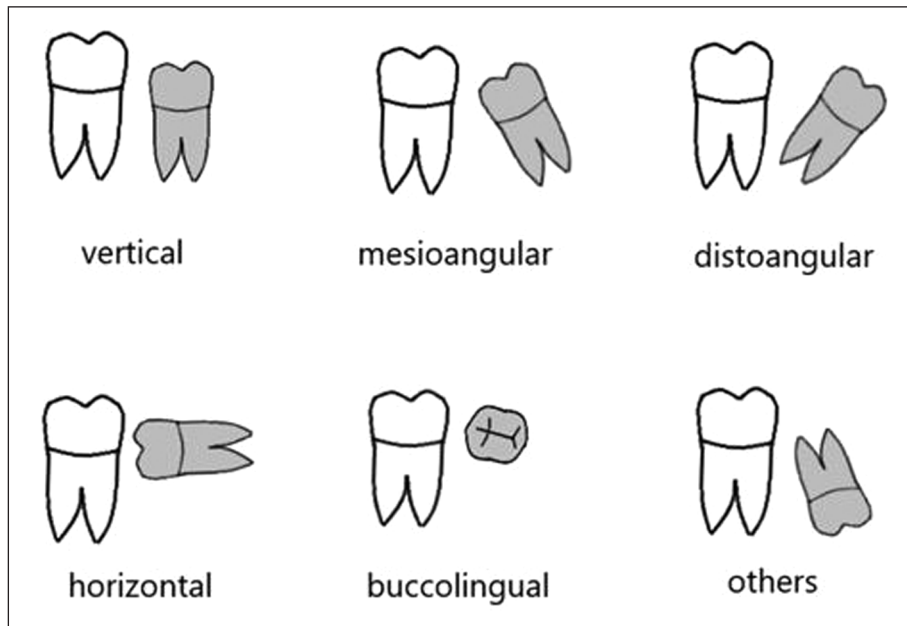


FIGURE 3: Illustrative diagram of Winter classification of third molar angulation status.

using the Shapiro-Wilk test. For analysis of between-group differences, the independent samples t-test was used for normally distributed datas, and the not normally distributed datas were compared with Kruskal-Wallis test. Qualitative variables were compared using the Kruskal-Wallis, exact Fisher, chi-square, and Mann-Whitney U tests. Intra-observer reliability on numerical datas were analyzed using interclass correlation coefficient, and nominal datas were analyzed using kappa coefficients. Statistical significance was assumed  $p < 0.05$ .

## RESULTS

The interclass correlation coefficient calculations for the retromolar space measurement indicated good reliability (interclass correlation coefficient=0.98) and the kappa coefficients were 0.999, 0.984, 0.983, 0.963, and 0.924 for the eruption status, angulation status and occlusal level of the 3<sup>rd</sup> molar, pathologies of the 3<sup>rd</sup> molars, pathological changes in the 2<sup>nd</sup> molars due to the 3<sup>rd</sup> molars, respectively.

Of the 700 panoramic radiographic images were included in the study, 308 (44%) were male and 392 (56%) were female patients. The patients age range was between 18 and 48 years. The mean age was  $25.6 \pm 7.18$ . A total of 2800 3<sup>rd</sup> molars were evaluated

and 813 (29%) 3<sup>rd</sup> molars were found to be impacted. The female/male ratio was 1:0.53 ( $n=531$  and  $n=282$  for females and males, respectively) and the impacted 3<sup>rd</sup> molars were significantly higher in females than males ( $p < 0.001$ ). There was a significant difference between age and eruption status and the impacted 3<sup>rd</sup> molars declined with age ( $p < 0.001$ ).

There were 442 (54.4%) and 371 (45.6%) impacted 3<sup>rd</sup> molars in the mandible and maxilla, respectively. The impacted 3<sup>rd</sup> molars were significantly higher in the mandibula ( $p=0.003$ ).

1767 (63.1%) 3<sup>rd</sup> molars were in level A, 444 (15.9%) 3<sup>rd</sup> molars were in level B, and 589 (21%) 3<sup>rd</sup> molars were in level C. 699 (49.9%) mandibular 3<sup>rd</sup> molars were in Class I, 635 (44.6%) mandibular 3<sup>rd</sup> molars were in Class II, and 76 (5.4%) mandibular 3<sup>rd</sup> molars were in Class III.

2177 (77.8%) 3<sup>rd</sup> molars were in the vertical position, 288 (10.3%) 3<sup>rd</sup> molars were in the mesioangular position, 195 (7%) 3<sup>rd</sup> molars were in the distoangular position, 133 (4.8%) 3<sup>rd</sup> molars were in the horizontal position, 3 (0.1%) 3<sup>rd</sup> molars were in a buccolingual position, and 4 (0.1%) 3<sup>rd</sup> molars were in other positions. For the impacted 3<sup>rd</sup> molars the most common angulation status was vertical in the maxilla (15.4%) and mesioangular in the mandible

**TABLE 1:** The distribution of the 3<sup>rd</sup> molar teeth according to their position and level of impaction.

		Angulation status						p value
		Vertical impaction n/%	Mesioangular impaction n/%	Distoangular impaction n/%	Horizontal impaction n/%	Buccolingual impaction n/%	Others n/%	
Level of impaction	Level A	1686/77.4	24/8.3	57/29.2	0/0	0/0	0/0	<0.001*
	Level B	210/9.6	105/36.5	38/19.5	90/67.7	0/0	1/25	
	Level C	281/12.9	159/55.2	100/51.3	43/32.3	3/100	3/75	
	Total	2177/100	288/100	195/100	133/100	3/100	4/100	

Chi square; level A: The occlusal plane of the 3<sup>rd</sup> molar is at the same level as the 2<sup>nd</sup> molar; level B: The occlusal plane of the 3<sup>rd</sup> molar is between the occlusal plane and the cervical line of the 2<sup>nd</sup> molar; level C: The occlusal plane of the 3<sup>rd</sup> molar is below to the cervical line of the 2<sup>nd</sup> molar; vertical impaction: The angle is between +10 and -10 degrees; mesioangular impaction: the angle is between +11 and -79 degrees; horizontal impaction: the angle is between +80 and +100 degrees; distoangular impaction the angle is between -11 and -79 degrees; others: the angle is between +101 and -80 degrees and buccolingual impaction; n= number of patient; %: percentage; \*p<0.05.

(13.1%). For erupted 3<sup>rd</sup> molars the most angulation status was vertical in both the maxilla and mandible (67.7% and 62.2%, respectively). The distribution of the 3<sup>rd</sup> molars according to their position and level of impaction is shown in Table 1.

The mean retromolar space was smaller in females (12.5±4.77 mm) than males (13.85±5.63 mm) (p<0.001); in the maxilla (12.01±4.85 mm) than the mandibula (14.18±5.34 mm) (p<0.001), and in the impacted 3<sup>rd</sup> molars (10.96±4.53 mm) than the erupted 3<sup>rd</sup> molars (13.97±5.21 mm) (p<0.001). The difference between retromolar space and the impaction level and the angulation status (p<0.001 for both) were statistically significant. Table 2, Table 3 show pairwise comparisons of the impaction level and the angulation status for retromolar space.

While 2565 (91.6%) 3<sup>rd</sup> molars didn't show any pathological changes, caries (n=142, 5.1%) was the most common pathology of the 3<sup>rd</sup> molars and this

**TABLE 2:** Pairwise comparisons of the levels of 3<sup>rd</sup> molar impactions for retromolar space.

Level of impaction	Level A	Level B	Level C
Level A	-	<0.001*	<0.001*
Level B	<0.001*	-	<0.001*
Level C	<0.001*	<0.001*	-

Kruskal Wallis; level A: The occlusal plane of the 3<sup>rd</sup> molar is at the same level as the 2<sup>nd</sup> molar; level B: The occlusal plane of the 3<sup>rd</sup> molar is between the occlusal plane and the cervical line of the 2<sup>nd</sup> molar; level C: The occlusal plane of the 3<sup>rd</sup> molar is below to the cervical line of the 2<sup>nd</sup> molar; \*p<0.05.

was followed by restoration (n=55, 2%), radiolucency of the distal aspect of the 3<sup>rd</sup> molars (n=34, 1.2%) and cyst/tumor (n=4, 5.1%). There was no significant difference in pathological changes of the 3<sup>rd</sup> molars between genders (p=0.173) and areas of the jaw (p=0.066). There was a relationship between pathological changes of the 3<sup>rd</sup> molars and the angulation status and the level of impaction (p<0.001 for both). In addition, there was a significant relationship

**TABLE 3:** Pairwise comparisons of 3<sup>rd</sup> molar angulation status for retromolar space.

Angulation status	Vertical impaction	Mesioangular impaction	Distoangular impaction	Horizontal impaction	Buccolingual impaction	Others
Vertical impaction	-	<0.001*	<0.001*	<0.001*	0.008*	0.09
Mesioangular impaction	<0.001*	-	<0.001*	0.974	0.021*	0.288
Distoangular impaction	<0.001*	<0.001*	-	0.001*	0.12	0.785
Horizontal impaction	<0.001*	0.974	0.001*	-	0.03*	0.318
Buccolingual impaction	0.008*	0.021*	0.12	0.03*	-	0.391
Others	0.09	0.288	0.785	0.318	0.391	-

Kruskal Wallis; vertical impaction: The angle is between +10 and -10 degrees; mesioangular impaction: The angle is between +11 and -79 degrees; horizontal impaction: The angle is between +80 and +100 degrees; distoangular impaction the angle is between -11 and -79 degrees; others: The angle is between +101 and -80 degrees and buccolingual impaction; \*p<0.05.



**TABLE 4:** The distribution of pathological changes of 3<sup>rd</sup> molar visible on radiographs according to level of impaction and angulation status.

	Level of impaction (n/%)				Angulation status (n/%)						p value
	A	B	C	p	V	M	D	H	B	O	
No pathology	1556/55.6	426/15.2	583/20.8		1968/70.3	276/9.9	186/6.6	129/4.6	3/0.1	3/0.1	
Caries	135/4.8	7/0.3	0/0		130/4.6	6/0.2	6/0.2	0/0	0/0	0/0	
Restoration	55/2	0/0	0/0	<0.001*	54/1.9	1/0.1	0/0	0/0	0/0	0/0	<0.001*
Radiolucency of the 3 <sup>rd</sup> molar	21/0.8	9/0.3	4/0.1		25/0.9	4/0.1	2/0.1	3/0.1	0/0	0/0	
Cyst/tumor	0/0	2/0.1	2/0.1		0/0	1/0	1/0	1/0	0/0	1	

Chi square; A: level A "The occlusal plane of the 3<sup>rd</sup> molar is at the same level as the second molar"; B: Level B "The occlusal plane of the 3<sup>rd</sup> molar is between the occlusal plane and the cervical line of the 2<sup>nd</sup> molar"; C: Level C "The occlusal plane of the 3<sup>rd</sup> molar is below to the cervical line of the 2<sup>nd</sup> molar"; V: Vertical impaction "The angle is between +10 and -10 degrees"; M: Mesioangular impaction "The angle is between +11 and -79 degrees"; H: Horizontal impaction "The angle is between +80 and +100 degrees"; D: Distoangular impaction "The angle is between -11 and -79 degrees"; O: Others "The angle is between +101 and -80 degrees and buccolingual impaction"; n: Number of patient; %: percentage; \*p<0.05.

between age and the presence of pathological change ( $p<0.001$ ). (Table 4).

Caries 2.8% ( $n=79$ ) of the 2<sup>nd</sup> molars due to 3<sup>rd</sup> molar was detected and no external root resorption, cyst, or tumor formation in the 2<sup>nd</sup> molar teeth. While 54 of them resulted from the vertical angulation status, 17 of them mesioangular, and 8 of them horizontal angulation. In addition, 55 of them resulted from the level A and this followed by the level B ( $n=23$ ) and the level C ( $n=1$ ). There was a significant relationship between the caries in the 2<sup>nd</sup> molar due to the 3<sup>rd</sup> molars and the angulation status and the level of impaction ( $p<0.001$  for both).

## DISCUSSION

In the current study, the prevalence of the impacted 3<sup>rd</sup> molar was 29%. This result was lower than Sandhu and Kaur, Hashemipour et al., Eliasson et al., Hattab et al., Rajasuo et al., Morris and Jerman and Quek et al. who found this prevalence 34%, 44.3%, 30.3%, 33%, 38%, 65.6%, and 68.6%, respectively.<sup>3,4,7,9,19-21</sup> These incidences of impacted teeth may vary depending on age, gender, genetic factors, race, and geographical differences related to nutrition, and these situations may be the reason for different results in the different studies.<sup>3,6,22</sup> In addition, this variability may be due to different patient inclusion criteria. The current study was conducted on Turkish adult individuals who had all 3<sup>rd</sup> molars, all 2<sup>nd</sup> molars, and all first molars. In the current study, if the 3<sup>rd</sup> molar teeth are fully covered by alveolar

bone they were classified as "impacted teeth", if the alveolar bone was perforated by the 3<sup>rd</sup> molar, they were included in the "erupted" group.

In the current study, the impacted 3<sup>rd</sup> molars were significantly higher in females ( $p<0.001$ ). Some previous studies are compatible with this result.<sup>7,9,11,23</sup> This can be explained by the stoppage of the development of the jaws in females while the 3<sup>rd</sup> molars just erupt, and the continuation of development of the jaws in males.<sup>7</sup> On the other hand, some studies didn't show a sexual predilection for the impacted 3<sup>rd</sup> molars.<sup>4,6,8</sup>

While Yilmaz et al. found no statistically significant difference in the distribution of the impacted 3<sup>rd</sup> molars according to the localization, Sandhu and Kaur, Hattab et al., and Ventä et al. showed a higher frequency of the impacted third molar in the maxilla.<sup>3,4,6,24</sup> In the present study, it was found that the impacted 3<sup>rd</sup> molars were significantly higher in the mandible ( $p=0.003$ ) such as Hashemipour et al.<sup>7</sup> This may be due to the fact that the mandibular bone is more compact than the maxilla, making it more difficult for eruption.

There are several methods for classifying impaction, such as the angulation status of the 3<sup>rd</sup> molars, the level of impaction, and the relation to the anterior border of the mandibular ramus.<sup>12</sup> According to the level of impaction, the current study showed 63.1% A position, 15.9% B position, and 21% C position, regardless of the maxilla or mandible. In the current study, A position is higher

than Hattab et al. (58%), Obiechina et al. (54.55%), Polat et al. (53.2%), Almendros-Marques et al. (44.9%), Monaco et al. (31.5%), Sandhu and Kaur (27%), and Yilmaz et al. (23%) and this result similar with Hashemipour et al. (63.7%).<sup>3,4,6,7,12,15,18,25</sup> Among the previous studies, some studies examined maxillary and mandibular 3<sup>rd</sup> molars, while others examined only mandibular 3<sup>rd</sup> molars.<sup>3,6,7,12,15,18,25</sup> This situation can explain the different results of the previous studies. The 3<sup>rd</sup> molars in both jaws were considered in the present study.

According to Pell and Gregory's classification Class I (49.9%) was the most prevalent type of ramus relationship in the mandibular 3<sup>rd</sup> molars and this was followed by Class II (44.6%) and Class III (5.4%) in the current study. While Almendros-Marques et al., Hashemipour et al., Monaco et al. and Obiechina et al. found the most common type as Class II (87.4%, 63%, 63%, and 60.89%, respectively) in the mandibular 3<sup>rd</sup> molars, the current study showed it was Class I.<sup>7,12,15,25</sup> On the other hand, Class III was the least prevalent type of ramus relationship and this result was similar to mentioned study above.<sup>7,12,15,25</sup> The 3<sup>rd</sup> molar mostly being Level A and Class I in the current study according to Pell and Gregory's classification, suggests that the difficulty degree and complications of a possible surgical procedure to be performed in the population examined may be less.

An important parameter which predicts the eruption of the impacted 3<sup>rd</sup> molars is retromolar space, measured from panoramic radiographic images.<sup>3,26</sup> When the retromolar space is 14.3 mm in males and 13.9 mm in females the possibility of eruption is approximately 70%.<sup>27</sup> The current study showed that this space was 12.5±4.77 mm in females and 13.85±5.63 mm in males and this difference was significant ( $p < 0.001$ ). This situation can be explained why the impacted 3<sup>rd</sup> molar was common in female patients in the current study. On the other hand, even if retromolar space is adequate, the eruption cannot be guaranteed.<sup>28</sup> The possibility of the eruption is 100% when the retromolar space is at least 16.5 mm.<sup>29</sup> In the current study retromolar spaces in the impacted 3<sup>rd</sup> molar and the erupted 3<sup>rd</sup> molar were 10.96±4.53 mm and 13.97±5.21 mm, respectively. When eruption status takes into consideration, the

mean retromolar space was 10.65±4.60 in females and 11.47±4.37 in males in the impacted 3<sup>rd</sup> molar. This result was a little less than Yilmaz et al.'s study (11.9 mm for females, 13.8 mm for males) which is conducted in the same race.<sup>6</sup> While Sandhu and Kaur found the retromolar space 12.86±3.10 mm in the maxilla and 15.34±2.99 mm in the mandible, Yilmaz et al. found this space 11.3 mm in the maxilla and 14.2 mm in the mandible.<sup>3,6</sup> The current study showed that the retromolar space was 12.01±4.85 mm and 14.18±5.34 in the maxilla and the mandible, respectively, and this result is similar to the mentioned studies.<sup>3,6</sup> While the use of panoramic radiographic images for measurements is controversial because of the distortion and magnification inherent to the methodology, measurements can be made more accurately if patient positioning is optimal.<sup>30</sup> All panoramic radiographic images were obtained by the same technician following the manufacturer's instructions. In addition, the mesiodistal widths of the mandibular first molar teeth were evaluated bilaterally for detecting horizontal distortion, and images with greater than a size difference of 1 mm were excluded from the study.<sup>31</sup>

While Kruger et al. found that the most 3<sup>rd</sup> molars were mesioangular in both jaws, according to some studies the most impaction in young adults was vertical angulation status.<sup>19,20,32,33</sup> In the current study the most angulation status was vertical angulation (77.8%). For maxillary 3<sup>rd</sup> molars, while some studies showed that the most angulation status is vertical angulation, Kruger et al. found that mesioangular angulation status was the most frequently observed pattern.<sup>7,9,32</sup> For the mandible 3<sup>rd</sup> molars, while some studies showed that the most angulation status is mesioangular, some studies found that vertical angulation status was the most frequently observed pattern.<sup>3,7,9,12,24,28,32,34</sup> In the current study, the most angulation status was vertical in the maxillary impacted 3<sup>rd</sup> molars (15.4%) and mesioangular in the mandible impacted 3<sup>rd</sup> molars (13.1%). Mesioangular angulation in the mandible may be the result of their late maturation and development, lack of space in the mandible at a later age, and eruption path.<sup>7</sup> For the erupted 3<sup>rd</sup> molars the most angulation status was vertical in both the maxilla and mandible (67.7% and

62.2%, respectively) in the current study. The use of the different methods of classification of angulation status, the level of eruption, the use of the different inclusion criteria, or different races can explain different results of angulation status in similar studies. Additionally, according to Ventä et al. and Richardson to predict the impaction or eruption of the 3<sup>rd</sup> molars before the age of 20 years may be improper due to the continuous positional changes during further development.<sup>28,29</sup>

The impacted 3<sup>rd</sup> molar surgery is regarded as the most common oral surgery.<sup>25</sup> The frequency of postoperative complications increases with age in impacted 3<sup>rd</sup> molars surgery. It is recommended that the surgery should be done as soon as possible, especially before the age of 24 for females.<sup>18</sup> There was a significant difference between age and the presence of pathologies in the current study ( $p < 0.001$ ). Almen-dros Marques et al. didn't find any statistically significant relationship between age and pathological changes such as the appearance of infectious, noninfectious, or neurological complications.<sup>12</sup> While the impacted 3<sup>rd</sup> molars may be asymptomatic indefinitely, they can cause systemic, local, or regional alterations of different severity. The decision of whether asymptomatic impacted 3<sup>rd</sup> molars can be surgically removed or not still causes confusion among dental practitioners. Because the angulation status and the level of eruption can induce the development of pathology, this information can help the dental practitioners when deciding whether to remove the impacted 3<sup>rd</sup> molars or not.<sup>18</sup>

The pathological changes of the 3<sup>rd</sup> molars have been examined in some studies.<sup>5,6,18</sup> While Yilmaz et al. and Akarslan et al. found the most common symptom of 3<sup>rd</sup> molars as pain (39% and 37.05% respectively), Polat et al. found as radiolucency of the distal aspect of the impacted lower 3<sup>rd</sup> molar (9.7%). The most common pathological change of the 3<sup>rd</sup> molar was "caries" in the current study (5.1%) and this result was quite similar to Polat et al.'s (5.3%).<sup>5,6,18</sup>

The pathologically widened pericoronal space cut-off value is 2.5 mm for the panoramic radiographs.<sup>17</sup> The current study showed that the radiolucency of the distal aspect of the 3<sup>rd</sup> molar was quite

smaller (1.2%) than Polat et al. (9.7%).<sup>18</sup> While the current study evaluated the maxillary and the mandibular 3<sup>rd</sup> molars, Polat et al. included only lower impacted 3<sup>rd</sup> molars in their study.<sup>18</sup> This situation can explain the different results between the studies.

The impacted 3<sup>rd</sup> molars can cause caries of the 2<sup>nd</sup> molar, with estimates varying between 1% and 12.6%.<sup>18,35</sup> The current study is compatible with the literature and this frequency was 2.8%. This result of the current study was smaller than Al-Khateeb et al.<sup>35</sup> The current study showed no external root resorption, cyst, or tumor formation in the 2<sup>nd</sup> molar teeth.

## STUDY LIMITATIONS

This study has some limitations. The first is that the study design was a cross-sectional study and the 2<sup>nd</sup> was that it was single-centered. The 3<sup>rd</sup> was that it was based only on radiographic diagnosis and clinical findings could not be examined. This may have led to misinterpretation or misdiagnosed some conditions that cannot be detected radiographically such as enamel caries, and gingival and mucosal lesions.

## CONCLUSION

The impacted 3<sup>rd</sup> molars prevalence was 29%. The impacted 3<sup>rd</sup> molars were significantly higher in females than males and were significantly higher in the mandibula than the maxilla. The most common level of impaction was level A, where the occlusal planes of the 3<sup>rd</sup> molars and the 2<sup>nd</sup> molars were at the same level. The most common angulation status was vertical. Mandibular 3<sup>rd</sup> molars were mostly located anterior to the anterior border of the ramus (Class I). The retromolar space was significantly smaller in females than males; in the maxilla than mandibula and in the impacted 3<sup>rd</sup> molars than the erupted 3<sup>rd</sup> molars. The most common pathological change of the 3<sup>rd</sup> molars was "caries" and there was a relationship between pathological change of the 3<sup>rd</sup> molar and the angulation status and the level of impaction. There were no pathological changes on the 2<sup>nd</sup> molar teeth except for caries and there was a relationship between caries in the 2<sup>nd</sup> molar due to the 3<sup>rd</sup> molars and the angulation status and the level of impaction.



### Source of Finance

During this study, no financial or spiritual support was received neither from any pharmaceutical company that has a direct connection with the research subject, nor from a company that provides or produces medical instruments and materials which may negatively affect the evaluation process of this study.

### Conflict of Interest

No conflicts of interest between the authors and / or family members of the scientific and medical committee members or members of the potential conflicts of interest, counseling, expertise,

working conditions, share holding and similar situations in any firm.

### Authorship Contributions

**Idea/Concept:** Hümeyra Tercanlı Alkış; **Design:** Sevcihan Günen Yılmaz; **Control/Supervision:** Esra Yavuz; **Data Collection and/or Processing:** Esra Yavuz, Sevcihan Günen Yılmaz, Hümeyra Tercanlı Alkış; **Analysis and/or Interpretation:** Hümeyra Tercanlı Alkış; **Literature Review:** Sevcihan Günen Yılmaz; **Writing the Article:** Hümeyra Tercanlı Alkış; **Critical Review:** Esra Yavuz; **References and Fundings:** Esra Yavuz; **Materials:** Sevcihan Günen Yılmaz.

## REFERENCES

- Hassan AH. Pattern of third molar impaction in a Saudi population. *Clin Cosmet Investig Dent*. 2010;2:109-13. [Crossref] [PubMed] [PMC]
- Hattab FN. Positional changes and eruption of impacted mandibular third molars in young adults. A radiographic 4-year follow-up study. *Oral Surg Oral Med Oral Pathol Oral Radiol Endod*. 1997;84(6):604-8. [Crossref] [PubMed]
- Sandhu S, Kaur T. Radiographic evaluation of the status of third molars in the Asian-Indian students. *J Oral Maxillofac Surg*. 2005;63(5):640-5. [Crossref] [PubMed]
- Hattab FN, Rawashdeh MA, Fahmy MS. Impaction status of third molars in Jordanian students. *Oral Surg Oral Med Oral Pathol Oral Radiol Endod*. 1995;79(1):24-9. [Crossref] [PubMed]
- Akarslan ZZ, Kocabay C. Assessment of the associated symptoms, pathologies, positions and angulations of bilateral occurring mandibular third molars: is there any similarity? *Oral Surg Oral Med Oral Pathol Oral Radiol Endod*. 2009;108(3):e26-32. [Crossref] [PubMed]
- Yılmaz S, Adisen MZ, Misirlioglu M, Yorubulut S. Assessment of third molar impaction pattern and associated clinical symptoms in a Central Anatolian Turkish Population. *Med Princ Pract*. 2016;25(2):169-75. [Crossref] [PubMed] [PMC]
- Hashemipour MA, Tahmasbi-Arashlow M, Fahimi-Hanzaei F. Incidence of impacted mandibular and maxillary third molars: a radiographic study in a Southeast Iran population. *Med Oral Patol Oral Cir Bucal*. 2013;18(1):e140-5. [PubMed] [PMC]
- Kaya GS, Aslan M, Omezli MM, Dayı E. Some morphological features related to mandibular third molar impaction. *J Clin Exp Dent*. 2010;2:12-7. [Link]
- Quek SL, Tay CK, Tay KH, Toh SL, Lim KC. Pattern of third molar impaction in a Singapore Chinese population: a retrospective radiographic survey. *Int J Oral Maxillofac Surg*. 2003;32(5):548-52. [Crossref] [PubMed]
- Barakat A, Nofal R. Pattern of impacted third molars and their associated radiographic pathological lesions in Makkah region: a retrospective radiographic survey. *Egyptian Dental Journal*. 2019;65(Issue 1):171-8. [Crossref]
- Ma'aïta J, Alwrikat A. Is the mandibular third molar a risk factor for mandibular angle fracture? *Oral Surg Oral Med Oral Pathol Oral Radiol Endod*. 2000;89(2):143-6. [Crossref] [PubMed]
- Almendros-Marqués N, Alaejos-Algarra E, Quinteros-Borgarello M, Berini-Aytés L, Gay-Escoda C. Factors influencing the prophylactic removal of asymptomatic impacted lower third molars. *Int J Oral Maxillofac Surg*. 2008;37(1):29-35. [Crossref] [PubMed]
- Peker I, Sarikir C, Alkurt MT, Zor ZF. Panoramic radiography and cone-beam computed tomography findings in preoperative examination of impacted mandibular third molars. *BMC Oral Health*. 2014;14:71. [Crossref] [PubMed] [PMC]
- Matzen LH, Wenzel A. Efficacy of CBCT for assessment of impacted mandibular third molars: a review - based on a hierarchical model of evidence. *Dentomaxillofac Radiol*. 2015;44(1):20140189. [Crossref] [PubMed] [PMC]
- Monaco G, Montevicchi M, Bonetti GA, Gatto MR, Checchi L. Reliability of panoramic radiography in evaluating the topographic relationship between the mandibular canal and impacted third molars. *J Am Dent Assoc*. 2004;135(3):312-8. [Crossref] [PubMed]
- Jaroń A, Trybek G. The pattern of mandibular third molar impaction and assessment of surgery difficulty: a retrospective study of radiographs in East Baltic population. *Int J Environ Res Public Health*. 2021;18(11):6016. [Crossref] [PubMed] [PMC]
- Ventä I. Predictive model for impaction of lower third molars. *Oral Surg Oral Med Oral Pathol*. 1993;76(6):699-703. [Crossref] [PubMed]
- Polat HB, Ozan F, Kara I, Ozdemir H, Ay S. Prevalence of commonly found pathoses associated with mandibular impacted third molars based on panoramic radiographs in Turkish population. *Oral Surg Oral Med Oral Pathol Oral Radiol Endod*. 2008;105(6):e41-7. [Crossref] [PubMed]
- Eliasson S, Heimdahl A, Nordenram A. Pathological changes related to long-term impaction of third molars. A radiographic study. *Int J Oral Maxillofac Surg*. 1989;18(4):210-2. [Crossref] [PubMed]
- Rajasuo A, Murtomaa H, Meurman JH. Comparison of the clinical status of third molars in young men in 1949 and in 1990. *Oral Surg Oral Med Oral Pathol*. 1993;76(6):694-8. [Crossref] [PubMed]
- Morris CR, Jerman AC. Panoramic radiographic survey: a study of embedded third molars. *J Oral Surg*. 1971;29(2):122-5. [PubMed]
- Jasim HH. The incidence of impacted permanent teeth: a review article. *Oral Health Dental Sci*. 2022;6(1):1-5. [Link]
- Kim JC, Choi SS, Wang SJ, Kim SG. Minor complications after mandibular third molar surgery: type, incidence, and possible prevention. *Oral Surg Oral Med Oral Pathol Oral Radiol Endod*. 2006;102(2):e4-11. [Crossref] [PubMed]

24. Ventä I, Turtola L, Ylipaavalniemi P. Radiographic follow-up of impacted third molars from age 20 to 32 years. *Int J Oral Maxillofac Surg.* 2001;30(1):54-7. [[Crossref](#)] [[PubMed](#)]
25. Obiechina AE, Arotiba JT, Fasola AO. Third molar impaction: evaluation of the symptoms and pattern of impaction of mandibular third molar teeth in Nigerians. *Odontostomatol Trop.* 2001;24(93):22-5. [[PubMed](#)]
26. Hattab FN, Alhaija ES. Radiographic evaluation of mandibular third molar eruption space. *Oral Surg Oral Med Oral Pathol Oral Radiol Endod.* 1999;88(3):285-91. [[Crossref](#)] [[PubMed](#)]
27. Ganss C, Hochban W, Kielbassa AM, Umstadt HE. Prognosis of third molar eruption. *Oral Surg Oral Med Oral Pathol.* 1993;76(6):688-93. [[Crossref](#)] [[PubMed](#)]
28. Richardson ME. The etiology and prediction of mandibular third molar impaction. *Angle Orthod.* 1977;47(3):165-72. [[PubMed](#)]
29. Ventä I, Murtomaa H, Ylipaavalniemi P. A device to predict lower third molar eruption. *Oral Surg Oral Med Oral Pathol Oral Radiol Endod.* 1997;84(6):598-603. [[Crossref](#)] [[PubMed](#)]
30. Kasimoglu Y, Tuna EB, Rahimi B, Marsan G, Gencay K. Condylar asymmetry in different occlusion types. *Cranio.* 2015;33(1):10-4. [[Crossref](#)] [[PubMed](#)]
31. Silvestrini-Biavati F, Ugolini A, Laffi N, Canevello C, Silvestrini-Biavati A. Early diagnostic evaluation of mandibular symmetry using orthopantomogram. *Indian J Dent Res.* 2014;25(2):154-9. [[Crossref](#)] [[PubMed](#)]
32. Kruger E, Thomson WM, Konthasinghe P. Third molar outcomes from age 18 to 26: findings from a population-based New Zealand longitudinal study. *Oral Surg Oral Med Oral Pathol Oral Radiol Endod.* 2001;92(2):150-5. [[Crossref](#)] [[PubMed](#)]
33. Haidar Z, Shalhoub SY. The incidence of impacted wisdom teeth in a Saudi community. *Int J Oral Maxillofac Surg.* 1986;15(5):569-71. [[Crossref](#)] [[PubMed](#)]
34. Bataineh AB, Albashaireh ZS, Hazza'a AM. The surgical removal of mandibular third molars: a study in decision making. *Quintessence Int.* 2002;33(8):613-7. [[PubMed](#)]
35. Al-Khateeb TH, Bataineh AB. Pathology associated with impacted mandibular third molars in a group of Jordanians. *J Oral Maxillofac Surg.* 2006;64(11):1598-602. [[Crossref](#)] [[PubMed](#)]